A TEXT-BOOK

of

ANATOMY and PHYSIOLOGY

By

JESSE FEIRING WILLIAMS, M. D.

Professor of Physical Education, Teachers College, Columbia University, New York City

THIRD EDITION, REVISED. WITH 405 ILLUSTRATIONS, 29 OF THEM IN COLORS

QM
23
W5
1929

39368

PHILADELPHIA AND LONDON

W. B. SAUNDERS COMPANY

1929

Copyright, 1923, by W. B. Saunders Company. Reprinted October, 1923, and May, 1925
Revised, reprinted, and recopyrighted September, 1926. Reprinted July,
1927 and August, 1928. Revised, entirely reset, reprinted,
and recopyrighted July, 1929

Copyright, 1929, by W. B. Saunders Company

Reprinted November, 1929

MADE IN U. S. A.

PRESS OF
W. B. SAUNDERS COMPANY
PHILADELPHIA

To Workers
In the Field of the Practical Arts

Household Arts
Nursing
Occupational Therapy
Physical Education
Physiotherapy

PREFACE TO THIRD EDITION

This revision for the third edition has been extensive in certain respects. Sections dealing with development have been elaborated both in text and in illustration. This will serve to make these portions easier to understand. These additions have necessitated a larger book but more extension rather than less is needed if clearness and comprehension are to be facilitated. The general plan and purpose of the book, however, remain unchanged.

The study of anatomy and physiology may reveal a remarkable example of the difference between the academic and the professional. This text is written to serve professional students in the field of the practical arts. It would seem to be apparent that professional students either for their own technical work or for teaching the subject should have an understanding of the basic facts. Mere descriptive anatomy or physiology will not suffice.

Nor can the scope of the study be marked out by such words as *simple* or *complex*, *easy* or *difficult*. The study may be classed easy and yet remain throughout clearly academic in character. It becomes professional when it gives to the student a grasp of the problem in human structure and function.

The vocabulary in these sciences presents real difficulties for the student. For this reason alone it is vital to avoid a mere listing of structures which require a rote memorization. There should be then an adequate content that will enable the student to understand and comprehend the principles underlying the terms employed. To aid the student in this study, a rather complete glossary has been added.

Experience of seventeen years in teaching this subject to students strengthens the judgment of the author that anatomy and physiology are basic sciences in all the practical arts. Students who can gain a mastery of the essentials will find all the applied fields not only more interesting and full of meaning, but also of greater practical value.

Jesse Feiring Williams.

Teachers College,
Columbia University.

PREFACE

This book presents the essentials of anatomy and physiology for students of the practical arts—nursing, physical education, physiotherapy, occupational therapy, and household arts. Since the subject matter of these sciences is well developed and generally available, the merit of a book of this kind must reside in the arrangement effected, the teaching helps used, the emphasis given, and the number and quality of illustrations selected.

Arrangement.— The subjects of anatomy and physiology when presented in abbreviated form frequently lack unity and logical sequence because of the selection of isolated facts. Consequently, it often happens that important points and fundamental concepts are omitted. In the writing of this book an effort has been made to present the basic and essential data concerning the structure and function of the human body in an orderly and logical sequence.

Moreover, the book seeks to awaken in the student an interest in the study that shall be more compelling than that of a required course. Such an aim is in harmony with the purposes of all real teachers. To this end, as well as for other practical reasons, embryology is given a distinct place in the text. Bones, muscles, nervous system, and viscera have meaning when introduced in the light of their origin and development.

The approach is the biologic one. The cell, its structure, and functions is the beginning of the study. Then follow the different systems of the body. The nervous system is considered after the muscular system and before the visceral systems because its structure and function are so fundamentally related to understanding of the viscera. It is the most difficult for students, and instructors may leave it for the latter part of the course, if they will early establish certain fundamental ideas concerning structure and function of neurons, centers, and brain areas.

Teaching Helps.—There would be little excuse for another text-book on anatomy and physiology if something worth while could not be added to make the teaching of these subjects more effective. The arrangement is important always, but the practical helps that can be given student and instructor are even more essential.

Teaching difficulties are lightened by suggestions for practical application of the theory. The sciences of anatomy and

physiology present serious difficulties because of the new vocabulary to be mastered and the great mass of new facts to be learned. The problem for the teacher of these sciences outside the medical school is primarily one of developing a field where the new words and new facts may be used, for they are worthless unless interpreted in the light of use and of meaning. Therefore at the end of each section are placed a series of practical exercises, a group of spirited questions, and a list of selected references. The references may or may not be required by the instructor, but for those students who are interested and who wish to look further into the subject a teaching help is offered. Moreover, reference is made to supply houses where slides, biologic material, charts, models, and other desirable supplies may be purchased. To help the teacher has been a constant motive in the mind of the author.

Emphasis.—The book is arranged to serve the needs of the student of anatomy and physiology outside the medical school. Whether a student of nursing, of physical education, or of one of the allied fields, their problems are fundamentally alike. For all, normal structure and function have significance in the light of the deviations from normality. The nurse and physiotherapist need this information for their hospital work; the teacher of physical education for the instruction in hygiene as well as the work in normal diagnosis.

The book covers the essentials of anatomy and physiology. There may well be disagreement with what has been included and what omitted. The author is well aware of the factor of personal equation that determines "essentials." And yet on the basis of a number of years' experience in teaching these subjects, there comes a certain justification. Moreover, the recommendations of the "Standard Curriculum for Schools of Nursing" have been followed, the needs of physiotherapy and occupational therapy aides as shown in our army hospitals have been experienced, and the problems of teachers and physical educators have been kept in mind.

The emphasis given in different chapters is based upon the effort to present the essentials of this study. The time given by the instructor to different portions of the text will vary with the teaching facilities available, other courses offered in the institution, as well as with special needs that may be felt. Thus, instructors of students of physical education may wish to give

relatively a large amount of time to the muscular system, instructors of nurses may wish to emphasize more the circulatory system, but no narrow point of view should be taken if adequate understanding of body structure and function is to be developed.

Whatever the opinion may be about the selection made of the general material, there doubtless will be instant approval of the emphasis given to the anatomy and physiology of the child. The usual texts so often treat the structure and function of the human body as if it were an automobile engine, of fixed and unvarying parts, of constant and uniform action. This is a great mistake, especially for the students of nursing and of physical education. For them, more than for any other workers in the field of the practical arts, the anatomy and physiology of the child are very important. It is greatly to be regretted that we do not have more detailed knowledge of old age.

Illustrations.—Four hundred and five illustrations are used to make clear the text. Twenty-nine of them are in color. The importance of illustrations hardly needs mention. It is sufficient to note that without adequate opportunity for dissection of the human cadaver the student is dependent very largely on illustrations for comprehension of the text.

Arrangement, teaching helps, emphasis, and illustrations—these four factors should render a distinct service. They are the source of the aim that seeks to make this book the most helpful one of its kind to students of the practical arts.

I wish to acknowledge the assistance of many friends and teachers with whom the teaching problems of anatomy and physiology have been discussed. In particular, I wish to express here my appreciation to Miss Katharine Ink, Visiting Instructor of Nurses, Presbyterian, French, and Fifth Avenue Hospitals; to Professor Isabel M. Stewart of the Department of Nursing, Teachers College; to Professor A. Elwyn of the Department of Anatomy, and to Professor R. Burton-Opitz, of the Department of Physiology of this University, for their expert help and criticism in preparation of the manuscript.

It is perhaps needless to say that this acknowledgment is in no sense a shifting of responsibility; errors where they occur are mine.

Jesse Feiring Williams.

Teachers College,
Columbia University.

CONTENTS

CHAPTER I

PAGE

INTRODUCTION 17

The Study of the Human Body, 17—Terminology, 18—The Cell, 20—Functions of Living Cells, 22—Segmentation, Differentiation, and Specialization, 24—Organization of the Body, 26—General Plan of the Human Body, 31—Practical Exercises, 33—Questions, 33—References for Further Study, 34.

CHAPTER II

FORMATION OF THE EMBRYO 35

Development of the Human Body, 35—Derivatives of the Three Embryonic Layers, 45—External Appearance of the Fetus, 46—Nourishment of the Fetus, 47—Composition of the Body, 50—Cells and Heredity, 51—Practical Exercises, 54—Questions, 55—References for Further Study, 55.

CHAPTER III

TISSUES 56

The Five Classes of Tissues, 56—Epithelial Tissues, 56—Function of Epithelium, 64—Connective Tissue, 66—The Function of the Connective Tissue, 73—Muscular Tissue, 75—Function of Muscular Tissue, 76—Vascular Tissue, 77—Function of the Blood, 80—Nervous Tissue, 84—Function of Nervous Tissue, 87—Practical Exercises, 87—Questions, 89—References for Further Study, 89.

CHAPTER IV

THE SKELETON 90

The Nature of the Human Skeleton, 90—Origin of the Skeleton, 91—Formation of Bone, 94—Growth of Bone, 99—General Characteristics of Bone, 100—Plan of the Skeleton, 104—Articulations, 106—Bursæ, 107—Movement in Articulations, 108—Practical Exercises, 110—Questions, 111—References for Further Study, 111.

CHAPTER V

THE SKELETON—SPINE AND SKULL 112

The Spine, 112—Curves of the Spine, 113—Differences in the Spine of Child and Adult, 115—A Typical Vertebra, 115—Characteristics in Different Regions, 117—The Intervertebral Disks, 118—The Ligaments of the Spine, 118—Movements of the Spine, 121—Injuries of the Spine, 124—Skull, 125—The Skull as a Whole, 133—Hyoid Bone, 138—Practical Exercises, 139—Questions, 139—References for Further Study, 139.

CHAPTER VI

PAGE

THE SKELETON—THORAX, PELVIS, AND EXTREMITIES 140

The Thorax, 140—The Shoulder-girdle, 143—The Pelvic Girdle, 143—The Upper Extremity, 150—The Lower Extremity, 155—Arches of the Foot, 165—Practical Exercises, 166—Questions, 167—References for Further Study, 167.

CHAPTER VII

THE SKELETAL MUSCLES 168

Development of the Muscular System, 168—The Attachment of the Muscles, 171—Blood-vessels and Lymphatics, 173—Contraction of Muscle, 173—Chemistry of Muscle, 174—Fatigue of Muscle, 174—Nerves to the Muscles, 176—The Action of Muscles, 176—The Names of Muscles, 178—Muscles of the Abdominal Wall, 179—Muscles of the Back, 184—Muscles of the Thorax, 186—Muscles of the Chest, 189—Muscles of the Neck, 189—Muscles of the Head and Face, 190—Muscles of the Scapula, 192—Muscles of the Arm, 195—Muscles of the Forearm and Hand, 195—Classification of the Muscles of the Trunk and Upper Extremity, 199—Muscles of the Pelvis, 200—Muscles of the Thigh, 204—Muscles of the Leg, 207—Muscles of the Foot, 211—Classification of the Muscles of the Hip and Lower Extremities, 211—Measurement of Muscular Strength, 212—Norms for Amplitude of Voluntary Movement, 213—Motor Points and Reaction of Degeneration, 214—Practical Exercises, 216—Questions, 218—References for Further Study, 218.

CHAPTER VIII

THE NERVOUS SYSTEM—THE CORD 219

The Evolution of the Nervous System, 219—Development of the Nervous System, 220—The Arrangement of the Neurons in the Nervous System, 223—The Divisions of the Nervous System, 225—The Function of the Nervous System, 226—The Spinal Cord, 226—The Spinal Nerves, 229—Structure of the Cord, 234—The Nerve Impulse, 243—Type Reactions in the Nervous System, 244—Education of the Reflexes, 246—Reflexes of the Cord, 247—Practical Exercises, 248—Questions, 249—References for Further Study, 250.

CHAPTER IX

THE NERVOUS SYSTEM—THE BRAIN 251

A Compound Type of Nerve Action, 251—The Brain, 252—General Characteristics, 255—Divisions of the Brain, 257—Tracts of the Brain, 264—The Brain Areas, 266—The Motor Area, 268—Brain Activity in Children, 271—The Cranial Nerves, 271—Nerve-centers, 272—Practical Exercises, 274—Questions, 274—References for Further Study, 275.

CHAPTER X

THE NERVOUS SYSTEM—THE AUTONOMIC 276

The Nature of the Autonomic Nervous System, 276—General Plan, 276—Functions of the Autonomic System, 279—Plexuses and Outlying Ganglia, 282—Summary, 282—Practical Exercises, 282—Questions, 283—References for Further Study, 283.

CHAPTER XI

PAGE

THE CIRCULATORY SYSTEM 284

Development of the Circulatory System, 284—General Arrangement of Circulatory System, 288—The Blood and Lymph, 289—The Lymphatic System, 290—Composition of the Blood, 299—Characteristics of Child's Blood, 306—The Heart, 307—How the Heart Works, 317—Sounds of the Heart, 319—Valvular Lesions of the Heart, 320—Electrocardiography, 321—Practical Exercises, 322—Questions, 323—References for Further Study, 323.

CHAPTER XII

THE VESSELS AND THEIR FUNCTIONS 324

Structure of Arteries and Veins, 325—Blood-supply of Arteries and Veins, 326—Nerve Supply of Arteries, 327—Valves of the Veins, 327—Arrangement of the Vessels, 327—The Pulmonary Circulation, 328—The Systemic Arteries, 328—The Systemic Capillaries, 342—The Systemic Veins, 342—Vasomotor Phenomena, 349—Blood-pressure, 350—How Blood-pressure is Determined, 351—Variations in Blood-pressure, 352—The Arterial Pulse, 353—Measures to Increase Blood Volume, 354—The Fetal Circulation, 355—Practical Exercises, 360—Questions, 362—References for Further Study, 362.

CHAPTER XIII

THE RESPIRATORY SYSTEM 363

Development of the Respiratory System, 363—The Structure of the Nasal Passages, 365—The Nasopharynx, 368—The Pharynx, 368—The Larynx, 368—The Trachea, 370—The Bronchi, 371—The Lungs, 372—The Mediastinum, 375—The Mechanism of the Thorax, 375—How the Lungs Expand, 377—Different Types of Breathing, 377—How the Gases of the Air Enter the Blood, 380—How the Gases of the Blood Enter the Tissues, 380—Nerve Supply to the Lungs and Muscles of Respiration, 381—Practical Exercises, 382—Questions, 384—References for Further Study, 385.

CHAPTER XIV

THE DIGESTIVE SYSTEM 386

Development of the Digestive Tract, 387—The Abdomen, 392—General Characteristics of the Digestive System, 394—The Mouth, 396—The Pharynx, 407—Esophagus, 410—Stomach, 410—Small Intestine, 415—Large Intestine, 420—Practical Exercises, 424—Questions, 424—References for Further Study, 425.

CHAPTER XV

THE DIGESTIVE SYSTEM—LIVER, PANCREAS, AND SPLEEN—INTESTINAL DIGESTION—ABSORPTION—METABOLISM 426

The Liver, 426—The Pancreas, 429—The Spleen, 431—Intestinal Digestion, 432—The Flow of Intestinal, Pancreatic, and Biliary Juices, 434—Movement of the Intestinal Contents, 434—Absorption Phenomena, 434—Absorption and Metabolism of Fats, 436—Absorption and Metabolism of Carbohydrates, 437—Absorption and Metabolism of Proteins, 438—Factors Influencing Metabolism, 439—Basal Metabolism, 440—Heat, Its Production, Dissipation, and Regulation, 440—Practical Exercises, 442—Questions, 442—References for Further Study, 443.

CHAPTER XVI

PAGE

THE EXCRETORY SYSTEM 44

Development of the Excretory System, 444—The Kidneys, 447—The Ureters, 451—The Bladder, 452—The Urethra, 454—How the Kidneys Secrete Urine, 454—The Composition of the Urine, 454—Micturition, 456—Quantity of Urine, 457—Modifying Kidney Action, 457—Practical Exercises, 458—Questions, 458—References for Further Study, 459.

CHAPTER XVII

THE REPRODUCTIVE SYSTEM 46

Development of the Reproductive System, 460—The Female Generative Organs, 461—Menstruation, 469—Menopause, 470—The Mammary Glands, 470—The Male Generative Organs, 471—Practical Exercises, 474—Questions, 474—References for Further Study, 474.

CHAPTER XVIII

THE ENDOCRINE SYSTEM 47

The Nature of Internal Secretions, 475—The Organs of the Endocrine System, 476—The Thyroid Gland, 476—Function of the Thyroid, 477—The Parathyroids, 478—Function of the Parathyroids, 480—The Thymus, 480—Function of the Thymus, 481—The Adrenals or Suprarenal Capsules, 481—Function of the Adrenals, 482—The Pituitary Gland or Hypophysis, 483—Function of the Pituitary, 483—The Germ Glands, 484—Function of the Germ Glands as Internal Secretory Organs, 484—Other Organs, 485—The Pineal Gland, 485—The Carotid Body, 485—The Coccygeal Body, 485—Practical Exercises, 486—Questions, 486—References for Further Study, 486.

CHAPTER XIX

ORGANS OF GENERAL AND SPECIAL SENSE 48

Classification of the General and Special Senses, 487—The General Senses, 488—The Skin and its Appendages, 490—The Sense of Smell, 496—The Sense of Taste, 496—The Sense of Sight, 496—The Eye, 498—The Senses of Hearing and Equilibrium, 507—The External Ear, 507—The Middle Ear, 509—The Internal Ear, 509—Practical Exercises, 516—Questions, 516—References for Further Study, 516.

GLOSSARY 51

INDEX 54

A TEXT-BOOK

OF

ANATOMY AND PHYSIOLOGY

CHAPTER I

INTRODUCTION

I. The Study of the Human Body.
II. Terminology.
III. The Cell.
IV. Functions of Living Cells:
    1. Irritability.
    2. Conductivity.
    3. Contractility.
    4. Metabolism.
    5. Reproduction.
V. Segmentation, Differentiation and Specialization.
VI. Organization of the Body.
    1. Classification of Cells.
    2. Cells Grouped as Tissues.
    3. Tissues Compose Organs.
    4. Organs Constitute Systems.
VII. General Plan of the Human Body:
    1. The Dorsal Cavity.
    2. The Ventral Cavity.

The Study of the Human Body.—To students of human anatomy and physiology the related biologic sciences contribute valuable assistance in helping to understand the body. Embryology, zoölogy, and botany describe not only the origin and nature of plant and animal life but also from a comparative standpoint indicate the relatedness of all living matter. In a narrow sense the study of anatomy is the study of structure. Oftentimes it is quite uninteresting because the meaning of the structure is not interpreted. Contrariwise, anatomy may be most interesting, may even seem vital to the student, when studied in relation to living forms of life in general, and inter-

preted in practical ways affecting man. Thus, anatomy may record the fact of branchial arches in the developing embryo,* but these structures need interpretation to have meaning and significance.†

Other sciences help to make clear the meaning of anatomic structure. Physiology attempts to describe how that structure functions, what it does under certain conditions. Pathology describes the deviations from the normal in structure, no matter how caused. Both of these sciences are dependent for an explanation of the processes of life upon the advances made and to be made in physics and chemistry, and particularly in the newer developments of physical chemistry.

Fig. 1.—The two chief planes of the body: *T*, transverse; *S*, sagittal.

Anatomy as a study would seem quite sterile if pursued alone. What is the origin of this structure, how did it develop, what are its common variations from the normal? These are practical considerations full of meaning and significance. Hence it seems that the beginning study of the human body should include not only the anatomy of the parts but also aspects of embryology, facts of comparative development and evolution, principles of physiology, and the important functions of the body.

Terminology.—In describing the human body it is necessary to have an agreement concerning the use of terms that define positions, give directions, and explain relations. For these purposes anatomists begin with a statement of the anatomic position of the body. This is taken to be an erect position, with the arms hanging at the sides of the body and the palms turned forward. In this position several planes, surfaces, and directions

* The term "embryo" is used while the new individual is in the early stages of development, during the first three months. "Fetus" is the term used to designate the new individual after organs and parts are well formed.

† Branchial arches (gill arches) in the developing human embryo suggest a biologic relationship with fishes, in which they are retained, and with higher vertebrates, in which they are suppressed, as they are in man.

are recognized. There are two chief planes of the human body: the *sagittal*, which passes vertically and divides the body into two equal and symmetric halves, and the *transverse*, which passes horizontally to the sagittal (Fig. 1). There are two surfaces: the *anterior*, *ventral*,* or front, which presents the body in the

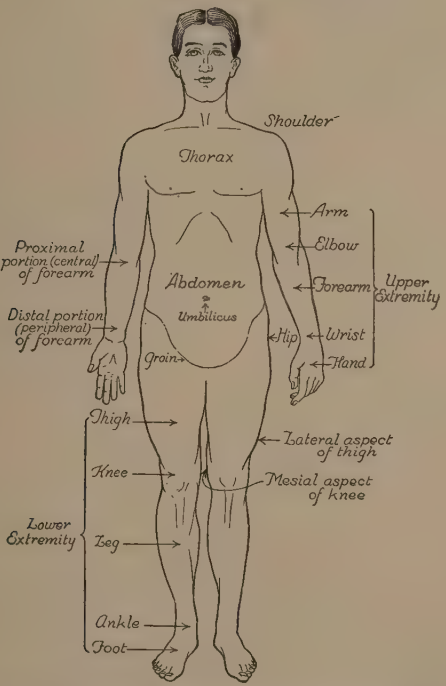

Fig. 2.—Diagram of parts of human body with terminology indicated.

anatomic position toward the observer, and the *posterior*, *dorsal*, or back, which is the opposite surface. It will be seen that these planes and surfaces define the relationship of parts. Other terms

* In zoölogy the head end of the animal is called the anterior; the opposite end, posterior; the under surface, ventral, and the back, dorsal. With the erect position, as in man, the terms "anterior" and "ventral" serve identical purposes, for now the ventral part of the body goes forward. To designate the head end of man the term "superior" is used, and for the opposite end the term "inferior" is at times employed.

are necessary to more specifically locate and to give direction (Fig. 2). *Superior*, *inferior*, *upper*, and *lower* are used to designate parts toward or away from the head end of the body. Parts nearest to the sagittal plane are described as *mesial*, parts farthest from this plane are called *lateral*. The terms *internal* and *external* are used to define within or without relationships of the body or its parts. The *midsternal line* coincides with the sagittal. It is used to locate heart and lung borders to the left and right of it. *Proximal* and *distal*, *central* and *peripheral* are terms used to designate nearness to source or beginning of part, or the opposite. *Homo-*

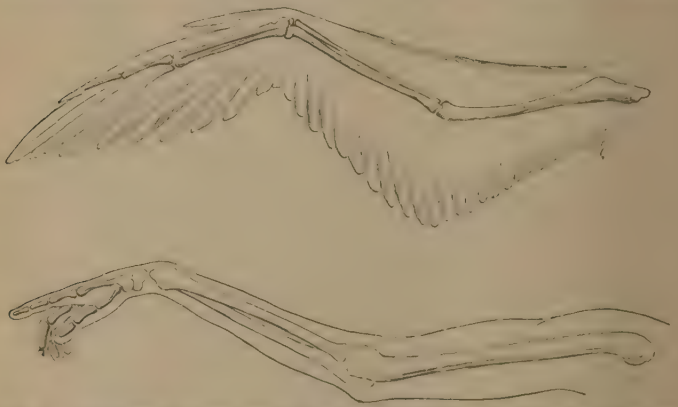

Fig. 3.—The arm of a man and the wing of a bird are homologous; they are not analogous.

logue is a term indicating identical structural characteristics of common origin; *analogue* denotes functional similarity only. Thus the arm of a man and the wing of a bird are homologous, but not analogous structures (Fig. 3).

The Cell.—The body grows from a single structure called a cell.[1] This cell divides and gives rise to many cells through successive divisions. At any early stage all the cells of the embryonic body appear very much alike and receive the name *embryonal cells*. In this stage they resemble simple unicellular organisms, such as the ameba (Fig. 4), which illustrates many of the characteristics of this early cell formation.

A diagram of such a cell (Fig. 5) shows an organized mass called *protoplasm* which is seen to be made up of other constit-

uent parts. The conspicuous portion of the cell is the *cytoplasm* or body of the cell. This appears as a reticular, granular, or homogeneous material according to the state of its activity. The cytoplasm is constantly changing; the life processes of the cell, reflecting simple and complex chemical combinations within the cell, account for a wide variation in structural composition at different times. The *limiting membrane* is usually well marked. In some highly specialized cells (cardiac muscle) the cytoplasm of one cell will be continuous with that of an adjoining cell due to the absence of limiting membrane in certain areas. The *nucleus*

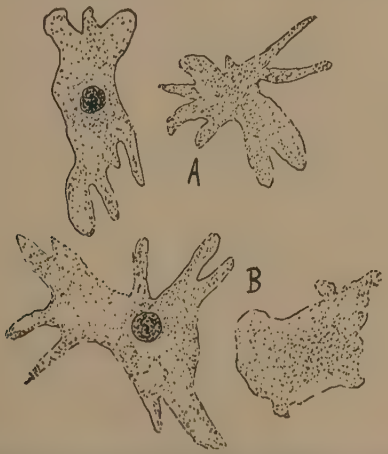

Fig. 4.—An ameba, a simple unicellular organism: *A*, An ameba divided into nucleated and non-nucleated portions; *B*, the same portions after an interval of eight days. (After Hofer.)

is a small body within the cytoplasm. It contains small, irregular masses that stain deeply, called *chromatin*. The nucleus is considered the vital part of a cell because a mass of cytoplasm deprived of its nucleus soon loses its functional power and disintegrates (see Fig. 4). The *nucleolus* appears as a small spheric body within the nucleus. In the cytoplasm is observed a minute body, the *centrosome*, vitally concerned in the phenomena of cell division. It is frequently surrounded by a clear zone, the *attraction sphere*, within which it appears as a minute speck, at times being double.

Functions of Living Cells.—A single cell to live must be able to carry on all the processes necessary for life.[2] Thus it must be able to take in and digest food and remove its waste; it must supply itself with oxygen to oxidize* the food that has been assimilated. It must respond to stimuli in the environment around it; showing a sensitiveness to such stimuli indicates not only its irritability but also its ability to remove itself from, or

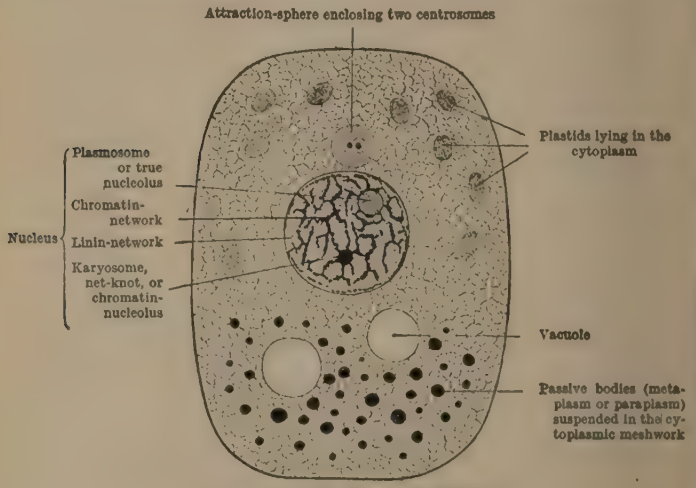

Fig. 5.—Diagram of a cell (Wilson).

to advance toward, the stimulus. Hence it will be able to conduct a stimulus received at one part to another part of the cell. It

* *Oxidation* is the union of oxygen with some other substance, with the production of heat in the process. Unless the oxidation is very rapid the heat may not be perceptible. Most of the oxidations in the body go on very slowly, sufficient heat being produced to keep the temperature of the body at 98.6° F. In conditions of fever with disturbance of the heat-regulating apparatus of the body the oxidation may be more rapid, with resulting increase in temperature.

This oxidation of materials in the cell produces energy according to the characteristics of the cell, one yielding motion, another a secretion, another something else. This activity must be compensated for by a replacement of the materials used up. Hence substances are taken into the cell to restore the used material, and waste must be removed. This dual process is called *metabolism.*

will be able to reproduce itself and give rise to new beings having similar structure and functions. The functions[2] of the cell have been classified as follows: *irritability*, *conductivity*, *contractility*, *metabolism*, and *reproduction*. These manifestations of life quite evenly distributed in simple cells become highly developed when specialization of the cell takes place.

Irritability.—Living protoplasm is able to receive stimuli; it possesses irritability. Dead cells are unable to receive stimulations; are unable to respond by any kind of action. Between these two extremes there are varying degrees of irritability. Some cells in the body are by nature more sensitive to stimuli than others (compare the skin of the finger-tip and the back of the arm, page 492). Also the normal irritability of certain cells may be greatly changed under conditions that favor disturbance in the normal functions of the body. Thus certain cells may be hypersensitive to stimuli (the nerve endings in the skin may be acutely irritable in certain conditions producing an extremely sensitive skin), and, on the other hand, cells may lose their irritability in part (the heart cells in certain conditions of disturbed internal secretions). This difference in irritability and the changes in irritability among cells are due to the physical and chemical constitution of the protoplasm of the cell at the particular time the stimulus is received.

Conductivity.—When a stimulus is received by a cell a reaction follows that is characteristic* of the cell in question. This reaction is carried throughout the cell and may even be conducted to neighboring cells. Nerve-cells show this quality in a very high degree.

Contractility.—The reaction to a stimulus is very frequently expressed as motion. Simple protoplasm shows to a marked degree the power of contractility. With the differentiation of cells in the multicellular animals there is a specialization in function so that some cells retain and develop to a higher degree

* Perhaps another quality should be introduced which might be called *correlation*. Thus a stimulus in one animal may produce one effect and in another a different one. What the effect may be is due to the physiochemic changes in the cells excited by the stimulus (see Forced Movements, Tropisms, and Animal Conduct, by J. Loeb, J. B. Lippincott Co., 1918). This proposal for an additional term is supported by increasing evidence of the influence of the internal secretions on many related processes. The old notion of *nervous correlation* is supplanted by the discoveries of endocrine function (see Internal Secretions, by A. Weil, Macmillan Co., 1924, Chapter).

certain powers originally possessed by all. Thus this power of contractility becomes associated with the differentiated muscle-cells; it is nearly lost in other than muscle-cells.

Metabolism.—All cells possess the power to carry on the processes of life. These are in large part associated with taking certain energy materials and building them up in the protoplasm of the cell and removing the wastes that result from the activity of the cell. Metabolism consists in this dual process, the building-up phase of which is sometimes called *anabolism*, and the waste removal phase *catabolism*. Clearly, all cells carry on metabolic processes, but in the specialization of functions metabolic processes have been peculiarly taken over by the cells of the digestive tract, while other cells, the nerve-cells. for example, have very little metabolic activity.

Reproduction.—The biologist sees living forms as concerned only with the reproduction of their kind. Certainly this power possessed by very simple cells seems to be the end of life, the aim of all activity. Some cells multiply by merely dividing equally the protoplasm and nucleus; in others profound changes go on in which the nucleus is intricately involved. With the specialization of function the reproductive powers are taken over in man and certain other animals by a group of cells (sex cells) that are concerned only with this activity. Certain other cells in the body possess the ability to reproduce themselves (the cells of the skin do; nerve-cells do not), but the creation of a new individual is the work of the sex cells alone.

There are two methods, *direct* and *indirect*, by which cells divide and produce new individuals. The direct method of cell reproduction, called *amitosis*, takes place among the simplest forms of life, such as ameba. It consists in simple division of protoplasm and nucleus in which half of each part goes to the two cells resulting from the division. In complex forms, however, complicated nuclear changes are always apparent, and hence this indirect type, called *mitosis*, may be considered as applicable to man. Details of this type are given in Chapter II.

Segmentation, Differentiation and Specialization.—As a result of processes of life in the sex cell, a series of remarkable changes begin.

First, the sex cell divides, and the resulting cells continue by successive divisions until many cells are produced (Fig. 6). This is called *segmentation*.

Second, there is alteration of the structure of the many cells so that distinctive and distinguishing forms appear. The embryonal cells that looked alike now show *differentiation* (Fig. 6).

Third, this change in structure is the outward sign of alteration of function and the differentiated cells soon exhibit ability to do very well certain functions with loss of ability to do all functions. This is called *specialization* (Fig. 6).

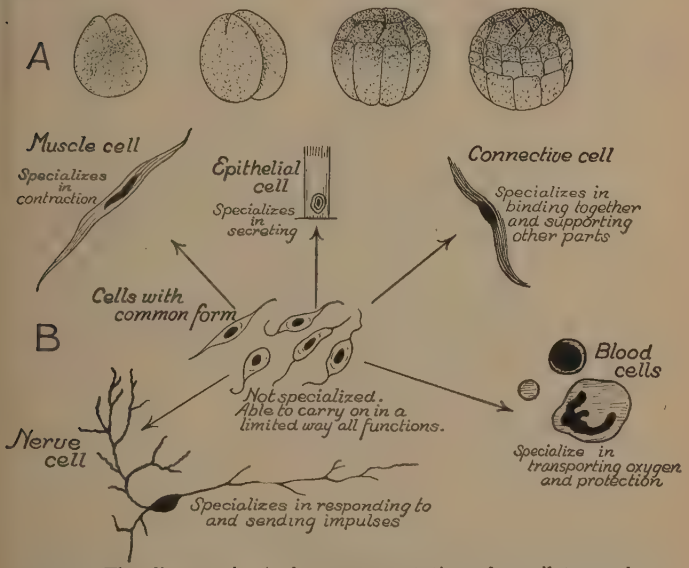

Fig. 6.—The diagram in A shows segmentation of a cell to produce a many-celled mass. B indicates five embryonal cells (in center) that have differentiated in form (note arrows). The specialization in function is indicated also.

These changes, segmentation, differentiation, and specialization go on to some extent at the same time. In a precise manner of speaking there is probably no differentiation without specialization, and vice versa. Whether structure makes function or function makes structure is not determined by the above facts. In the embryo function is at a minimum and yet structure increases rapidly; on the other hand, after birth, function frequently determines structure.[3]

These changes that result in many cells that are distinctive in form and function enable the anatomist to group the cells of the body into particular classes, the classes of cells into tissues, the tissues into organs, and the organs into systems. The sex cell has been metamorphosed. From one cell many different units have resulted, arranged in marvelous fashion to perform exceedingly intricate functions.

Organization of the Body.—The organization of the body may be comprehended by studying the classification of its parts. They may be classified as cells, grouped as tissues, composed as



Fig. 7.—Cross-section of stratified squamous epithelium from the esophagus of man (Böhm, Davidoff, and Huber).

organs, or constituted into systems. These four classifications are described below.

Classification of Cells.—As a result of differentiation and specialization the cells of the fully formed individual may be grouped into the following five classes, performing five functions:

1. *Epithelial* cells covering body surfaces, lining body cavities, and serving as the chief structural elements of all glands (Fig. 7).

2. *Connective-tissue* cells forming the supporting, binding, and connecting parts for the other cells (Fig. 8).

3. *Muscle* cells providing contractile units for the body (Figs. 9–11).

4. *Blood* cells serving as transportation and protective agents for the body (Fig. 12).

5. *Nerve* cells acting as receiving and sending mechanisms (Fig. 13).

Fig. 8.—Another illustration of differentiation. Schematic diagram given to show the development of the different types of connective tissue: *a*, Mesenchymal cells, certain of which are separate, others are joined by protoplasmic branches; *b*, syncytium with large strands of protoplasm and relatively few nuclei; *c*, reticular tissue—the dark fibers are elastic fibers; *d*, white fibrous tissue; *e*, cartilage; *f*, membranous bone. Note how well these cells are adapted for supporting and binding purposes. (Böhm, Davidoff, and Huber.)

Cells Grouped as Tissues.—Groups of like cells bound together by an intercellular substance comprise a *tissue*. Thus a tissue

is an aggregate of like cells, and they may be similarly classified into five groups:

1, *Epithelial tissue;* 2, *connective tissue;* 3, *muscular tissue;* 4, *vascular tissue* (blood and lymph); 5, *nervous tissue.*

Fig. 9.—Smooth muscle cells, teased apart and showing long oval nuclei surrounded by undifferentiated protoplasm (Burton-Opitz).

Fig. 10.—Muscular fibers of the adductor magnus of a dog: *m*, Muscular fiber; *n*, nuclei; *s*, sarcolemma; *e*, *e*, spaces left by the retraction of the muscular substance from the interior of the sarcolemma. (Ranvier.)

Tissues Compose Organs.—As a rule two or more tissues are arranged to perform a special function. Such an organization is called an *organ.* For example, the stomach is recognized as an organ. It is concerned with the function of receiving and digest-

ng food. It is composed of all five tissues as, indeed, most organs are.

Organs Constitute Systems.—A further step in the organization of the body is the grouping together of several organs to accom-

Fig. 11.—Cardiac muscle (Burton-Opitz).

plish a highly specialized piece of work in the body, as in a *system*. At times the organs composing a system are alike or

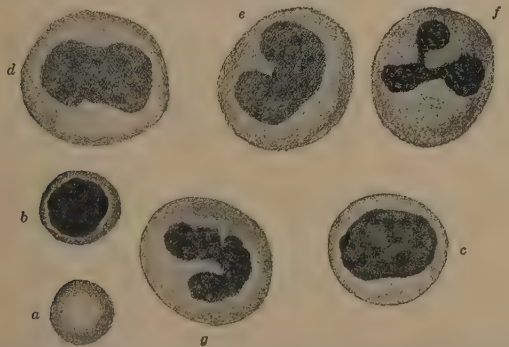

Fig. 12.—From the normal blood of man; × 1200 (from dry preparation of H. F. Müller): *a*, Red blood-cell; *b*, lymphocyte; *c* and *d*, mononuclear leukocytes; *e*, transitional leukocyte; *f* and *g*, leukocytes with polymorphous nuclei. (Böhm, Davidoff, and Huber.)

very similar, *e. g.*, the muscles; at other times they vary widely, *e. g.*, the excretory system. The formation of a system has unity

as regards function and represents, therefore, the tendency toward physiologic harmony. No matter how diverse the structure of the organs in a system, they are alike in their co-operative endeavor to secure the special ends desired. Nine systems are recognized in the body. These and the organs composing each are as follows:

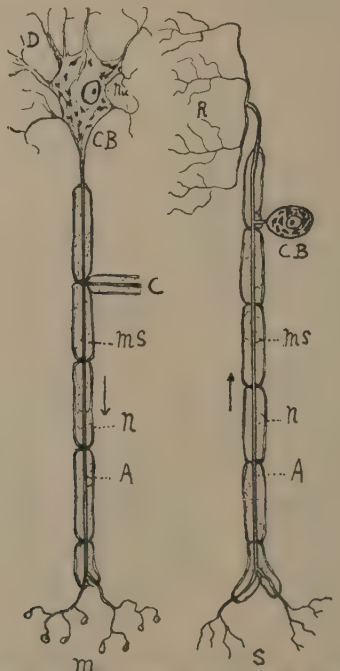

Fig. 13.—*M*, End-organ of efferent neuron; *S*, end-organ of afferent neuron; *A*, axon; *MS*, myelin sheath; *N*, neurilemma; *C*, colateral; *CB*, cell body; *D*, dendrites; *Nu*, nucleus and nucleolus; *R*, sensory terminals. (Burton-Opitz.)

1. The *skeletal* system comprises the bones of the skull, vertebral column, thorax, shoulder girdle, pelvis, upper and lower extremities. These bones are assembled in a definite order and are held together by ligaments.

2. The *muscular* system includes the muscles of the skeleton and the muscles of the blood-vessels and hollow organs (viscera).

3. The *digestive* system includes the teeth, salivary glands, esophagus, stomach, liver, gall-bladder, pancreas, small and large intestines.

4. The *respiratory* system comprises the nose, pharynx, larynx, trachea, bronchi, and lungs.

5. The *circulatory* system comprises the heart, blood-vessels, lymphatics, blood, and lymph.

6. The *excretory* system comprises the kidneys, ureters, bladder, urethra, and, in a limited sense, the skin and lungs.

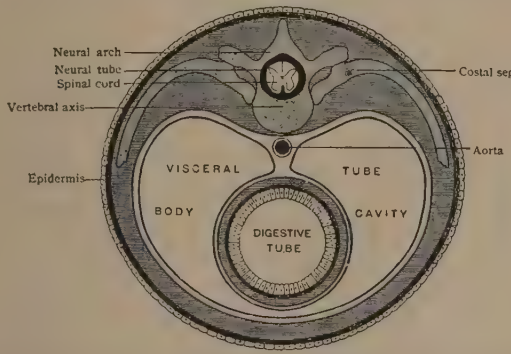

Fig. 14.—Diagrammatic plan of vertebrate body in transverse section (after Wiedersheim).

7. The *nervous* system comprises the brain, spinal cord, and peripheral nerves in the cerebrospinal system, and the chain of ganglia, plexuses, and nerves of the autonomic system.

8. The *reproductive* system comprises the ovaries, uterus, tubes, and the vagina in the female, and the testes, vas deferens, seminal vesicles, prostate, penis, and urethra in the male.

9. The *endocrine* system comprises the thyroid, thymus, adrenals, pituitary body, pancreas in part, pineal gland, ovaries, and testes. The liver also acts as a gland of internal secretion.

This organization of the body provides in health a harmonious relationship between the different systems. High specialization demands co-operation, for the whole is dependent upon the parts.

General Plan of the Human Body.—In the classification of animal life man is known as a vertebrate. In the group of vertebrates the characteristic structure is the possession of a spine

or vertebral column, extending from the head to the tail end of the animal. Striking characteristics in the vertebrate plan are bilateral symmetry and body cavity formation. A transverse section (Fig. 14) of the plan of vertebrate body shows the symmetric arrangement, and a longitudinal section (Fig. 15) reveals the cavities.

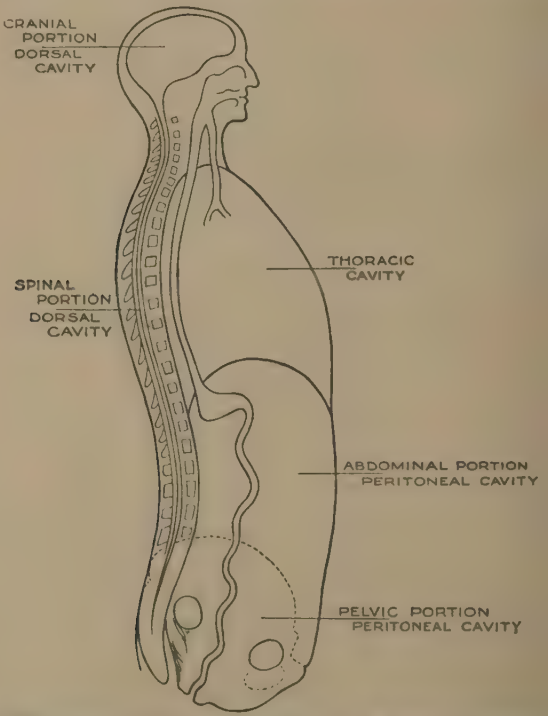

Fig. 15.—Diagram of the body cavities. The spaces indicated are not to be considered as empty. They exist only as potential cavities, but they are all closed (peritoneal in female excepted).

The *dorsal cavity* is a single cavity with two well-defined divisions:

1. The cranial portion, in which lies the superior part of the nervous system, the brain; and

2. The spinal portion, in which lies the spinal cord.

The *ventral cavity* presents two well-defined divisions, completely closed to the outside (peritoneal in the female excepted). These cavities are the thoracic and peritoneal. They should not be confused with the lumina, or passages, or spaces in the respiratory or digestive tracts. The term "cavity" is often used carelessly, *e. g.*, oral cavity, nasal cavity, orbital cavity, but such use is improper. Such passages are not to be classed with the cavities, which are true, closed spaces. However, in the female, the peritoneal cavity is not closed because connection with the outside of the body is made via the vagina, uterus, and fallopian tubes.

1. The thoracic cavity is made up of the pericardial portion, in which are the heart and the beginning of the great vessels, and the pleural, in which are the trachea, esophagus, lungs, thymus, and adjacent arteries, veins, and lymphatics.

2. The peritoneal cavity has two divisions that are confluent and only defined artificially. The upper or abdominal portion contains stomach, liver, gall-bladder, spleen, pancreas, small and large intestine. The lower or pelvic portion contains the sigmoid, rectum, and bladder; in addition, in the female, uterus, tubes, and ovaries, and in the male, vas deferens, seminal vesicles, and prostate.

PRACTICAL EXERCISES

1. Study a one-cell organism. Paramecia may be secured from a hay infusion, which is made as follows: Obtain grasses from the side of a river or pond. Place grasses in a jar with water and set the jar in a light warm spot, preferably near a window. In several days small organisms can be collected from the scum that develops on top of the water. Place a drop of this material on a slide, cover with a cover-glass, and examine under the low power of the microscope.

2. Study slides* of the malarial parasite (Fig. 16).

3. Study slides of different bacteria.

4. Study slides of different types of cells, preferably of some showing the direct type of cell division.

5. Dissect a frog or larger animal and note tissues and organs. If a cat or a dog is dissected, the chief organs of the nine systems of the animal body may be studied.

QUESTIONS

1. Define the sagittal plane. Is the sagittal plane anteroposterior?

2. Locate the inferior eyelid, the lateral wall of the nasal passage, the external surface of the teeth, the proximal end of the forearm, the peripheral

* Permanent preparations of cells and tissues may be obtained from supply houses, such as Ward's Natural Science Establishment, Rochester, N. Y., and Marine Biological Laboratory, Woods Hole, Mass.

portion of the ear, the mesial aspect of the arm, and the distal portion of the thumb.

3. What is irritability among cells? What is conductivity? Contractility? Metabolism? Reproduction?

4. Describe what is meant by differentiation and specialization.

5. Name the organs in the different body cavities. Do real cavities exist? What is a potential cavity? Does nature permit empty spaces to exist?

6. What is oxidation?

7. Name the systems of the body.

8. What are the five classes of tissues?

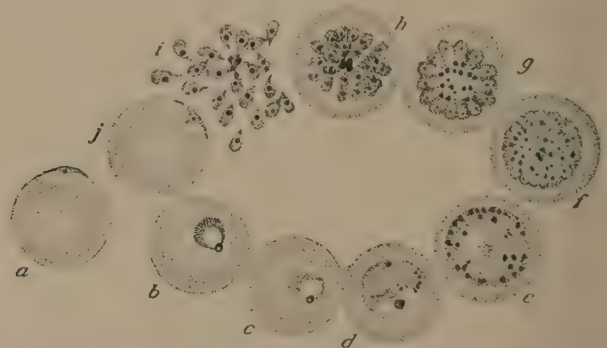

Fig. 16.—Reproduction of the malaria parasite in a red blood-cell: *a*, Entering the cell; *b*, within the cell; *c h*, development and segmentation of the parasite; *i*, rupture of red cell setting young parasites free; *j*, one of them entering a red cell. The process goes on with continued destruction of the red blood corpuscles until the parasites are killed by medical treatment. (From Williams, Healthful Living, published by The Macmillan Company.)

REFERENCES FOR FURTHER STUDY

1. Wilson, E. B.: The Cell, The Macmillan Co., New York, 1911, pp. 1–62.

2. Burton-Opitz, R.: An Elementary Manual of Physiology, W. B. Saunders Co., Philadelphia, 1928, pp. 17–62.

3. Adami, J. G.: Principles of Pathology, vol. i, Lea & Febiger, Philadelphia, 1908, pp. 82–95.

Bigelow, M. A. and A. N.: Applied Biology, The Macmillan Co., New York, 1911, pp. 10–18, 57–65, 561–573.

CHAPTER II

FORMATION OF THE EMBRYO

I. Development of the Human Body:
   1. Maturation of the Ovum.
   2. Fertilization of the Ovum.
   3. Segmentation of the Ovum.
   4. The Appearance of the Three Embryonic Layers.
   5. The Ectoderm and the Nervous System.
   6. The Mesoderm and the Somites.
   7. The Entoderm and the Alimentary Canal.

II. Derivatives of the Three Embryonic Layers:
   1. Derived from the Ectoderm.
   2. Derived from the Mesoderm.
   3. Derived from the Entoderm.

III. External Appearance of the Fetus.

IV. Nourishment of the Fetus.
   The Placenta.

V. Composition of the Body.

VI. Cells and Heredity:
   1. Biologic Inheritance.
   2. Maternal Impressions.

Development of the Human Body.—The human adult, with all his wonderful adaptation, complex organizations, and marvelous powers, is a development of the newborn child. Both adult and child are to be considered as the product of the fusion of two sex cells—one the *ovum* of the female and the other the *spermatozoön* of the male—which have specialized and differentiated as they grew in the uterus of the mother.[1] To follow the changes that result from this union is an important step in the study of human anatomy and physiology.

The ovum, given off from the ovary of the female, is a rounded mass or organized substance called an egg-cell (Fig. 17). It presents a limiting membrane around which is a clear area surrounded by remains of the follicle in which it developed. Inside of the limiting membrane is an inner organized material called protoplasm, within which is a sharply defined smaller body, the *nucleus*, containing the germinal spot or *nucleolus*. In preparation for the reception of the spermatozoön the ovum goes through a stage known as *maturation of the ovum.*

Maturation of the Ovum.—The ova develop in the ovary in nests or groups of cells formed by the germinal epithelium of the organ (Fig. 18). As the ovum approaches maturity the nest in which the ovum rests, called the Graafian follicle, develops a space which gradually enlarges to considerable size. When the cell is ready to be discharged from the ovary, the follicle ruptures and the matured ovum is set free from the ovary to enter the tubes that will conduct it to the uterus.

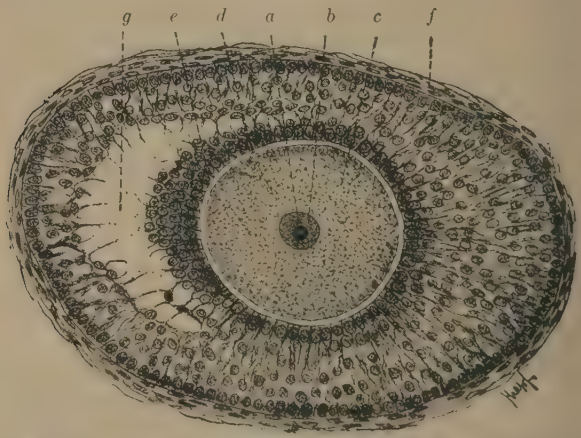

Fig. 17.—From section of cat's ovary, showing ovum and follicle; × 225. *a*, Germinal spot; *b*, germinal vesicle; *c*, ovum; *d*, zona pellucida; *e*, corona radiata; *f*, covering of follicle; *g*, beginning of formation of the cavity of the follicle. (Böhm, Davidoff, and Huber.)

The essential process of maturation, however, is the series of changes that takes place in the nucleus of the ovum just before the rupture of the Graafian follicle. The chromatin of the cell arranges itself in a loose reticular network or skein, and then breaks up transversely to form structures known as *chromosomes*. Later the chromosomes split longitudinally. This splitting results in double the number of original chromosomes. The nucleus of the ovum migrates to the periphery of the cell and undergoes a division in which half of the chromatic material is extruded from the cell as the first polar body (Fig. 19). When the first polar body is formed half of the chromosomes remain in the nucleus of the maturating ovum. This process is repeated

in the formation of the second and third polar bodies (the third resulting from division of the first), with the result that the masses of chromatin are reduced to one-half the normal quota of chromosomes.* For example, if the normal number of chromosomes is 8 this is increased to 16 by the splitting process. With the division of the chromatic masses 4 chromosomes are given to each of the 3 polar bodies and the maturing egg-cell. When maturation is completed the egg-cell then contains 4, or one-half of the original number of the species.

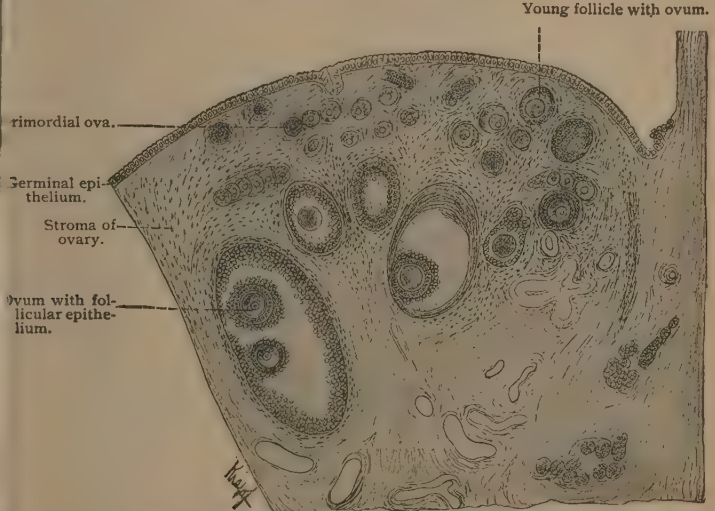

Fig. 18.—Section from ovary of adult dog. Notice the follicles in various stages of development. At the left is a follicle with ovum ready for eruption (copied from Waldeyer).

While the ovum undergoes these changes after it is fully formed, the spermatozoön has acquired half of the number of chromo-

* It is an established fact that each species of plant or animal contains an exact number of chromosomes. The union of two cells without a loss of chromatic material would result in an increase in the number of chromosomes. Wilson (The Cell, p. 206) quotes Bardeleben in giving the number of chromosomes in man as 16. Some authorities (Winiwarter, Evans) give 48 chromosomes for the female and 47 for the male. It is believed that sex is determined by certain chromosomes known as X and Y chromosomes.

somes characteristic of the species during the process of its development, so that when the two sex cells unite the cell resulting from the union contains the exact number characteristic of the species.[4]

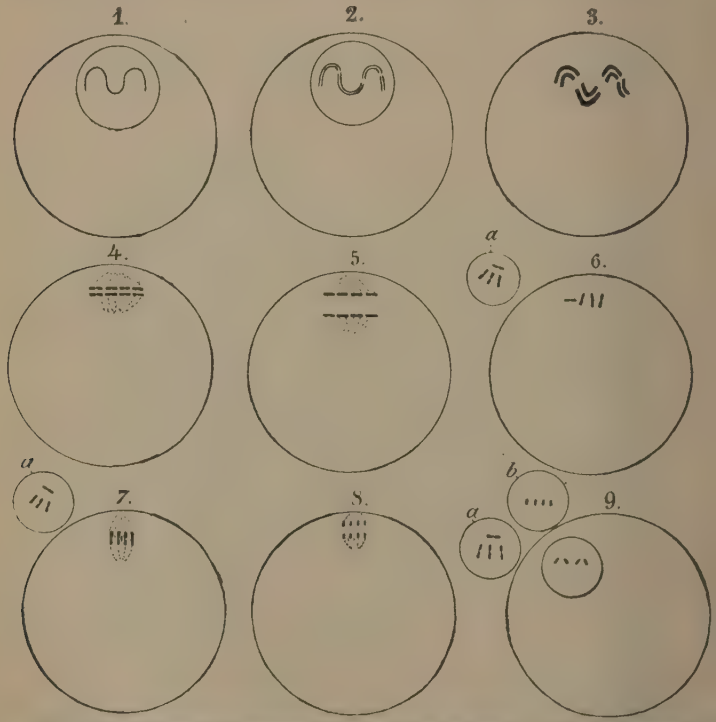

Fig. 19. Schematic representation of the behavior of the chromatin during the maturation of the ovum: *a*, *a*, *a*, First, and (*b*) second polar body; third polar body comes from the first. (Böhm, Davidoff, and Huber.)

Fertilization of the Ovum.—After maturation of the ovum *fertilization* may take place on entrance of the spermatozoön into the cell (Fig. 20, A, B). Soon the nuclear material of the male cell, now called the *male pronucleus*, and the nuclear material of the female cell, now called the *female pronucleus*, unite to form one nucleus from which continuing segmentation goes on. The

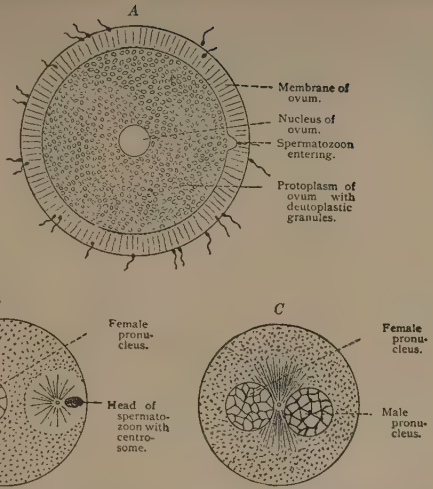

Fig. 20, A.—Diagrams of the process of fertilization, after Boveri: *A*, The ovum is surrounded by spermatozoa, one of which is in the act of penetration. Toward it the yolk is pushed forward in a short, rounded process. *B*, The tail of the spermatozoön has disappeared. Beside the head is a centrosome with polar radiation. *C*, The pro-nuclei approach each other.

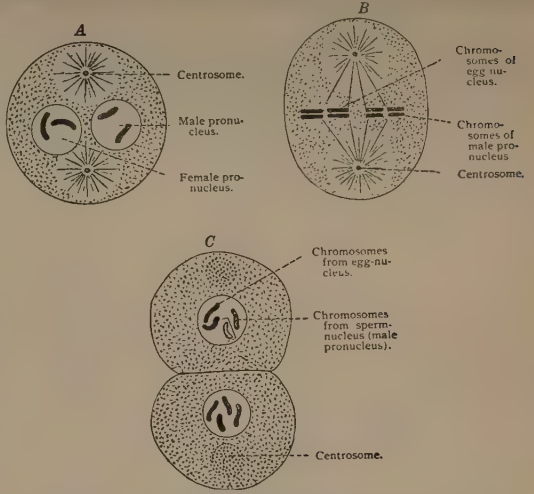

Fig. 20, B.—Diagrams of the process of fertilization, after Boveri: *A*, Chromosomes have formed. The centrosphere has divided. *B*, The double chromosomes of the two pronuclei lie in the equatorial plane of the ovum. *C*, The ovum has divided. Chromosomes from the male and female elements are seen in equal numbers in both daughter nuclei.

ovum has been fertilized and the new individual is started on its way.

Segmentation of the Ovum.—The process of segmentation is a division in which the fertilized cell divides at first into two, then four, eight, etc. (Fig. 21). As the segmentation continues there results a mass made up of many cells that result from

Fig. 21.—External view of segmentation of an ovum: 1, Unsegmented ovum; 9, advanced segmentation. (After A. C. Eycleshymer.)

division of nuclei and protoplasm of other cells. Soon, however, a cavity develops within the mass. This cavity increases rapidly in size and with accompanying changes in the outer cells, there results a group of cells massed at one spot or pole, and a thinned-out layer of cells that completes the wall of the cavity (Fig. 22).

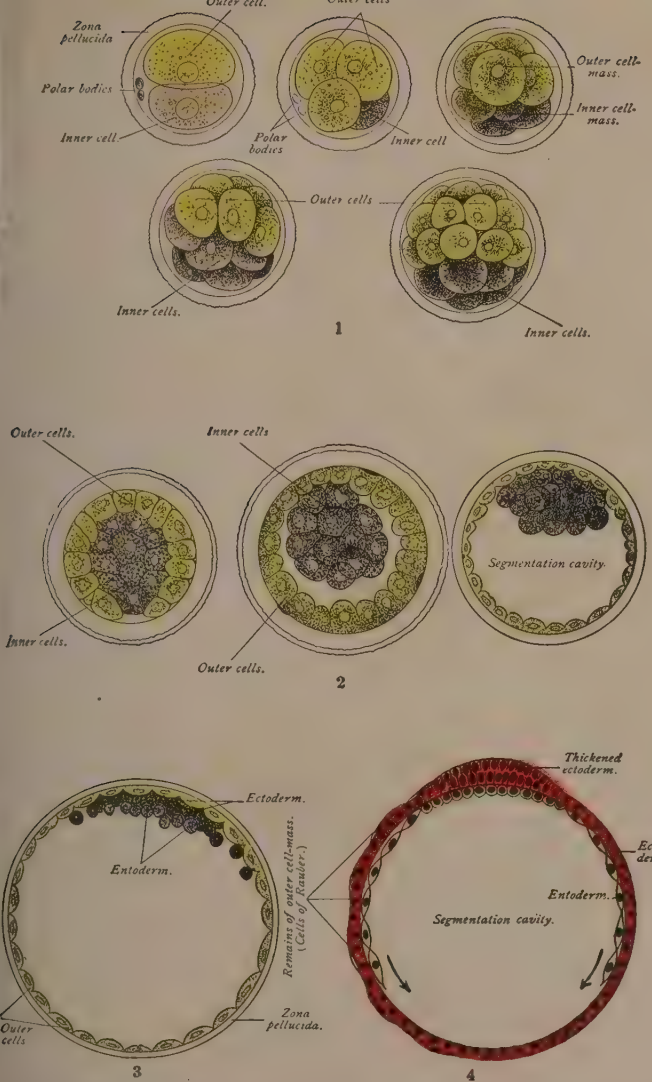

Fig. 22. -1. Diagrams show external views of segmentation of the ovum. (Allen Thomson after von Beneden). 2. Diagrams showing internal view of segmentation and cavity formation, differentiation of layers. (Allen Thomson after von Beneden). 3, 4. Diagrams showing the first two layers of the segmented cell (Bonnet).

The Appearance of the Three Embryonic Layers.—Segmentation of the fertilized ovum has produced then many cells arranged in a sphere around a central cavity with a cluster of cells at one spot. This cluster of cells is the center of a number of remarkable changes. First there is a rearrangement into three layers (Fig. 23): an outer layer, called the *ectoderm*, a middle, called the *mesoderm*, and an inner, called the *entoderm*. These three layers undergo rapid modification to produce the varied organs and arrangements in the embryo. The exact changes during the first days is not known but it is reasonable to suppose that they are similar in all mammals. The cluster of cells gathered at one

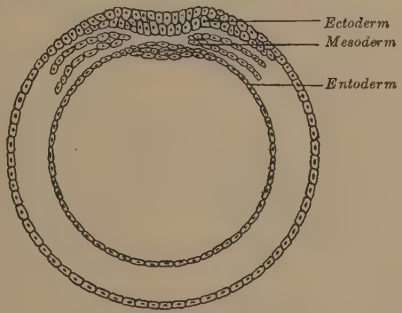

Fig. 23.—The developing ovum divides into three layers.

pole of the segmenting cell marks the body of the embryo (Fig. 24). The remainder of the cell is the yolk sac which in man is small. A cross section through the mid part of the embryo in Fig. 24 would show the three layers as indicated in Fig. 25. As the embryo grows a number of significant changes in the three embryonic layers appear.

The Ectoderm and the Nervous System.—From the ectoderm and along the central axis of the embryonic body arises the spinal cord. At the fore end the brain develops. The series of ectodermal changes is very interesting (Fig. 26). In the diagram, there is shown a slight thickening of the ectoderm at the site of the future nervous system, followed by a proliferation of cells on either side of a groove. Finally, the continued upward and mesial extension of the lateral masses converts a groove into a cavity surrounded by ectodermal cells. This early cavity is



Fig. 24.—The segmentation of the cell produces the embryo (From Marshall "Vertebrate Embryology," in part after Van Beneden and Julin); × 10.

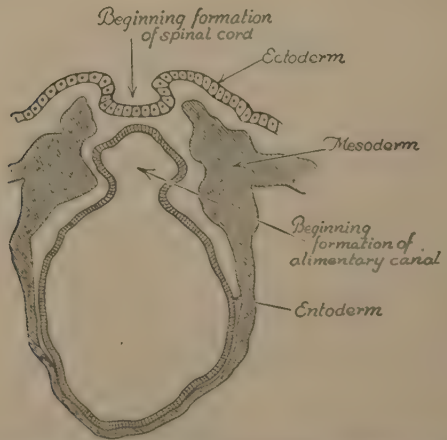

Fig. 25.—Diagrammatic cross-section of embryo indicated in Fig. 24 taken about in the center of the body.

the forerunner of the spinal canal and the cranial ventricles; the ectodermal cells of this area constitute the tissue of the brain and cord. By thirty-one days nerves have formed and connecting pathways from cord and brain to distant parts have been established (Fig. 27).

Fig. 26.—*a*, Shows thickening of ectoderm (after Kölliker) × 80; *b*, the beginning neural folds (after Marshall) × 200, *c*, the formed structures (after Marshall), × 100.

The Mesoderm and the Somites.—While the above changes have been occurring in the ectoderm, interesting modifications have taken place in the middle layer. Transverse constrictions have divided the mass near the neural canal, forming segmented portions called *somites*. This segmentation involves only the mesoderm and corresponds with the vertebral and neural segments of the body. The somites have three parts: (1) One portion gives rise to the muscles of the back and trunk, (2) one contributes bone, cartilage, and ligaments to the vertebral area, and (3) the third forms the excretory portion of the kidneys.

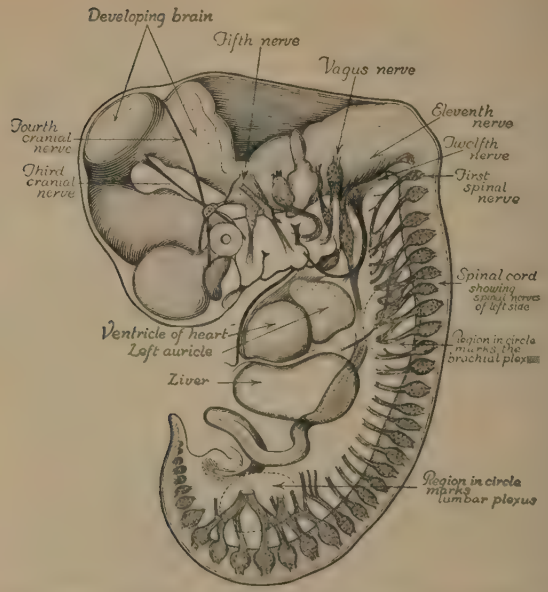

Fig. 27.—Diagram of embryo with brain, spinal cord, and spinal nerves in definite form (Marshall).

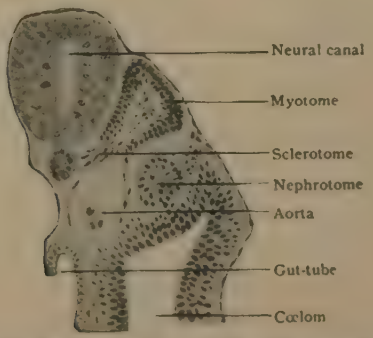

Fig. 28.—Transverse section of human embryo of about twenty-one days, showing differentiation of somite; × 90 (Kollmann).

Laterally to the somites the mesoderm splits (Fig. 28) into two layers, giving rise to a layer of *parietal mesoderm*,* and a layer of *visceral mesoderm*, between which is enclosed the body cavity.

The Entoderm and the Alimentary Canal.—A section of an embryo at an early date (Fig. 25) shows the entoderm converging mesially with the accompanying layer of visceral mesoderm to form the alimentary canal. The blood-vessels arising in the visceral mesoderm become now the vessels of the visceral organs of the thorax and abdomen (Fig. 29). The abdominal wall closes in the sagittal line except for the attachment of the umbilical cord, and a remnant of the yolk sac and stalk seen in

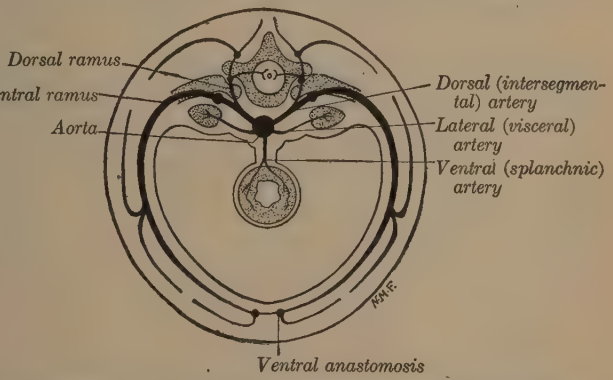

Fig. 29.—Diagram of the trunk, in transverse section, showing the arrangement of the aortic branches (Prentiss and Arey).

animals where the yolk of the egg is the only source of nourishment during the period of development. In the human the umbilical cord carries the umbilical vessels connecting fetus and placenta of the mother. Dorsal to the forming alimentary canal the two aortæ in the mesoderm swing mesially to unite and form the one main trunk seen in man. Laterally to the somites are the cells of the beginning genito-urinary system.

Derivatives of the Three Embryonic Layers.—The differentiation of the developing embryonic cells into three layers is followed

* The terms "parietal" and "visceral" are used frequently in anatomy. The former refers to the covering of the body cavity, the latter to the viscera or hollow organs of the body cavity. The parietal mesoderm and ectoderm form the somatopleure (body wall), the visceral mesoderm and entoderm form the splanchnopleure (visceral organs).

by further changes, so that they lose their embryonic character, in which all the cells look alike and take on the distinguishing marks of their future state. As a result of this differentiation we may note the structures that arise from the different layers.



Fig. 30.—Early embryos (DeLee, from His).

Derived from the Ectoderm.—1. The epithelium of the skin together with the appendages of the skin, as the hair, nails, and sebaceous and sweat glands.

2. The epithelium of the nasal and oral passages together with the salivary and other glands of the mouth and nose.

3. The enamel of the teeth.

4. The nervous system.

Derived from the Mesoderm.—1. The muscles of the body.

2. The connective tissues of the body, as bone, cartilage, dentin of the teeth, ligament, tendon, and areolar tissues.

3. The kidneys and ureters, sex glands, and passages in part.

4. The heart, blood- and lymph-vessels, blood, and lymph.

5. The lining of the pericardial, pleural, and peritoneal cavities.

Derived from the Entoderm.—1. The epithelium of the digestive tract, including the epithelium of the glands emptying into the tract, as the liver and pancreas.

2. The epithelium of the respiratory tract.

3. The epithelium of the bladder and urethra.*

4. The epithelium of the thyroid and thymus.

External Appearance of the Fetus.—Continual cell division and differentiation in the human embryo proceeds through different stages to assume gradually the external features of the human from at about the second month (Fig. 30). During the

* A small portion of the bladder is mesodermal and part of the urethra is ectodermal.

fifth month the first fetal movements are observed. In the sixth month a conspicuous increase in size and weight occurs. This is the period of greatest absolute growth. During the seventh, eighth, and ninth months the fetus progressively assumes the characteristics recognized at birth. The nervous and digestive systems make their final adjustments, surface fat is deposited, hair appears, and the fetus is ready to be born as the human infant.

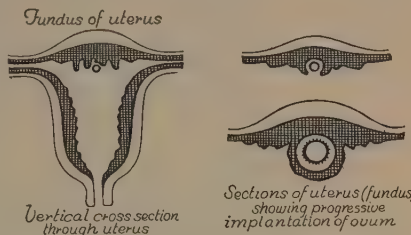
Fundus of uterus
Vertical cross section through uterus
Sections of uterus (fundus) showing progressive implantation of ovum

Fig. 31.—Diagrams showing implantation of ovum in mucous membrane of uterus.

Nourishment of the Fetus.—In birds the nourishment of the fetus is furnished by the yolk sac of the developing egg. In ova with little yolk, as in man, the nourishment is provided by means of a structure, called the placenta, that is formed from both mother and embryo. At an early stage the fertilized

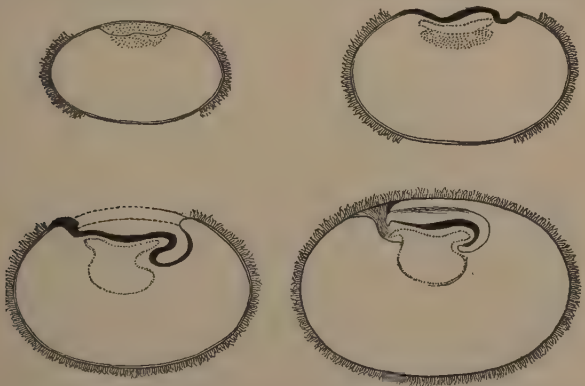

Fig. 32.—Diagrams showing formation of membranes and placenta (His).

ovum will be found embedded in the mucous membrane of the uterus (Fig. 31) which has responded to the presence of this cell by changes in the lining membrane of the organ.

As the embryo develops rapidly at one pole two changes occur to alter its position: the embryo itself becomes depressed

Fig. 33.—Six weeks' ovum showing chorion (DeLee).
Villi arise over the entire chorion, but only those at the placental site develop; the others atrophy at an early stage.

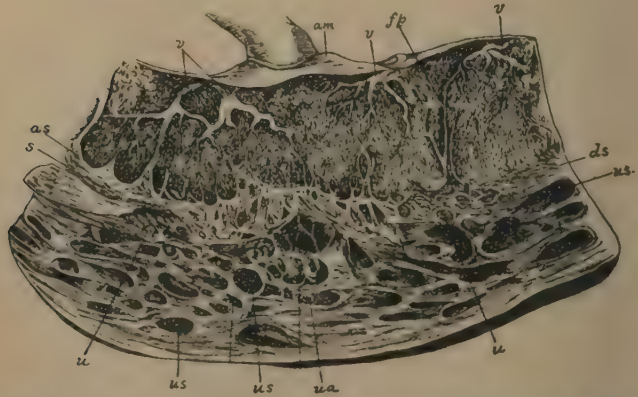

Fig. 34.—Section through uterine wall and attached placenta: *u*, Uterine wall rendered spongy by greatly developed uterine sinuses (*us*); *ua*, branches of uterine artery; *s*, line of separation; *fp*, fetal portion of placenta, consisting of a mass of vascular fetal villi (*v.v.v.*), surrounded by the maternal blood-sinuses (Wagner).

into the vesicle and folds of the outer membrane turn up on all sides to cover the embryo (Fig. 32). The outer membrane of the developing embryo, celled the chorion, has numerous projections, known as villi (Fig. 33). At the site where the embryo retains connection with the chorion the villi become more numerous and greatly enlarged. Richly supplied with blood vessels

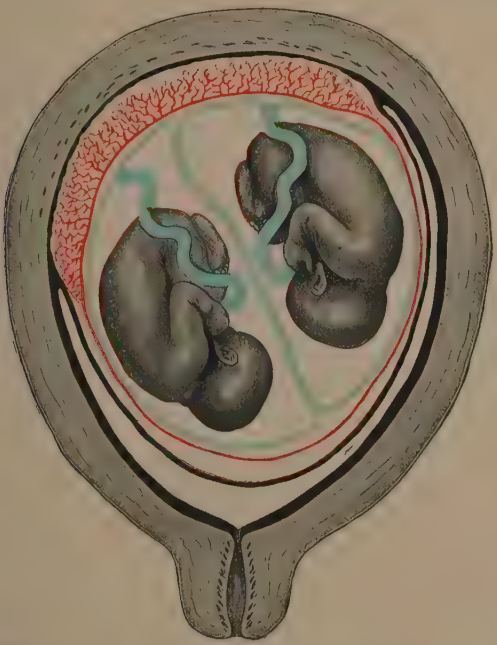

Fig. 35.—Diagram of the development of homologous or single ovum twins from ovum implanted in the fundus of the uterus (DeLee).

from the embryo and in close contact with maternal blood spaces, this structure makes possible the nourishment of the child. This structure formed from both mother and embryo is the *placenta.*

The Placenta.—The placenta then is the organ by which the nutrition of the embryo is effected (Fig. 34). Although composed of both embryonic and maternal tissues, nevertheless in

all respects the fetal and maternal circulations are separate and distinct. Moreover, no nerves from the mother reach the embryo (Fig. 35).

It follows, therefore, that the circulations of mother and fetus pass in a series of closed tubes that are separate and distinct for the two individuals. Fluids, waste, food materials, and other substances transferred from one individual to the other must pass through the walls of the thinnest vessels to reach the other circulation.

It is obvious, therefore, that the nourishment of the pregnant mother is an essential condition for the nourishment of the fetus. Its growth and development are dependent not only upon the quality of the germ cells which produced it but also upon the food, mode and conditions of life of the mother during the period of gestation.[2]

Composition of the Body.—Considered physiologically the body is composed of power units capable of transforming, releasing, or using energy. These units are the cells of the body acting individually or as groups, which is more common. Considered chemically the composition of the body shows the following chemical elements: carbon, hydrogen, nitrogen, oxygen, sulphur, phosphorus, chlorin, fluorin, iodin, silicon, sodium, potassium, calcium, magnesium, lithium, iron, manganese, copper, and lead. These elements are found combined in the body sometimes in the form of salts, often as parts of the protein molecule or constituents of the tissues.

Analysis of the embryo and the full-grown fetus shows that during intra-uterine life there is a constant accumulation of chemical material. The following, quoted by Jordan,[3] illustrates the above statement:

ANALYSES OF THE EMBRYO AND FULL-GROWN FETUS*

Age.	Total weight, grams.	Dry matter, grams.	Water, grams.	Dry matter contains:		
				Ash, grams.	Protein, grams.	Fat, grams.
Four months	36.5	3.00	33.5	0.33	1.77	0.20
Six months	261.8	39.10	322.7	7.01	24.13	2.60
Full grown	3294.0	855.52	2440.8	83.00	388.69	299.70

* From Jordan's Principles of Human Nutrition. Courtesy of The Macmillan Company.

The chemical nature of the body is shown by an analysis of the ash, which is given by Jordan, as follows:

COMPOSITION OF THE ASH OF A NEWBORN CHILD*

	In total ash, grams.	In 1000 grams body weight, grams.
Potassium oxid (potash)	1.64	0.88
Sodium oxid (soda)	6.20	3.35
Calcium oxid (lime)	25.40	13.73
Magnesium oxid (magnesia)	0.67	0.36
Ferric oxid	1.15	0.61
Phosphorus pentoxid	22.81	12.25
Chlorin	3.50	1.89
Total	61.37	33.07

Cells and Heredity.—It is a common observation that like tends to produce like. A bird produces eggs that will hatch birds and not frogs, the acorn will develop the oak and not some other kind of tree. In similar fashion sex cells of man develop into individuals of the human race and, in fact, into that particular type of which the parents are representatives. Probably the chromosomes are the bearers of heredity, and hence the new individual is a complex of the male and female chromosomes that result after fertilization of the ovum.[4]

After the fertilization of the ovum any characteristics developing in the individual are said to be acquired.[5] After birth many changes in structure due to use or accident occur. Thus, loss of certain parts by surgical operation, development of muscles by exercise, are acquired characteristics. These changes are not transmitted to new individuals because they do not influence the chromosomes, the agents for the transmission of hereditary characteristics.

Due to causes as yet unknown and unexplained individuals may be born with defect of structure which is transmitted to new individuals.[6] The struggle for existence and natural selection in a primitive world easily explain the rise and perpetuation of different species. How far these forces are operative today, opposed as they are by the effort of society to preserve all life whether fit

* From Jordan's Principles of Human Nutrition. Courtesy of The Macmillan Company.

or not,* and to select artificially for preferment individuals that would fail in a more primitive environment, is not known. However, certain general principles regarding heredity are known.

Biologic Inheritance.—Heredity in a strict sense is the transmission of "particular germinal organization"† from parents to offspring. The germ-plasm from which the new individual arises by differentiation produces many different structures with widely varying functions. Just how these parts develop does not have to



Fig. 36.—Illustration of well developed hairy appendage in man.

do directly with heredity, although heredity may limit the possible development of the individual. The problems of heredity are further complicated by variation in which the factors of the environment influence the development of the hereditary possibilities.

* Degenerate types show characteristic markings that are known as stigmata of degeneration. Common stigmata are: (1) Receding foreheads indicating incomplete development of frontal lobes of brain; (2) prognathism, a prominence of the maxillæ; (3) the "canine" ear; (4) prominent superciliary ridges; (5) nipples placed too high and supernumerary nipples.

† Conklin, E. G.: Heredity and Environment, Princeton University Press, Princeton, 1917, p. 522.

The central fact of heredity discloses that the individual arises from the germ-plasm of his parents. The differentiation of this germ-plasm produced him, an individual with a body (somatic characteristics) and a germinal power (germinal characteristics). What he develops into or is capable of arises out of the facts of his parental germ-plasm.

The chromosomes are considered the bearers of heredity. They are still further divided into *determiners*, a term now quite generally used to distinguish the influences in the chromosomes which determine the development of any particular character. Moreover, these influences are recognized as *dominant* or *recessive*, meaning by a *dominant character* "a character inherited from one parent which develops to the exclusion of a contrasting character of the other parent,"* and by recessive, an undevelopment of that character in the presence of a dominant. Thus, a particular character of a parent may be present in the offspring because it is a dominant character, or it may not appear because it is a recessive, although a recessive not appearing may remain latent to appear in later generations. An individual may follow one parent, or it may be a blend of the two, or there may be a progressive inheritance in which the individual exhibits characters not present in the parents at all and explained as spontaneous and sudden variations. Or, finally, the individual may exhibit a retrogressive inheritance in which he reverts to a lower form in the animal series. An illustration of such reversion is shown in Fig. 36.

Maternal Impressions.—From this discussion of heredity it is clear that what an individual shows at birth is dependent upon the differentiation of the germ-plasm, the ovum, and spermatozoön derived from the parents. That differentiation is conditioned by intra-uterine influences. What these are and how powerful they may be are important because of the quite common belief in maternal impressions. Keeping the facts of heredity in mind, it may be stated here that *there is no nerve connection between mother and fetus and no direct circulatory connection.* The possible avenue of communication between the two is by the passage of substances in solution through the walls of the vessels of placental and fetal circulations. This, of course, is real and, as Abderhalden suggests, many congenital deformities may be the result of altered maternal internal secretions that pass from

* Conklin E. G: Heredity and Environment, Princeton University Press, Princeton, 1917, p. 522.

placenta to child. However, it should be remembered that the fetus is well formed by the third month and that usually the terrifying experiences related by the mother *occur in the later months* of pregnancy. Nearly all individuals in a space of nine months experience unpleasant situations. They are usually forgotten except when a mother gives birth to a child deformed or marked in some fashion. The experience is then resurrected to explain the condition. This can usually be explained much better in other and scientific fashion. Umbilical cord markings and vascular nevi (birthmarks) are explained by well-known factors. Instances of arrested development and intra-uterine amputations are more satisfactorily classed as congenital defects. This is better than to rely upon the rather magical and mysterious influences of maternal impressions.

PRACTICAL EXERCISES

1. Examine epidermis from growing root-tip of an onion, showing cells in various stages of division. (See Wilson, E. B., The Cell, p. 4, Fig. 2.) Study prepared slides of animal cells showing indirect cell division.

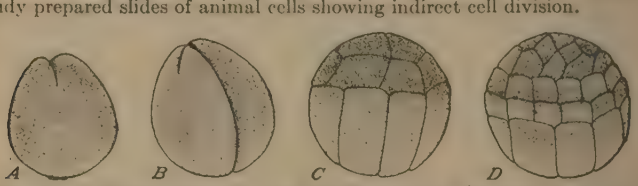

Fig. 37.—Different stages in the development of the frog's egg (*A*) to form the body of the frog. In *D* the egg (ovum) has divided many times, and presently these cells will begin to change into bone, nerve, and muscle cells, and other types of body cells. (From Williams, Healthful Living, published by The Macmillan Company.)

2. Arrange on slide under the microscope fertilized frogs' eggs showing segmentation* (Fig. 37).

3. Demonstrate with charts† or models the folding off of tissues in the embryo.

4. Dissect a cat or dog and indicate the different body cavities, their contents, and boundaries.

5. Study a section of the body wall of the hog, as represented by a piece of bacon. The "rind" corresponds to the skin, the lean is the muscle of the body wall, fat is deposited between "rind" and muscle, and the inner lining of the wall.

* Frogs' eggs preserved in formalin solution may be secured from Marine Biological Laboratory, Woods Hole, Mass.

† Charts and models may be secured from Ward's Natural Science Establishment, Rochester, N. Y., the Central Scientific Supply Co., Chicago, Ill., Marine Biological Laboratory, Woods Hole, Mass., and Denoyer-Geppert Co., Chicago, Ill.

QUESTIONS

1. About what percentage of dry substance is added to the embryo in the last three months of intra-uterine life? Is the growth more rapid in the first three months or the last three months?
2. What is the daily addition of protein, fat, and ash to the embryo in the last three months? Where does the embryo secure this material? If the food of the parent is deficient in calcium oxid, does the embryo go without this material?
3. How early are fetal movements observed? Are fetal movements a sign of pregnancy?
4. Are there nerves or blood-vessels running directly from mother to embryo? In what way could chemical substances released by the mother reach the child?
5. Upon what does normal growth and development of the fetus depend?
6. What are chromosomes?
7. How valid is the belief in maternal impressions? Are markings of a newborn child due to terrifying experiences of the mother? What should be told expectant mothers concerning this question?
8. If one develops unusual skill in piano playing, will this power be transmitted to the child? Do children born of parents who have previously had a tonsillectomy have tonsils?
9. Are differentiation in structure and specialization in function associated?
10. What structure in the human embryo indicates a biologic relation between higher and lower vertebrates?

REFERENCES FOR FURTHER STUDY

1. Piersol, G. A.: Human Anatomy, J. B. Lippincott Co., Philadelphia, 1908, pp. 6–66.
2. Feldman, W. M.: Antenatal and Postnatal Child Physiology, Longmans, Green & Co., New York, 1920, pp. 111–113.
3. Jordan, N. H.: Principles of Human Nutrition, The Macmillan Co., New York, 1912, pp. 260–266.
4. Wilson, E. B.: The Cell, The Macmillan Co., New York, 1911, Chapter V.
5. Feldman, W. M.: Ibid., Chapters IV, V, VI.
6. Adami, J. G.: Principles of Pathology, Lea & Febiger, Philadelphia, 1908, vol. i, pp. 140–178.

CHAPTER III

TISSUES

I. The Five Classes of Tissues.
II. Epithelial Tissues:
    1. Simple Squamous Epithelium.
    2. Simple Columnar Epithelium.
    3. Stratified Squamous Epithelium.
    4. Stratified Columnar Epithelium.
    5. Modified Epithelium.
III. The Function of Epithelium.
IV. Connective Tissue:
    1. White Fibrous Tissue.
    2. Yellow Fibrous Tissue.
    3. Areolar Tissue.
    4. Adipose Tissue.
    5. Reticular Tissue.
    6. Cartilaginous Tissue.
    7. Bone Tissue.
    8. Neuroglia.
    9. Wharton's Jelly and the Vitreous Humor.
V. The Function of Connective Tissue.
VI. Muscular Tissue:
    1. Smooth Muscle.
    2. Cardiac Muscle.
    3. Striated Muscle.
VII. Function of Muscular Tissue.
VIII. Vascular Tissue.
IX. Function of the Blood:
    Coagulation of Blood.
X. Nervous Tissue:
    Endings of Neurons.
XI. Functions of Nervous Tissue.
XII. The Role of Tissues in Repair of Injury.

The Five Classes of Tissues.—The tissues[1] of the body are classified* in five groups: epithelial, connective, muscular, vascular, and nervous.

Epithelial Tissues.—This tissue forms the covering of the body, the secreting portion of glands, the channels of various

* Classification of tissues on the basis of their origin is not attempted because identical tissue structures arise from different layers of the developing embryo.

ducts and tubes, and the lining of the respiratory and digestive tracts. The cells of this tissue are derived from the ectoderm and entoderm. The mesoderm contributes to the formation of connective and muscular tissues. However, certain cells of mesodermic origin line the walls of the heart chambers, the lymph- and blood-vessels. To them the name *endothelia* is applied. Likewise, the covering of serous surfaces, as the lining of the pericardial, pleural, and peritoneal cavities, are of mesodermic origin. To them the name *mesothelia* is applied. These facts relate to their origin. In structure, however, they have many of the characteristics of epithelia, and hence are generally described in connection with them.

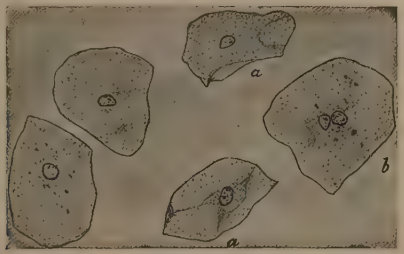

Fig. 38.—Isolated cells of squamous epithelium (surface cells of the stratified squamous epithelium lining the mouth): *a*, *a*, Cells presenting under surface; *b*, cell with two nuclei. (Böhm, Davidoff, and Huber.)

The following classification of epithelial tissue, based on form, is clear, simple, and satisfactory for the purposes of this study:

1. Simple epithelium consisting of one layer of cells has two subdivisions: (*a*) squamous, (*b*) columnar.

2. Stratified epithelium consisting of more than one layer of cells has also two divisions: (*a*) squamous, (*b*) columnar.

3. Modified epithelium may be simple or stratified. The distinguishing characteristic is its departure from the type as represented by the presence of cilia on the free margin of the cells, pigment, or unusual form, as observed in goblet-cells, glandular, and neuro-epithelium.

Simple Squamous Epithelium.—The cells in this form of epithelium (Fig. 38) are flat, scale-like bodies fitting together like the parts of a parquet floor. This type forms very smooth surfaces. It occurs quite infrequently in the human body. It is

found in the alveoli of the lungs, in the posterior surface of the anterior capsule of the crystalline lens, and in the membranous labyrinth of the inner ear.

Endothelium.—The lining of the heart, for which the special term *endocardium* is employed, is composed of a single layer of flat cells. The blood- and lymph-vessels are lined also by endothelium. The rôle of these flat cells is well illustrated in the capillaries—thin, smooth tubes composed of a single layer of cells. In synovial membranes of joints the deeper cells are similar to connective tissue indicating the origin of the membrane, but the flat cells of the joint surface are like endothelium. Hence these types are described under the epithelia.

Mesothelium.—The serous cavities, like the heart, vessels, and joints, are lined by cells derived from the mesoderm, and like them, also, they resemble the flat cells of squamous epithelium.

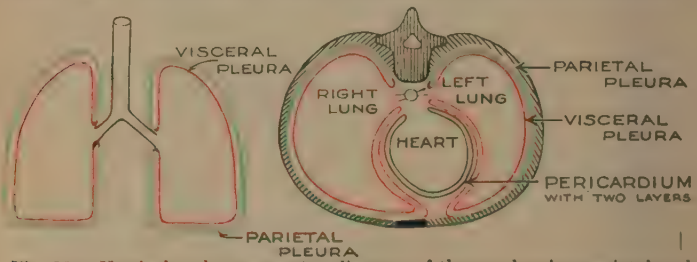

Fig. 39.—Vertical and cross-section diagram of thorax showing parietal and visceral pleura.

Thus from the endothelia and the mesothelia the synovial and serous membranes may be described as types under simple, squamous epithelium:

1. Serous membranes are composed of simple, squamous epithelium and connective-tissue cells acting as a base or foundation. The epithelial-like cells present smooth, glistening linings for the cavities of the trunk. In the thorax this membrane is called the *pleura* and *pericardium*, and in the abdomen and pelvis, the *peritoneum*. The combination of loosely arranged connective-tissue cells with the mesothelium forms these characteristic membranes. Thus, pleura is mesothelium plus connective-tissue cells lining the thoracic cavity; pericardium is mesothelium plus connective-tissue cells lining the fibrous pericardium; and peritoneum is mesothelium plus connective-tissue cells lining the lower

trunk cavity. That portion of the membrane covering an organ or viscus is called the *visceral layer;* the covering of the wall of the cavity is designated the *parietal layer* (Fig. 39). Hence, there is to be distinguished parietal pleural, visceral peritoneum, etc.

2. Synovial membranes form smooth, glistening, lubricating surfaces for joints, tendon sheaths (Fig. 40), and bursæ. For

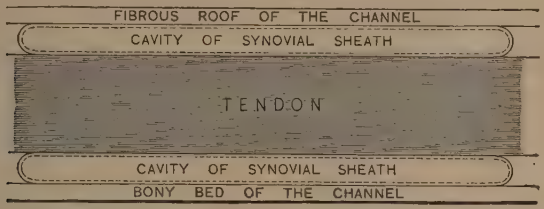

Fig. 40.—Diagram of a vaginal synovial membrane in longitudinal section (F. H. G.).

these three classes they are known as *articular*, *vaginal*, or *bursal synovial membranes.*

Simple columnar epithelium presents elongated cells (Fig. 41). The nuclei are placed in the deeper part of the cell. This type of epithelium forms the lining layer for a large part of another type of membrane in the body, the *mucous membrane.** Mucous mem-

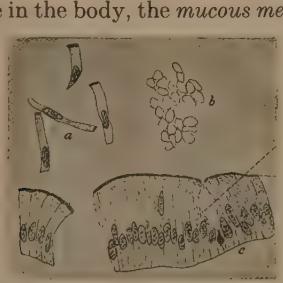

Fig. 41.—Simple columnar epithelium from the small intestine of man: *a*, Isolated cells; *b*, surface view; *c*, longitudinal section. (Böhm, Davidoff, and Huber.)

branes show other types of epithelia, but the prominence of this form suggests its description at this point.

* One general distinction between serous and synovial membranes and mucous membranes may be made. The two former ones line closed cavities; the latter lines cavities communicating with the outside of the body.

Mucous membranes: This type of membrane lines the digestive, pulmonary, and genito-urinary tracts. In the upper part of

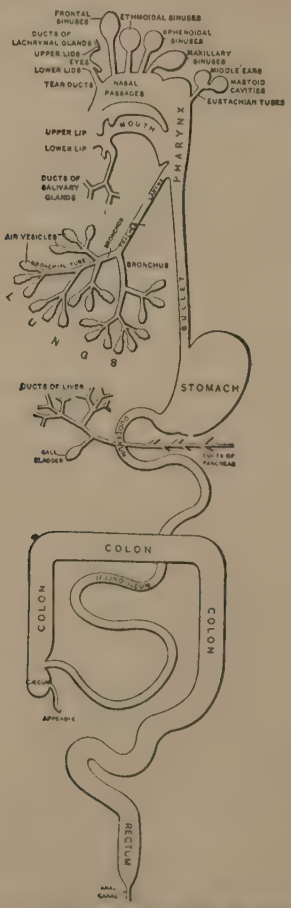

Fig. 42.— Diagram showing the continuity of the mucous membranes (from Gerrish, Text-book of Anatomy, Lea & Febiger, publishers).

the digestive tract the epithelium is a stratified squamous type, in the stomach and intestine it is simple columnar, in the respira-

tory tract it is ciliated, and in the genito-urinary it shows a number of forms. Whatever the variety of epithelium exhibited, the mucous membrane usually consists of four layers of tissue as follows:

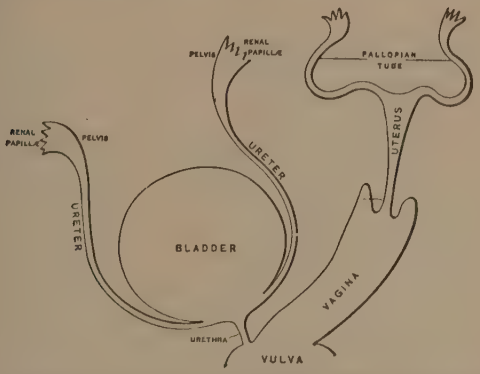

Fig. 43.—Diagram showing the continuity of the mucous membrane of the genito-urinary tract in the female (from Gerrish, Text-book of Anatomy, Lea & Febiger, publishers).

1. Epithelium: This is the surface layer, the cells secrete mucus.

2. Basement membrane: This is a layer of flat cells on which the epithelium rests.

Fig. 44.—Cross-section of stratified ciliated columnar epithelium from the trachea of a rabbit (Böhm, Davidoff, and Huber).

3. Corium: This is a layer of areolar tissue containing blood-vessels and frequently lymphoid cells.

4. Muscularis mucosæ: This is a thin layer of smooth muscle. It marks the boundary line between mucous membrane and the other coats of the tract.

The continuity of the mucous membranes of the respiratory and digestive tracts is shown in Fig. 42, and that of the genital and urinary tracts in the female in Fig. 43.

Stratified Squamous Epithelium.—In this form the cells are arranged in more than one layer. The surface cells are always very flat, but beneath there is a gradual transition to cells that are cuboidal in shape or even columnar (see Fig. 7).

Stratified columnar epithelium shows the surface cells columnar, but the deeper cells are often cuboidal (Fig. 44).

Fig. 45.—Cross-section of negro's skin, showing the intimate relationship of the pigment cells of the corium to the basilar cells of the epidermis. The latter are more deeply pigmented at their outer ends. The pigment granules may be traced into the outermost layers of the stratum corneum; × 525. (Böhm, Davidoff, and Huber.)

Modified Epithelium.—The above types may be modified in different ways:

1. Ciliated epithelium exhibits fine hair-like processes attached to the free surface of the cells (Fig. 44). Cilia are capable of movement that has a wave-like character. Cilia are present in the simple columnar epithelium of the smaller bronchi, uterus, fallopian tubes, and central canal of the spinal cord, and in stratified columnar epithelium of the large bronchi, trachea, larynx, nose, eustachian tube, vas deferens, and epididymis.

2. Goblet epithelium (Figs. 41, 44) appears in large numbers in the lining of the small and large intestine and the respiratory mucous membrane.

3. Pigmented epithelium occurs in the retina of the human eye and in the epidermis of the skin of dark races (Fig. 45).

4. Neuro-epithelium is observed in connection with the end organs of sensory nerves (Fig. 46). The different cells of the organs of Corti in the ear, the retina and the taste-buds are examples of neuro-epithelium.

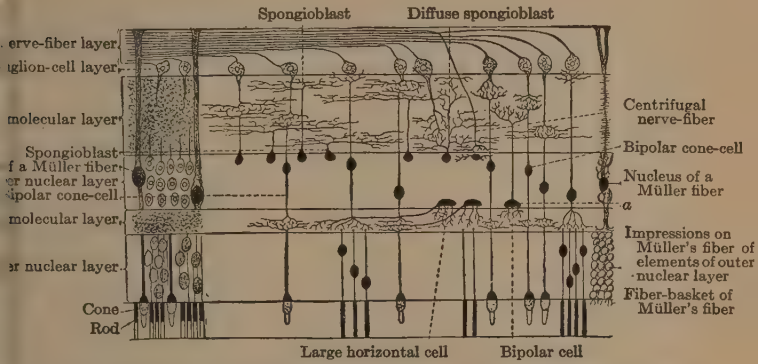

Fig. 46.—Schematic diagram of the retina according to Ramón y Cajal: The line *a*, after passing through a Müller fiber, crosses a bipolar rod-cell, then two bipolar cone-cells, and finally ends in the body of a bipolar cone-cell. (Böhm, Davidoff, and Huber.)

5. Glandular epithelium comprises the structural elements of glands. Usually they are of a simple cylindric type and, typically, grouped around the extremity of a duct. A collection

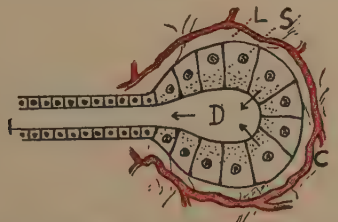

Fig. 47.—Diagrammatic representation of an acinus: *D*, Duct; *S*, secretory cells; *L*, lymph space; *C*, blood capillaries. (Burton-Opitz.)

of cells arranged in this way is called an *acinus* (Fig. 47). Glands are classed often according to the way in which the ducts divide (Fig. 48), but the significant part of a gland is not the duct, but the acinus. In Fig. 49 the acini of a salivary gland are shown.

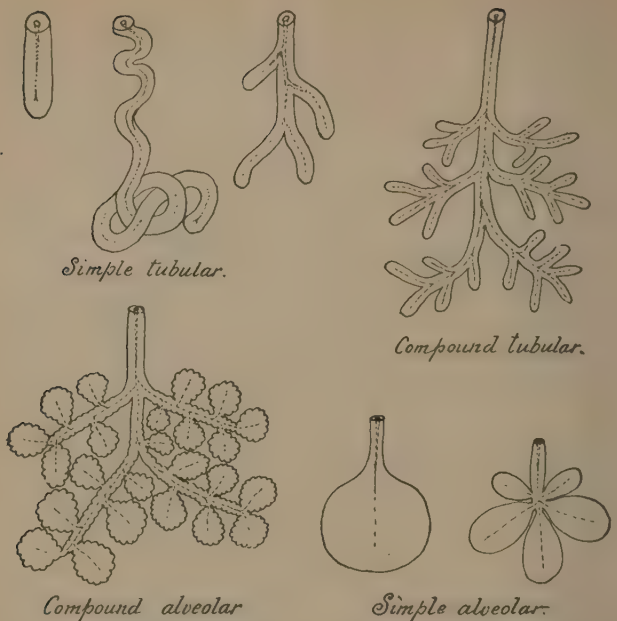

Fig. 48.—Diagram of different forms of glands (Hill.)

Fig. 49.—Section from parotid gland of man (Böhm, Davidoff, and Huber).

The **function of epithelium** may be considered under four divisions:

1. To give a protective covering, as in the skin.

2. To form smooth passageways, as in the blood-vessels, heart, and lymphatics.

3. To form smooth secreting surfaces, as in the pleura, pericardium, peritoneum, and mucous and synovial membranes.

4. To form the simple glands of the mucous membranes and the skin, and the more highly specialized structures, in which the epithelial elements are arranged in acini giving their secretion into ducts, or, as in the case of the internal secretions, directly into the blood. The secretions concerned with nutrition and par-

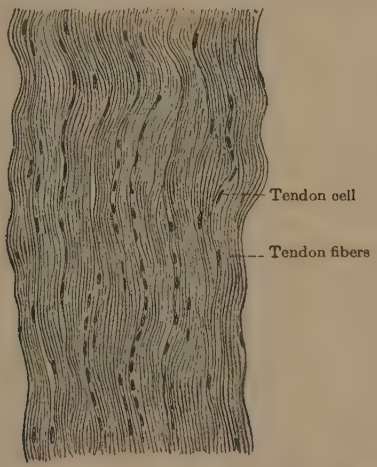

Fig. 50.—Longitudinal section of tendon; × 270. (Böhm, Davidoff, and Huber.)

ticularly with digestion of food come from the salivary, gastric, intestinal, pancreatic glands, and from the liver. These secretions are able to change food-stuffs due to *ferments* or *enzymes* produced by the cells. These ferments have special properties: they act best at body temperature; they are not destroyed or used up in the processes they initiate; they act in very small quantities; they are specific, *i. e.*, a fat ferment will not act on sugar; and finally, they exist in the cell not as the active agent, but in a dormant state requiring some other substance to make them active. This provision protects the epithelial cells from a disintegrating action that would otherwise result.

Connective Tissue.—Tissues of this group serve a supporting and binding function in the body. They comprise the bones, ligaments, tendons, and the supporting parts of all the organs. They show a great diversity in shape, the nuclei are small, and they tend to collect deposits within their cellular envelope. They may be classified in seven groups:



Fig. 51.—Schematic diagram given to show the development of the different types of connective tissue from the mesenchyma: *a*, Mesenchymal cells, certain of which are separate, others are joined by protoplasmic branches; *b*, syncytium with large strands of protoplasm and relatively few nuclei; *c*, reticular tissue the dark fibers are elastic fibers; *d*, white fibrous tissue; *e*, cartilage; *f*, membranous bone. (Bohm, Davidoff, and Huber.)

White fibrous tissue forms a very large part of the supporting framework of the body, acting purely a passive rôle. It is non-

elastic and very strong. Ligaments, tendons, and aponeuroses are built of this material. The intercellular material is large and consists of closely packed fibers of great tensile strength. Between the fibers are rows of flattened cells (Fig. 50). Some fibers of the next division are often found mixed with the white fibrous tissue.

Yellow fibrous tissue appears as wavy bands (Fig. 51) and usually is associated with white fibrous tissue. If they exceed the latter in amount then the tissue is classed as yellow fibrous. This tissue is not so strong as the white, but it is elastic, a quality that renders it extremely valuable in the parts where it is found, especially in the blood-vessels and lungs.

Areolar tissue is composed of a mixture of white and yellow fibers very loosely bound together (Fig. 51). It is found filling the spaces between other tissues, chiefly between blood-vessels and nerves, under mucous membranes, and composing the subcutaneous layer of the skin, where it is called *fascia*.

Adipose tissue is areolar tissue with the cells filled with fat globules. Seen under the microscope the fat is observed to be

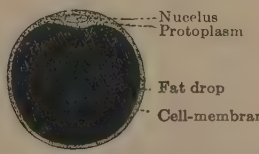

Fig. 52.—Scheme of a fat cell (Böhm, Davidoff, and Huber).

deposited within the cell body (Fig. 52) of the connective-tissue cells. When fat occurs in compact tissues, such as the heart, liver, or kidneys, there must first occur degeneration of the cells forming the part, hence the term "fatty degeneration." Adipose tissue accumulates chiefly under the skin, in the mesentery, around viscera, *e. g.*, the kidneys, between blood-vessels and nerves, and under mucous membranes.

Reticular tissue is very much like areolar in its loose arrangement, but it differs in exhibiting a network or reticulum. It is observed chiefly in lymph-nodes (Fig. 53), although it may be found in other parts, *e. g.*, mucous membranes and glands. In the spleen its relation to the formation of phagocytes is very important.

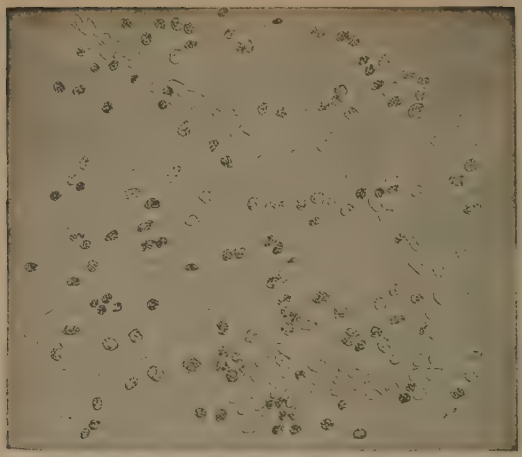

Fig. 53.—Reticular connective tissue from lymph-gland of man; × 280. Brush preparation. (Böhm, Davidoff, and Huber.)

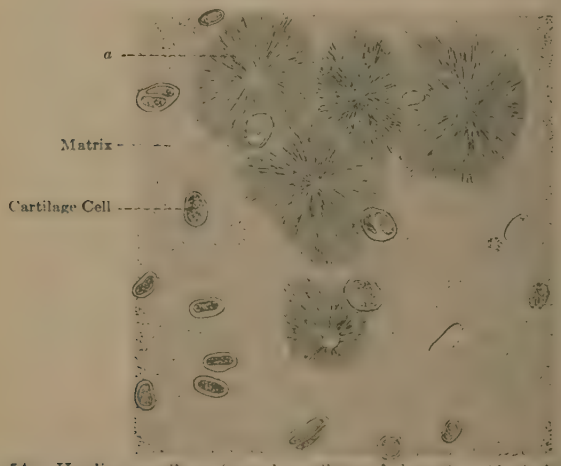

Fig. 54.—Hyaline cartilage (costal cartilage of the ox). Alcohol preparation; × 300. The cells are seen inclosed in their capsules. In the figure *a* represents frequent but by no means characteristic radiate structures. (Böhm, Davidoff, and Huber.)

Cartilaginous tissue is quite commonly recognized by the layman as "gristle," a tough firm substance. It is composed of cells lying in pairs or multiples (Fig. 54) in a field of intercellular substance called the *matrix*. In some cases the matrix is homogene-



Fig. 55.—Insertion of the ligamentum teres into the head of the femur. Longitudinal section; × 650. (Böhm, Davidoff, and Huber.)

ous, in others it contains fibers. There are three classes of cartilage, grouped according to the matrix:

1. Hyaline cartilage forms the articular surfaces of bones, the rib cartilages, the rings of the trachea, the bronchi, and the

nose. In the embryo the entire skeleton is laid down in hyaline cartilage. The matrix is homogeneous.

2. White fibrocartilage occurs in the intervertebral disks, symphyses, and in certain joints. The matrix contains a large amount of white fibrous tissue (Fig. 55).

3. Yellow fibrous or elastic cartilage occurs in the cartilages of the ear, epiglottis, parts of the larynx, and eustachian tube. The matrix contains a large amount of yellow fibrous tissue (Fig. 56).

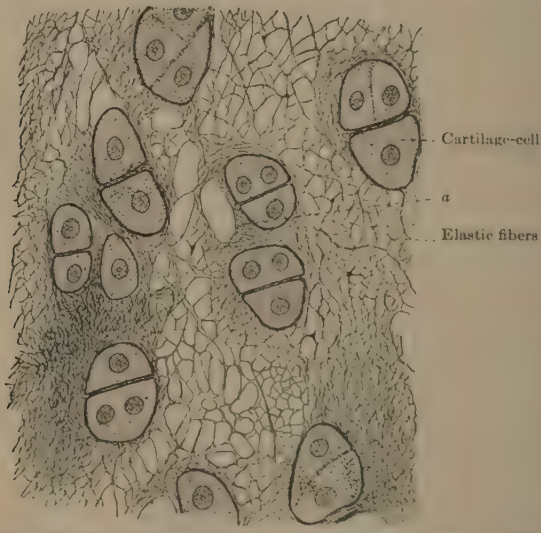

Fig. 56.—Elastic cartilage from the external ear of man; × 760: *a*, Fine elastic network in the immediate neighborhood of a capsule. (Bohm, Davidoff, and Huber.)

Except where it forms articular surfaces, cartilage is covered by a tough, fibrous membrane, the *perichondrium*. All three types are elastic because cartilage itself is elastic, but the yellow fibrous variety is more extensile than the others because of the preponderance of yellow elastic fibers.

Bone tissue is essentially connective tissue with which are combined inorganic compounds, chiefly the phosphate and carbonate of calcium. Hardness of this tissue is due to the deposit of inorganic materials during the process of ossification. This

process would result in great increase in weight except for the fact that there occurs a cavity within the shaft of the bone, called the marrow cavity, and the ends of the bones develop a number of spaces giving rise to what is known as spongy bone, as distinguished from the compact bone of the shaft. Within the marrow cavity is a fatty material called *marrow*, containing blood and blood-cells in large numbers. The marrow of bone serves as a blood-forming organ and is conspicuous in this activity during

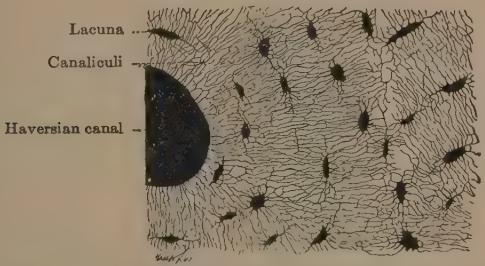

Fig. 57.—Portion of a transversely ground disk from the shaft of a human femur; × 400 (Böhm, Davidoff, and Huber).

periods of blood regeneration. For a description of the way in which bone tissue is formed see Chapter IV.

Bone tissue, like cartilage, has a distinct cellular element and a definite intercellular substance. The bone-cells lie in spaces called *lacunæ* (Fig. 57) in the intercellular substance. The lacunæ have branching canals which connect with other lacunæ and at the surface of the bone open into vessels of the *periosteum*, the membrane covering bone. This system of canals provides a circulatory tract by means of which nourishment may reach the deeper parts of the bone.

The surface of the bone is covered with an investment of white fibrous tissue called *periosteum*, which is essential to the proper nourishment of bone. Portions of dead or diseased bone may be removed by the surgeon, and if the periosteum is intact, regeneration of the part will take place.

The *dentin* and *enamel* of teeth are very hard, are closely allied to bone, and therefore may be discussed in this connection. The dentin shows minute canals, called *dentinal tubules*, which radiate from the pulp cavity. Along the margin of the pulp cavity are

cells, called *odontoblasts* (Fig. 58), which connect with the tubule. The enamel is arranged in columns or prisms and covers the exposed part of the tooth. Enamel contains very little organic material (3 to 5 per cent.) and, hence, is very hard.

Neurologia is the connective tissue of the spinal cord and brain, and forms the framework of these structures. It consists of con-

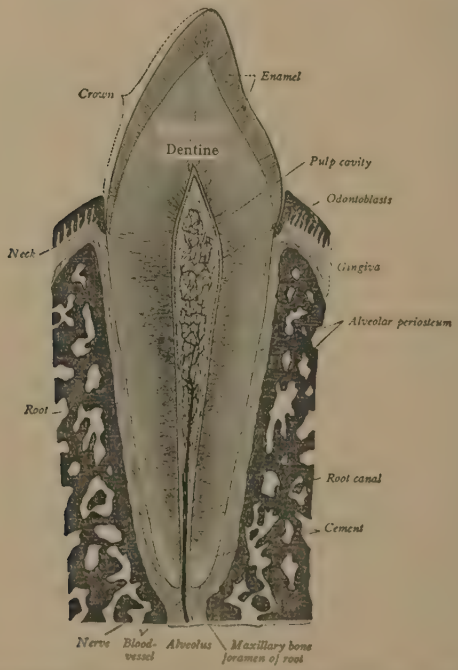

Fig. 58.—Longitudinal section of a tooth in its alveolus (diagrammatic) (Sobotta and McMurrich).

nective-tissue-like cells, called glia cells (Fig. 59). It, like the teeth, is derived from ectoderm, although other connective tissues come from mesoderm.

Wharton's jelly and the *vitreous humor* are two tissues that are of connective-tissue character, although very distinctive and very much restricted in their distribution. The former is present

in the umbilical cord of the infant and the latter in the posterior cavity of the eye.

The Function of Connective Tissue.—In general, it has been stated that the function of connective tissue was a binding and supporting one. The particular application of this function in the different varieties of connective tissue is given as follows:

Fig. 59.—Neuroglia cells: *a*, From spinal cord of embryo cat; *b*, from brain of adult cat; stained in chrome-silver. (Böhm, Davidoff, and Huber.)

White fibrous tissue functions as the chief constituent of:

1. Ligaments which, as strong inelastic bands, hold the ends of bones together, forming joints.

2. Tendons which, as very strong, inelastic yet flexible cords, attach muscles to bone.

3. Aponeuroses which, as broad sheets, anchor muscles together or muscles to bone.

4. Capsules or protecting sacs, which form a firm covering over organs, *e. g.*, the capsule of the kidney and part of the pericardium of the heart are composed of white fibrous tissue.

Yellow fibrous tissue functions as the chief constituent of certain ligaments where extensibility is desired, as in certain ligaments of the spine, *e. g.*, the ligamentum subflavum. It is found also in the walls of blood-vessels, particularly the arteries, and in the walls of the lungs, providing for the elastic recoil of these organs.

Areolar tissue functions as a *fascia* or protecting and connecting bandage in two main categories:

1. Fascia of the skin under which it forms a loose supporting groundwork allowing freedom of movement. The cutaneous fascia is commonly known as superficial fascia.

Superficial fascia contains both white and yellow fibers. It is very loose, shows numerous spaces connecting with one another, and frequently contains large amounts of fat. The looseness of

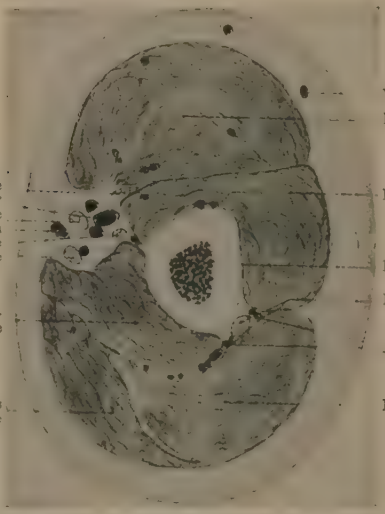

Fig. 60.—A cross-section through the middle of the arm, showing deep fascia continuous with superficial fascia (after Schultze and Stewart).

this structure accounts for the ease with which fluid from the blood-vessels collects in this tissue in *edema*, and the connecting channels accounts for the fact that such fluid following the laws of gravity accumulates in pendant parts of the body. Infection in superficial fascia spreads readily and rapidly, hence the seriousness of *cellulitis*, a name based upon a term formerly applied to areolar tissue (cellular tissue).

2. Fascia of organs is more organized than the superficial fascia and forms a firm partition for organs. It is commonly known as deep fascia.

Deep fascia is continuous with the superficial fascia and assumes a denser and firmer character, at times taking on the character of white fibrous tissue. It covers muscles and sends thin shafts of partitions in between the muscle bundles. The continuity of the fibrous tissues is well illustrated in this connection (Fig. 60). Superficial and deep fascia blend with each other and send their prolongations to bone, ligaments, tendons, and the capsules investing organs. The fascia of organs is not constricted to the muscles only. It is observed as an important part of the groundwork around which the epithelial elements are constructed.

Adipose tissue serves chiefly as packing material filling in the interstices between parts and forming a soft bed in which delicate structures, such as nerves and blood-vessels, run. Incidentally adipose tissue in the superficial fascia gives protection against cold and a certain roundness to the body that may be attractive.

Reticular tissue forms a network for lymph-nodes and similar organs, such as the spleen and thymus. It is also seen as the groundwork in parts of other organs, such as the adrenals, and quite constantly in glands and mucous membranes.

Cartilaginous tissue functions as an intermediate structure between the less rigid connective tissues and the unyielding bones of the body. It is found, therefore, in those parts where permanence of form is desired without rigidity, and hence is a constant constituent at the ends of bones. Illustrations of this useful service are the cartilages of the ribs, the *costal cartilages;* of joints, the *articular cartilages;* of the nose, the *nasal cartilages;* and the cartilaginous rings of the trachea and bronchi.

By the addition of white fibers to cartilage a firmer tissue is produced, and this type is seen in the *intervertebral disks* between the bodies of the vertebræ. Adding some elastic fibers provides an elastic cartilage, such as those of the ear, larynx, epiglottis, and eustachian tube.

Bone tissue functions as support for the body, and in certain areas, such as the spine and cranium, it gives protection to the nervous system. The protective function is exhibited in spine and cranium.

Muscular Tissue.—The property of contractility is characteristic of all protoplasm, but in muscle tissue it reaches its highest development. This power to contract, possessed by all muscle cells, is due to contractile fibers in the cytoplasm of the cell. The

structure and arrangement of fibers group muscle tissue into three classes:

1. Smooth muscle (involuntary).
2. Cardiac muscle (involuntary and striated).
3. Striated muscle (voluntary).

Smooth muscle is found mainly in the walls of viscera, the bladder, skin, fallopian tubes, the arteries, and veins. The cell of this tissue varies from 30 to 200 micra* in length, from 3 to 8 micra in width (see Fig. 9). It is called involuntary at times because its contractions are not under the control of the will, and smooth because it has no striations.

Cardiac muscle is the muscle tissue of the heart and resembles both the smooth and the striated. It has cells with cross-striations like the latter, and is not under the control of the will like the former (see Fig. 11).

Striated muscle comprises the skeletal muscles of the body. This tissue is grouped in masses having definite names. They vary in shape and size as muscles, although they are all composed of the same type of cell. The individual cells are like cylinders within which are many fine threads arranged longitudinally, called *fibrils*. The fibrils show alternate dark and light bands, forming the cross-striations. The cell is invested with a connective-tissue covering called the *sarcolemma*† (see Fig. 10).

Function of Muscular Tissue.—The contraction of muscle tissue in the body is dependent upon a stimulus from the nerve going to the muscle. This contraction may be modified by various factors, for example, the substances in the blood, but the initiative in the case of the smooth and skeletal muscles must come from the nervous system. The heart muscle possesses within itself the power to initiate contraction, but even here the rate and frequency are controlled by the action of nerves. The muscle and its nerve may be thought of as the unit of movement structurally and functionally because loss of the nerve connection gives rise to paralysis. When the nerve actually innervating the muscle is damaged or destroyed, atrophy of the muscle results. Atrophy does not occur in a paralysis of voluntary

* 1 micron = 1/1000 millimeter.

† The sarcolemma is tough and fibrous. In giving meat to children or sick persons a "scraped-beef sandwich" is often employed. The beef is prepared by scraping the protoplasm of the muscle-cell free from the investing sarcolemma.

movement, but only when the neuron actually innervating the muscle is damaged or destroyed.

Normally in the body the nerves are sending to the muscles a series of stimuli that keep the muscles in a partial state of contraction called *tonus*.[2] This condition is observed in the blood-vessels as reflected in the varying state of blood-pressure, in the muscles of the face as indicated by the firmness or sagging of the skin, in the muscles of the trunk and feet, particularly as represented by the relaxation of the abdominal muscles or as indicated by trouble with the arches. Muscular tonus represents a state of readiness of the muscle to act. It is decreased by fatigue and other debilitating conditions.

A contracting muscle acts by pulling its ends toward each other. A muscle never pushes, although the pulling action of muscles applied to bones may accomplish what is recognized as pushing. The power of pull of a muscle is modified by the strength of the stimulus sent over the nerve, by the conditions of warmth or cold affecting the part, and by the nutrition of the muscle itself. After activity a muscle loses its power to contract effectively due to the presence of some of the end-products of the chemical processes developed during contraction. Fatigue of muscle is, therefore, due to fatigue products, the chief of which is sarcolactic acid. Soreness and stiffness following an unusual activity is often due to little tears in the muscle cells with an accompanying damage to the endings of nerves.

The nutrition of muscle is dependent upon activity of the muscle (use causes hypertrophy, disuse causes atrophy of muscle) and the circulation to the part. Hence in instances of paralysis of muscle the nutrition of the muscle may be kept up by massage and passive movements, and the prevention of atrophy by electric stimulation until such time as the nerve will be restored.[3]

Vascular Tissue.—The blood and lymph are considered as tissues, although their elements are not fixed and remain as isolated units in a fluid medium. The cells may be considered as the structural parts moving about in an intercellular material, the fluid portion of the blood. The formed elements of the blood are:

1. Red blood-cells (erythrocytes) are disk-like, without nuclei, homogeneous in structure, extremely soft and elastic, easily accommodating themselves to the smallest vessel (Fig. 61). They number about 5,000,000 per cubic millimeter. They

contain an important iron-protein compound, called *hemoglobin* composed of hematin and globulin.

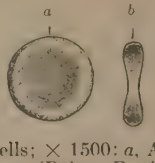

Fig. 61.—Human red blood-cells; × 1500: *a*, As seen from the surface; *b*, as seen from the edge. (Böhm, Davidoff, and Huber.)

2. White blood-cells (Fig. 12) are colorless, nucleated structures extremely variable in shape and number. An average

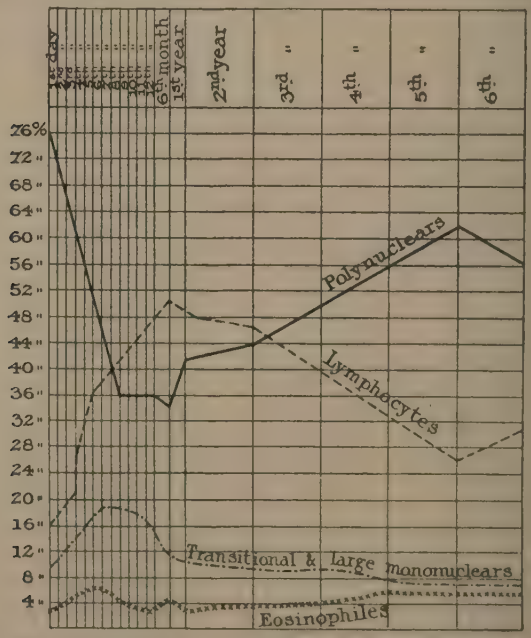

Fig. 62.—Chart showing the percentages of the various leukocytes from birth to six years of age (after Carstanjen and Roteh).

count for the normal adult gives between 7000 and 9000 per cubic millimeter.

At birth there are more white cells than during normal adult life. The first day shows nearly 20,000 and continues at 9000 to 13,000 during the first two years. This variability in the

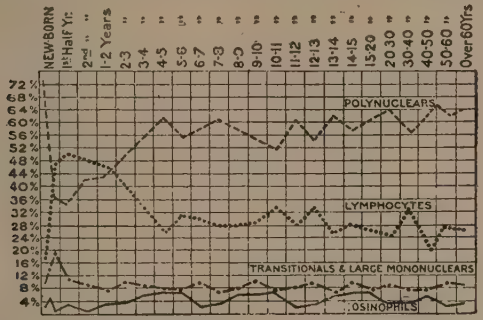

Fig. 63.—Chart showing the percentages of the various leukocytes from birth to old age (Hutchison's "Lectures on Diseases of Children," Edward Arnold).

ormation of the red and white cells during the first years of life is ndicated in Figs. 62–65.

The white blood-cells are of several varieties, and may be classi- ied as follows:

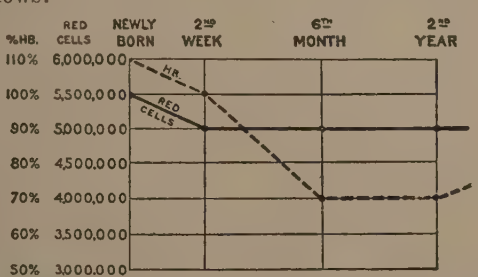

Fig. 64.—Chart showing the variations in the percentage of hemoglobin nd erythrocytes from birth and two years of age (Hutchison's, "Lectures n Diseases of Children," Edward Arnold).

(*a*) Lymphocytes about the same size as the red cells, with rge spheric nuclei filling almost the entire cell. Some are larger ee Fig. 12). They number about 20 per cent. of the white cells. n increase in number over the normal is called *lymphocytosis*.

(*b*) Mononuclear leukocytes comprise about 2 to 4 per cent. of the white cells. They resemble the large lymphocytes.

(*c*) Transtional leukocytes are about the same size as the large lymphocytes, with a nucleus that is horseshoe shaped (see Fig. 12), numbering about 2 to 4 per cent. of the white cells.

(*d*) Polymorphonuclear leukocytes comprise about 70 per cent. of the white cells. Their nucleus is irregular in shape, usually appearing in three lobulations, sometimes in four (see Fig. 12). The cytoplasm is granular and gives a characteristic staining reaction so that three types are recognized: *eosinophils*, which take an acid stain and show red granulations; *basophils* which take a basic stain and show blue granulations, and *neutro-*

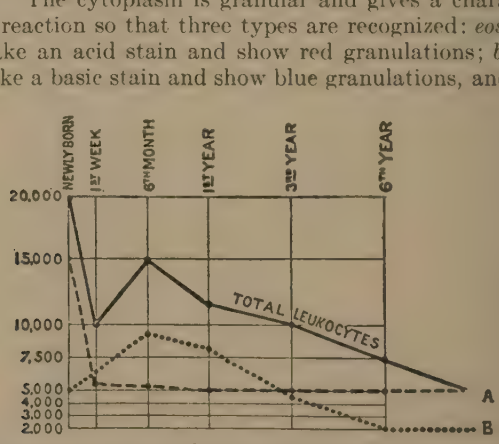

Fig. 65. Chart showing the leukocyte counts from birth to six years (Hutchison's "Lectures on Diseases of Children," Edward Arnold).

phils, whose granules respond to both acid and basic stains. An increase in number of leukocytes above normal is called *leukocytosis;* a decrease is known as *leukopenia.*

3. Platelets are minute round bodies numbering about 200,000 per cubic millimeter.

Function of the Blood.—The *red blood-cells* are concerned in the transportation of oxygen from the lungs to the tissues of the body. Oxygen combines with the hemoglobin of the red cells forming oxyhemoglobin. Reduction in the oxygen-carrying capacity of the blood either through diminution of the number of cells or through decrease in the amount of hemoglobin in each cell results in a condition called *anemia.* Causes of anemia are excessive loss of blood, toxins (poisons) in the circulating blood

either from old suppurating sores or from malignant growth. Parasites in the blood—*e. g.*, in malaria—or in the intestines—*e. g.*, certain worms—may cause anemia through destruction of the red cells. *Chlorosis* is a condition in which the hemoglobin is reduced in amount, the number of red cells being normal.

The *white cells* serve a protective function in the body. They possess the power "to surround and destroy foreign particles" in the circulation and tissues. This activity is called *phagocytosis* and the cells are known as *phagocytes* (Fig. 66). They are capable of ameboid movement, and hence may easily escape through the capillaries of the blood-stream and enter the tissue spaces. This ability to migrate from the confines of the vessel walls combined

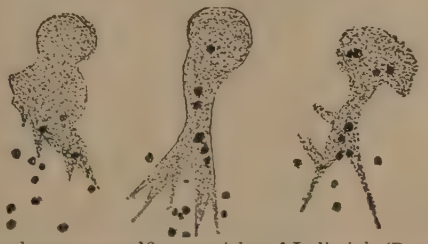

Fig. 66.—Leukocytes engulfing particles of India-ink (Burton-Opitz).

with the power to exert protective action as phagocytes render them especially useful in combating infections that occur in the body. An area of infection will show increased blood-supply to the part, accounting for the swelling, heat, and redness. The leukocytes are greatly increased in the area and engage in a battle with the bacteria present. The power of the leukocytes to attack and digest bacteria is conditioned by certain antibodies in the plasma, called *opsonins*. The opsonin content may be determined and is expressed as the *opsonic index*. In any case of infection many leukocytes are killed in the process; their dead bodies constitute in large part the *pus* that forms.

The leukocytes are concerned chiefly with phenomena of phagocytosis and are hence especially prominent during an infection. The lymphocytes may be increased in certain chronic diseases, but they are supposed to assist in other ways by absorbing fat globules and conveying them to lymphatic channels and by aiding in the absorption of peptones.

The *platelets* function chiefly in the clotting of blood, a phenomenon of great importance in the body. The time between the drawing of blood and its change to a clot is known as the *coagulation time*. This time varies, but for most persons is about five minutes. When the blood does not clot readily or at all the person is known as a *hemophiliac*, and the condition as *hemophilia*. This condition is observed only in males; females are free from the condition, but may transmit the malady.

Coagulation of Blood.—In normal blood there are all the essentials for clotting. According to one theory, the plasma, or fluid portion, contains *fibrinogen*, a protein substance, which is changed

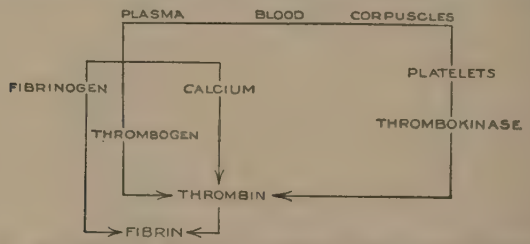

Fig. 67.—Schema of blood coagulation (after Burton-Opitz).

to *fibrin*, forming numerous thread-like processes that constitute the clot. This transformation of fluid fibrinogen into thread-like fibrin is brought about by the action of *thrombin* on the fibrinogen (Fig. 67). Thrombin does not exist as such in the blood, but occurs in an inactive form—*thrombogen*. The platelets yield an activating agent, *thrombokinase*, which in the presence of *calcium* has the power to change the thrombogen into thrombin; the thrombin, acting on the fibrinogen, gives fibrin. It would seem, therefore, that important factors in the process were the platelets. So long as the blood remains in the normal blood-vessel these fragile cells are unchanged, but injury to the blood-vessel causes, on the one hand, an extravasation of blood with clot formation, or in case the vessel is not severed, the clot may be produced within the vessel. Such intravascular clot is called a *thrombus* and may be due to injury of the vessel wall from a blow or from the toxins of bacteria with subsequent injury to the fragile platelets and liberation of thrombokinase. If a portion of a thrombus becomes separated and carried into other vessels it is known as an *embolus*.

In addition to the function of the cells and the coagulation power of the plasma, the fluid portion of the blood distributes food materials to the tissues,* transfers waste from body cells to eliminative organs, serves as a medium of circulation for internal secretions, and carries numerous protective substances formed in the body.

Coagulation Time.—The time between the withdrawal of blood and its formation into a clot is the *coagulation time.* This period

Fig. 68.—A portion of three striated muscle-fibers, moderately magnified, showing the capillary vessels (dark). (From Williams' "Healthful Living," published by The Macmillan Company.)

is fairly constant for man, but may be modified by various measures. High temperatures shorten and low temperatures lengthen this interval, hence to stop bleeding by causing a clot it is the practice to apply hot applications to the bleeding surface. Different animal extracts have been prepared that hasten the coagulation of blood, but commonly adrenalin is used in certain surgical procedures to cause constriction of the vessels, and hence stop the bleeding. In transfusion of blood it has been found helpful to use certain salts to prevent coagulation. Thus sodium

* Note the vascular distribution to muscle tissue in Fig. 68.

citrate in 2 per cent. solution is used in transfusion cases to prevent coagulation. It acts by combining with the calcium of the blood and removing one of the essential factors in coagulation.

In certain diseases the coagulation time is prolonged. This is noticeable in instances where bile gets into the blood, as in cirrhosis of the liver and in obstruction of the common bile-duct.

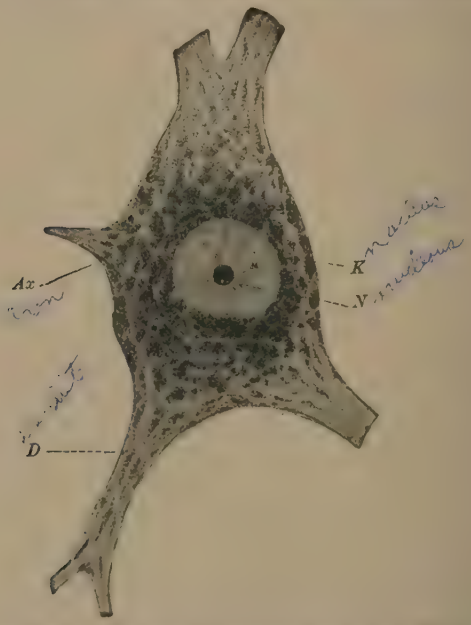

Fig. 69.—Cell from the anterior horn of the spinal cord of a rabbit, showing Nissl's bodies: *Ax*, Axon; *D*, dendrite; *K*, nucleus; *N*, nucleolus. (Klopsch.)

In operating on icteric patients it is customary to make a preliminary test of the coagulation time.

Nervous tissue forms the brain, spinal cord, peripheral nerves, ganglia, and plexuses. These parts are made up of nerve cells and their branching processes. A nerve cell and its processes are called a *neuron*, which may then be considered the structural unit of the nervous system (see Fig. 13). A neuron may be said to consist of cell body, dendrites, and axon.

The *cell* body (Fig. 69) resembles other protoplasmic units, but is more irregular. Within the cytoplasm are darkly staining masses, known as *Nissl bodies*, substances related to the physiologic state of the cell, for they decrease under certain conditions (Fig. 70).

The *dendrites* are branches of the cell body, concerned with carrying impulses toward the cell body.

Fig. 70.—Brain cells at rest, in action, exhausted (Crile). (From Williams' "Healthful Living," published by The Macmillan Company.)

The *axon* (see Fig. 13) is usually a long process of the cell that runs as a distinct branch, giving off an occasional lateral communication, called *collaterals*, and ending in a tuft-like process, the *terminal arborization or end brush*. The axon carries impulses from the cell body. Axons are divided into two groups—*medullated* and *non-medullated axons*.

The medullated axons are covered with a thick fatty sheath, composed of *myelin*. At intervals the sheath is marked by constrictions, forming the *nodes of Ranvier*. The outer covering of the sheath is the *neurilemma*.

The non-medullated axons are present in large numbers in the embryo, and in the adult they are found in both white and gray matter of the central nervous system. There is no neurilemma

in the cord or brain structures; this covering is present only in the peripheral nerves.

An axon with its covering constitutes a nerve-fiber.

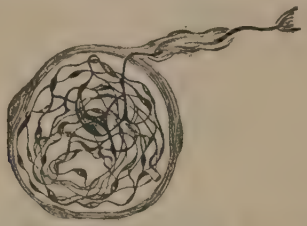

Fig. 71.—End-bulb of Krause (receptor) from conjunctiva of man; methylene-blue stain (Dogiel, "Arch. f. mik. Anat.," vol. xxxvii).

Endings of Neurons.—The endings of neurons are highly specialized for the purpose of receiving or delivering stimuli and impulses. The neurons that receive stimuli for transmission

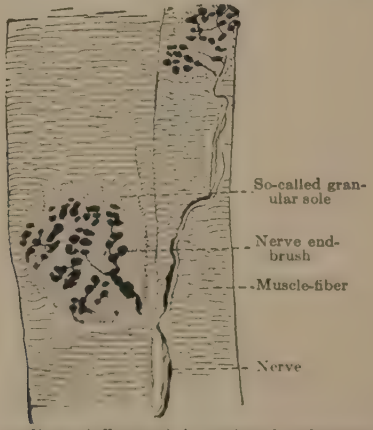

Fig. 72.—Motor endings (effectors) in striated voluntary muscles (Böhm, Davidoff, and Huber).

to the spinal cord and brain are called *afferent.* Their dendritic endings are known as *receptors* (Fig. 71). Neurons that carry impulses from the spinal cord and brain to muscles and glands are called *efferent.* Their terminal arborizations are known as *effectors* (Fig. 72).

Function of Nervous Tissue.—The embryonal type of cell possesses all the properties necessary for its undifferentiated existence. The specialization of function that accompanies that of structure reveals in nervous tissue irritability and conductivity developed to a high degree. The other properties so common to the unspecialized cell are greatly reduced. This fact indicates the primary function of nervous tissue, namely, to readily respond to stimuli (irritability) and to conduct impulses (conductivity).* These functions in an organism, such as an earthworm, are very simple; they become very complex in the mammals, and particularly so in man. They will be discussed more at length later.

PRACTICAL EXERCISES

1. From the butcher secure material to illustrate different tissues of the animal body.

2. Indicate parietal and visceral pleura in the animal used in demonstration of cavities and organs. (See page 54.)

3. Lay open a joint and note the smooth, glistening character of the synovial membrane. Is the vascular supply meager or abundant?

4. Secure a fresh oyster. Mount and examine under the microscope a piece of gill, using the salt water found in the shell for mounting purposes. Observe the movements of cilia. The mucous membrane of the mouth of a frog may be used to show cilia.

5. Observe paramecium and note the action of cilia (Fig. 73). (See page 33, Practical Exercises, 1.)

6. Study slides showing goblet epithelium and pigmented epithelium.

7. The action of an enzyme may be demonstrated as follows: Heat a teaspoonful of starch in a pint of water. The resulting starch paste is opalescent. Place an equal portion of thin starch paste in two test-tubes marked A and B. To tube A add 10 c.c. of saliva filtered through coarse filter-paper. Set aside for about forty minutes. Note the loss of opalescence in one tube. Add a few drops of iodin solution to tube B. Note color. Add iodin solution to tube A. The enzyme of the saliva has changed the starch to maltose.

8. Examine a slide of human blood stained with eosin-methylene-blue.† Note the cells: Red corpuscles are bright red, nuclei and bodies of the lymphocytes are blue, polymorphonuclear leukocytes show bright red granules in the eosinophils, and pink cytoplasm in the neutrophils. Examine an unstained slide of human blood mounted in normal salt solution (7 grams of common salt to 1 liter of water) and observe the red cells.

9. In making a count of the number of red blood-cells in a cubic millimeter a small quantity of blood is secured. This is then diluted and some is placed on a specially devised chamber, ruled to facilitate counting. The following steps are usually followed:

(*a*) *Obtaining the Blood.*—The finger is punctured with a sterile needle and a large drop of blood is allowed to collect. A pipet (Fig. 74) attached to

* Although not commonly classed as a function of nerve tissue, the power to correlate (correlation) response with reference to the nature of the impulse is strikingly characteristic.

† See Wood, F. C.: Chemical and Microscopical Diagnosis, D. Appleton & Co., New York, 1911, pp. 69–118.

a rubber tube is placed with its tip in the drop and blood is drawn by suction into the capillary tube as far as the mark 1.

Fig. 73.—Paramecium, a ciliated infusorium.

(*b*) *Diluting the Blood.*—Immediately after the pipet is filled to the mark desired the tip is wiped off and the diluting fluid (Hayem's solution is com-

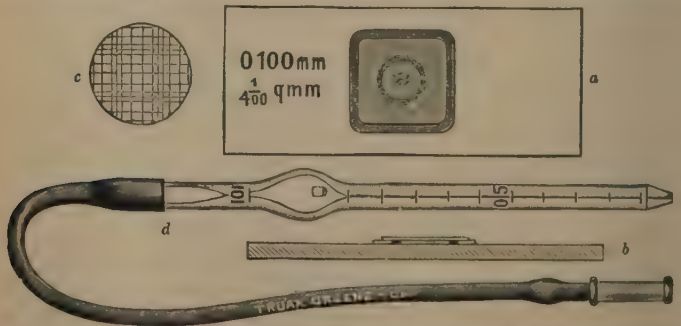

Fig. 74.—Thoma-Zeiss hemocytometer: *a*, Slide used in counting; *b*, sectional view; *c*, a portion of ruled bottom of the well; *d*, pipet.

monly employed) is drawn into the pipet to the mark 101. With the finger on the tip, the pipet is shaken to evenly distribute the cells.

(*c*) *Filling the Counting Chamber.*—The counting chamber is a slide to hich has been cemented two glass plates (Fig. 74). The central circular late holds the drop of blood to be examined. It contains a ruled area 1 illimeter square, divided into 400 small squares, each being then 1/400 quare millimeter. Heavy lines group these small squares into groups of 25, that four large squares would contain 100 small squares. A cover-glass ts over the larger and outer glass, and rests exactly 1/10 millimeter above ie ruled disk. Therefore the blood-cells present in any one of the 400 small quares represent the count of the diluted blood in 1/4000 cubic millimeter. he count is made by means of a microscope.

(*d*) *Counting the Cells.*—Usually 100 small squares are counted. If cells re on boundary lines of the large squares they are counted in the square to ie right and below. Suppose that 4 large squares or 100 small squares yield 205 cells. The average per small square would be 12.05. This represents ie cells in $\frac{1}{4000}$ cubic millimeter, and hence a cubic millimeter would ave 48,200 cells. The dilution in the pipet was 100. Then the undiluted ood with this calculation would have 4,820,000 cells per cubic millimeter. fterward the pipet must be thoroughly cleaned.

QUESTIONS

1. Name epithelial structures derived from ectoderm, mesoderm, and ntoderm.
2. Name the four coats of mucous membrane.
3. What is an acinus?
4. Do ligaments stretch?
5. What is meant by the term "fatty degeneration of the heart"?
6. Distinguish between periosteum and perichondrium.
7. Why is cellulitis a serious form of infection?
8. How does bone regenerate itself? What is callus of bone? How is it rmed?
9. Describe coagulation. What is the coagulation time? What is an mbolus?
10. What is the meaning of the terms "hypertrophy" and "atrophy"? se the terms in a sentence referring to some animal, organ or part.

REFERENCES FOR FURTHER STUDY

1. Böhm, Davidoff, and Huber: A Text-book of Histology, W. B. Saunders o., Philadelphia, 1920. The entire text is valuable for reference.
2. Burton-Opitz, R.: An Elementary Manual of Physiology, W. B. unders Co., Philadelphia, 1928, pp. 63–110; 119–130.
3. Stookey, B.: Surgical and Mechanical Treatment of Peripheral Nerves, . B. Saunders Co., Philadelphia, 1922, chapter on Nerve Degeneration and egeneration.

CHAPTER IV

THE SKELETON

I. The Nature of the Human Skeleton.
II. Origin of the Skeleton.
Formation of Intramembranous Bone.
Formation of Endochondral Bone
III. Growth of Bone.
IV. General Characteristics of Bone.
V. Plan of the Skeleton:
General Difference between Infant's and Adult's Skeleton.
VI. Articulations.
VII. Bursæ.
VIII. Movement in Articulations.

The Nature of the Human Skeleton.—In certain lower forms of life the skeleton serves mainly for protection. In some higher

Fig. 75.—The lobster, an exponent of the exoskeleton idea (from Walter "The Human Skeleton," published by The Macmillan Company).

forms it becomes important as an organ of support, as in the lobster, but in this instance, as an external skeleton, it constricts

greatly the range and skill of movement (Fig. 75). The type of skeleton seen in mammals with the organs arranged on the outside of a bony scaffold increases enormously the possibilities of life. The external skeleton of the crustaceans and mollusca is a lifeless sort of thing consisting of tiny plates deposited by the skin cells of the animal; the internal skeleton as seen in man is a living mechanism that can adapt itself to the changing needs of the individual. Moreover, an internal skeleton admits of easy growth, whereas an external skeleton limits growth in size. The skeleton of man, instead of being a lifeless thing like the shell of a lobster, is a mechanism still capable of change, and hence it is of great interest.[1]

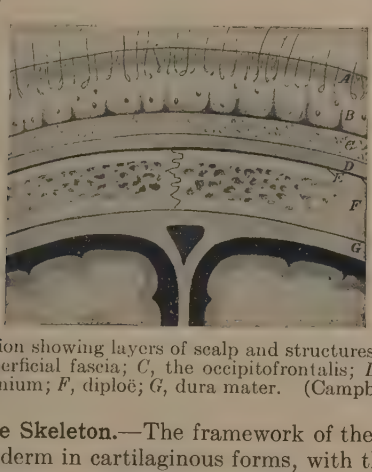

Fig. 76.—Section showing layers of scalp and structures beneath: *A*, The in; *B*, the superficial fascia; *C*, the occipitofrontalis; *D*, subaponeurotic yer; *E*, pericranium; *F*, diploë; *G*, dura mater. (Campbell.)

Origin of the Skeleton.—The framework of the skeleton arises om the mesoderm in cartilaginous forms, with the exception of e bones of the face and skull, which arise from two layers of rous membrane. This dual origin of bone accounts for the assification of bone into two types as regards origin—*intra-embranous* and *endochondral* bone. From these two forms the velopment of bone occurs.

Formation of Intramembranous Bone.—At an early stage before ne formation occurs, the developing brain is covered by three yers of tissue: (1) the brain membranes themselves, (2) a rous membrane, and (3) the skin. It is in this fibrous layer at the changes occur to transform it into bone. In the middle an area corresponding to the bone that is to be formed lime

salts* appear. From this center ossification continues as a radiating process that results in a net-work of bone quite compact near the center and much less so at the periphery. Between the radiating columns of calcified fibers bone-forming cells called *osteoblasts* begin the construction of bone. Occasionally an

Fig. 77.—*x*-Ray of fetus eighth month: Length, 45 cm.; weight, 3 pounds 8½ ounces (DeLee).

osteoblast becomes caught in a lacuna of the forming bone and remains there as a bone cell. Ultimately in this type of bone spaces are formed which are filled with blood-vessels and marrow.

* Berzelius gives the composition of bone as follows:

Gelatin and blood-vessels	33.30
Calcium phosphate	51.04
Calcium carbonate	11.30
Calcium fluorid	2
Magnesium phosphate	1.16
Sodium oxid and sodium chlorid	1.20

or a time the newly formed bones are separated from adjacent nes by unossified membrane. Even at birth conspicuous areas re left at the site of union of two or more of the brain areas. 'hese unossified areas are called *fontanels*. The final stage in ıtramembranous ossification shows the bones of the skull

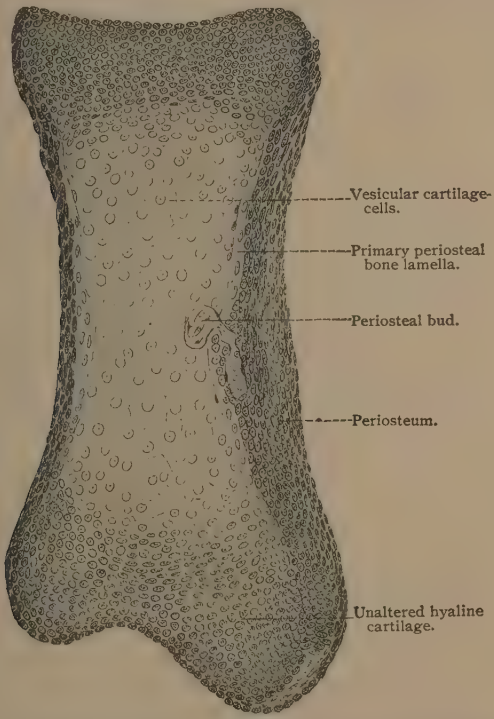

Fig. 78.—Longitudinal section through a long bone (phalanx) of a lizard nbryo. The primary bone lamella originating from the periosteum is roken through by the periosteal bud. Connected with the bud is a periosal blood-vessel containing red blood-corpuscles. (Böhm, Davidoff and uber.)

uilt with hard and strong outer and inner plates of bone, called *bles* (Fig. 76), between which is a soft, spongy type of bone ssue, called *diploë*.

Formation of Endochondral Bone.—The cartilage of the skeleton is fully formed by the second month. Soon after this the cartilaginous units begin to ossify and at birth much of the skeleton is bony (Fig. 77). Before ossification begins in cartilage,

Fig. 79.—Longitudinal section through area of ossification from long bone o human embryo (Böhm, Davidoff, and Huber).

the units of the skeleton are covered with a membrane, calle *periosteum*, composed of two layers of tissue: an outer laye fibrous in character and an inner one composed of bone formin cells, the osteoblasts. The first change in ossification is a

ıcrease in size of the cartilage cells in certain areas. These ;eas in long bones are in the center of the shaft (*diaphysis*) and ı the ends of the bone (*epiphysis*) often in several places. This rowth of the cartilage cells results in a loss of their vitality with ıeir subsequent degeneration and disappearance leaving ɔaces into which grow cells from the bone forming layer of the ɛriosteum (Fig. 78). From this time on a dual process is at ork: destruction of cartilage and, through continued activity the periosteum, the formation of bone to replace it.

During this process there is formed in the shafts of long bones, ıe *marrow cavity*, a space rich in fat, blood, and the bone cells

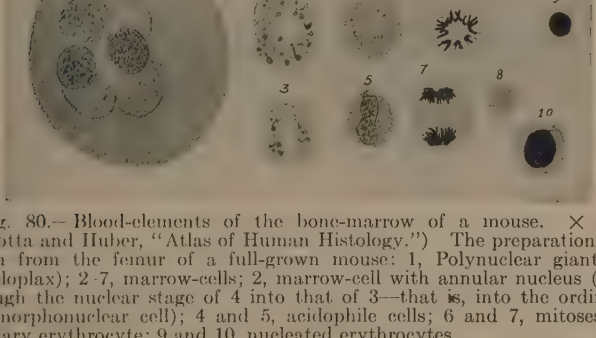

Fig. 80.— Blood-elements of the bone-marrow of a mouse. × 700. obotta and Huber, "Atlas of Human Histology.") The preparation was ken from the femur of a full-grown mouse: 1, Polynuclear giant-cell ıyeloplax); 2-7, marrow-cells; 2, marrow-cell with annular nucleus (goes rough the nuclear stage of 4 into that of 3—that is, into the ordinary lymorphonuclear cell); 4 and 5, acidophile cells; 6 and 7, mitoses; 8, linary erythrocyte; 9 and 10, nucleated erythrocytes.

active in reconstructing the character of the skeleton. Beyond e cavity the weakened cartilage cells are arranged in columns :tween which are the areas of newly-formed bone (Fig. 79). ; ossification proceeds some of the bone cells are surrounded by e bone construction of other cells. These spaces called *cunæ* and their imprisoned osteoblasts give mute testimony of e part played by these cells in this remarkable transformation cartilage into bone.

An area of cartilage between the diaphysis and epiphysis ·sists as the *epiphyseal cartilage* until the growth in length of e bone is complete, at which time it, too, becomes transformed to bone.

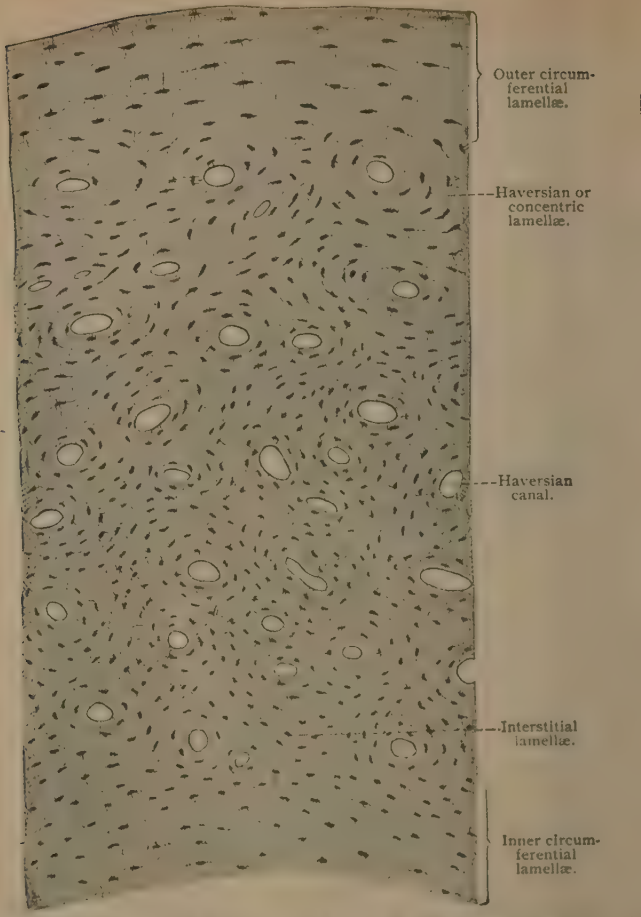

Fig. 81.—Segment of a transversely ground section from the shaft of long bone, showing all the lamellar systems. Metacarpus of man. (Bolin Davidoff, and Huber.)

The ossification of cartilage gives a structure in which th following are characteristic:

1. Bone covered with periosteum externally.

Fig. 82.—Longitudinal section through the whole femur (Koch).

2. Compact or hard bone seen in the shafts of long bones.
3. Spongy or soft bone seen in the extremities of long bones and in irregular bones.

4. A cavity within the bone, known as the medullary cavity, and well defined in long bones. Within the cavity is marrow—red in the infant, and red and yellow in the adult. Red marrow is blood-forming tissue and contains myelocytes,* nucleated and non-nucleated red blood-cells, leukocytes, and giant-cells called myeloplaxes (Fig. 80). Red marrow begins to change into yellow marrow in the fourth year of life, and at fourteen the proportion

Fig. 83.—Section of the head of the thigh bone of a woman of eighty-two years. Note the loss of the spongy bone (Minot).

in the child of red and yellow marrow is the same as in the adult. In the adult an extraordinary demand for the formation of red cells is met by the conversion of yellow into red marrow. This is

* Myelocytes are not present in normal blood, but occur in large numbers in leukemia, and particularly in myelogenous leukemia.

not possible in the child under four, hence the younger the child, the less readily can he adjust to a loss of blood.

5. In the long bones an endosteum, similar to the periosteum, lines the marrow cavity.

6. The compact bone is arranged in bony units called *haversian* systems (Fig. 81).

7. Spongy bone, particularly in the long bones, illustrates a remarkable arrangement of the tissue to secure lightness and strength.* The network of bone exhibits a mechanical adjustment of stress and strain planes to most easily bear superimposed weight (Fig. 82).

Growth of Bone.—Bone formed from cartilage grows in diameter and in length. It has been frequently stated that growth in diameter proceeds by deposition of bone beneath the periosteum

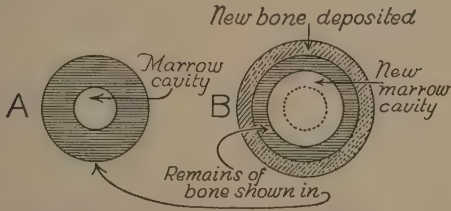

Fig. 84.—Diagram to show how a long bone grows in circumference. A, cross section of a long bone. B, cross section of bone that has deposited new bone and enlarged the marrow cavity.

by the action of osteoblasts and the eating away of bone in the marrow cavity by the action of osteoclasts (Fig. 84). Wolff's experiments indicate that the osteoblasts are engaged in remodeling and rebuilding the internal structure according to lines of stress bearing upon the new bone.[2] Whatever the exact nature of the process, it results in an increase in size and strength of the part without greatly increasing its weight. Growth in length occurs at the epiphyseal cartilage. There is observed to occur a proliferation of the epiphyseal cartilage with a subsequent ossification of portions of the new tissue, the result being a linear extension (Fig. 85). After the period of growth is past the shaft and ends of the bones become firmly united, and hence after

* In the aged much of the internal spongy structure of the bones is lost through degenerative changes, and there is left only a hard shell of compact bone (Fig. 83). This partly explains the greater liability of fracture in old persons.

ossification of the epiphyseal cartilage there cannot occur growth in length.

Growth in size of the skull (membranous bone) to give room for the developing brain is accomplished by the combined action of the osteoblasts and osteoclasts.

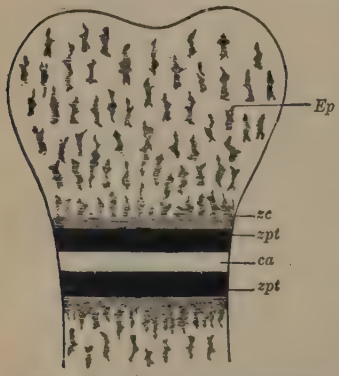

Fig. 85.—Schematic diagrams showing epiphysis and diaphysis and line of ossification: *Ep*, Epiphysis of endochondral bone; *zpt*, zone of proliferation; *zc*, zone of calcification; *ca*, cartilage. (Poirier and Charpy.)

Non-use of a part causes atrophy. This result in the case of muscles is well known, but it occurs also in bones. If disuse prevails during the period of adolescence, the bones of the non-used part may not grow normally and may even cease to grow before the time for the normal growth period to end.[3]

Injury* in a child may result in separation of the epiphysis from the diaphysis, and unless appropriately treated growth in length may be seriously impaired.

General Characteristics of Bone.—The development of bone results in a structure composed of compact and spongy material covered with periosteum, and containing a cavity filled with marrow and lined with endosteum. It should be noted that a wide variation exists in the degree of ossification in different

* Bones may be injured by other than mechanical forces. In cretinism the bones show a lack of proper development. This is due to a deficiency in secretion of the thyroid gland. Many common skeletal deformities are the result of rickets in the young child. This condition causes bow-legs, head and chest malformations. Rickets may be prevented by proper living, in which sunlight is a very important factor. The condition can be cured by systematic exposure to sunlight or by the administration of cod-liver oil. The element lacking in the nourishment of bone when this condition develops is a vitamin.[5]

Fractures of bone may be complete, in which the continuity of the bone is lost, or only partial. The latter, commonly seen in children who have suffered injury, is known as a "greenstick fracture."

A fracture of a bone is repaired by the formation at the site of the injury of a callus. In this process of repair connective-tissue cells first appear. Subsequently bone cells from the periosteum grow into the newly formed tissue and later a deposition of lime salts occurs (Figs. 86, 87). "Setting" a fracture consists in bringing the broken parts together in normal position. Often the tone of the muscles makes it difficult to get the ends in apposition. The *x*-ray is used to determine the accuracy of the procedure.

bones. With some bones ossification begins in the fetus (Fig. 77), but in most bones it is not complete until the twenty-fifth

Fig. 86.—Callus of fracture (dog), four weeks; commencing ossification of external callus (Warren.)

Fig. 87.—Femur of a child fifth week after fracture (Warren.)

Projections.	*Depressions.*
Process—a general term for projection.	Fossa—a pit or cavity.
Spine—a sharp projection.	Groove—a furrow.
Tubercle—a small rounded projection.	Sulcus—a furrow.
Tuberosity—a large rounded projection.	Sinus—a groove, as used to designate a structure on the inner surface of the skull.
Trochanter—a very large process.	Sinus, antrum, or cavity are used to designate a hollow space within a bone.
Crest—a ridge-like projection.	
Condyle—a rounded swelling at an articular extremity.	Foramen—a hole or opening in bone.

year of life. The anatomic age of a child may be determined quite accurately by means of a radiograph of the carpal bones.[4]

Fig. 88.—Photograph of the skeleton, with outline, of a man aged thirty-seven years; height 6 feet, 1 inch. (From McClellan's "Anatomy in its Relation to Art.")

Bones are classified sometimes as long, short, flat, or irregular, but such grouping is of little value because of the looseness of the

categories. In general, the long bones are in the extremities, the short bones in the hands and feet, the flat bones in the skull, and the irregular bones in the wrists, ankles, pelvis, shoulder-girdle, and spine.

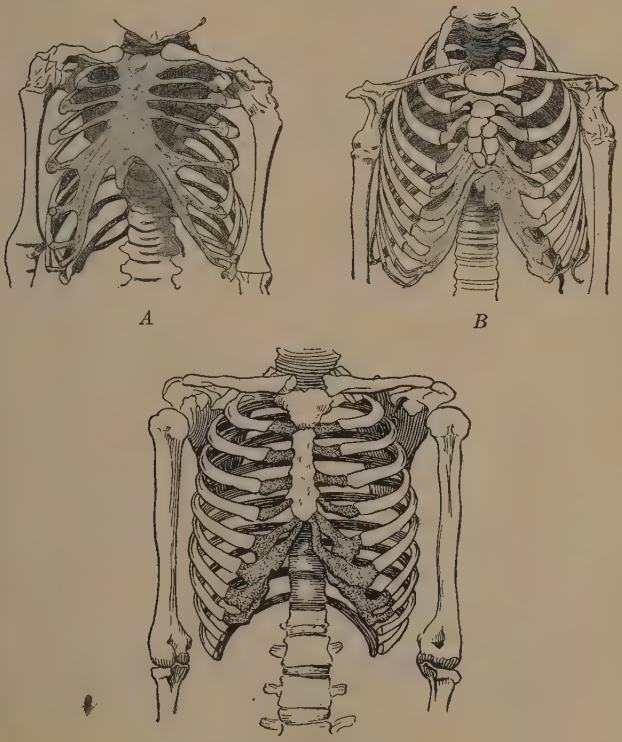

Fig. 89.—Ribs and sternum, to show the progressive ossification of the cartilage, which is indicated by stippling: *A*, Child at birth, reduced from life-size. *B*, Child at seven years, much reduced. *C*, Adult, thirty years, very much reduced, from life. From specimens in the Warren Museum of the Harvard Medical School. (From Minot.)

All bones show markings upon their external surface due to the pull of muscles or stresses of weight. These markings are in the form of projections or depressions (See p. 101).

Plan of the Skeleton.—Looking at the skeleton of man (Fig. 88) there is noticed parts corresponding to the head and trunk and parts corresponding to the extremities. The former, comprising the spine, thorax, and skull, is called the *axial* skeleton; the latter is the *appendicular* skeleton. This arrangement is common to all vertebrates, but the assumption of the upright posture by man has required definite skeletal adjustments, throwing strains and stresses upon parts that would function better in a horizontal position.[6] Although following the same plan, the skeleton of the infant and child shows marked differences compared with the adult's.

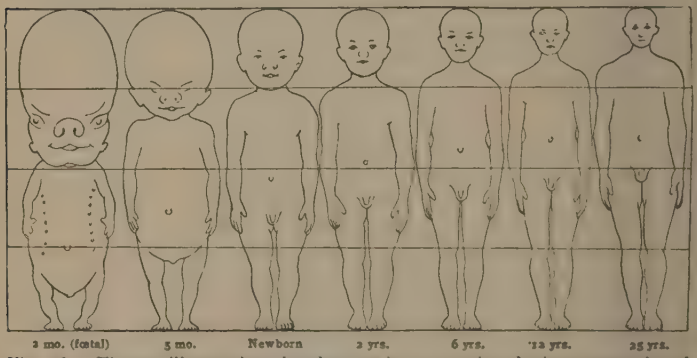

Fig. 90.—Figures illustrating the changes in proportion during prenatal and postnatal growth (Stratz).

General Difference Between Infant's and Adult's Skeleton.—1. The skeleton of the infant shows a large proportion of cartilage and fibrous tissue. This fact explains the comparative softness of bone in the infant. In Fig. 89 the thorax of the newborn child and the child of seven years should be compared with that of the adult. Proportional growth from early fetal life to the twenty-fifth year is shown in Fig. 90. The relatively greater size of the head of the infant is the predominating characteristic.

2. The skeleton of the infant provides for growth of the organs related to the part. This is conspicuous in the bones of the skull, where they are loosely held together by membrane, the anterior fontanel (see page 136), closing at about the end of the second year.

3. The skeleton of the infant differs chemically from that of the adult. The bones of the adult contain about 68 per cent. of mineral matter; those of the infant, about 66 per cent. Feldman* gives the following analyses:

Ages.	Birth.	Ten years.	Thirty-six years.	Seventy-one years.
Organic matter	33.37	32.62	32.04	32.94
Inorganic matter	66.63	67.88	67.96	67.60

4. The periosteum is thicker, more easily removed, and contains more blood-vessels in the infant.

5. The proportion between face and cranium is more equal in the adult than in the infant. In early infancy the face to cranium is as 1 to 8; in adult life it is as 1 to 2.

During infancy all parts of the skull grow rapidly. At six months the cranial capacity has increased from 400 to 700 c.c.; at eighteen months it is over 1000 c.c. The growth of the face

Fig. 91.—Diagram comparing the jaw of an infant with that of an adult (after Kölliker). (From Walter's "The Human Skeleton," published by The Macmillan Company.)

is even more rapid, marked by a great increase in the orbits, the maxillæ, and mandible, dentition being responsible for the growth of the jaws. By the second year the ratio of 1 to 8 has been reduced to 1 to 6, and by the fifth year it is 1 to 5. This growth of the face is the characteristic feature of skull development in this period. In adolescence the skull again shows a growth acceleration. The cranial portion enlarges mainly due to increase in thickness of the bones of the vault. In this period also the facial bones complete their full development, with formation of sinuses and enlargement of the dental arches. These changes in adolescence are more marked in the male than in the female.

6. The jaws of the infant are very small and undeveloped (Fig. 91).

7. In the infant the thorax is round; in the adult it is an ellipse. After the first year of life the thorax increases in diameter very

* Feldman, W. M.: Prenatal and Postnatal Child Physiology, Longmans, Green & Co., New York, 1920, p. 317.

much faster than the head, as is shown in the following figures given by Feldman*:

Age.	Circumference of head. Cm.	Inches.	Circumference of thorax. Cm.	Inches.
Birth	33	(13)	31	(12½)
5 months	42	(16½)	41	(16¼)
1 year	45.5	(18)	47.5	(18¾)
2 years	48	(19)	51	(20⅛)
3 years	51	(20⅛)	55	(21¼)
6 years	52	(20½)	55	(21¾)
10 years	53	(21)	62	(24½)
13 years	54	(21¼)	66	(26)
Adult	55	(21½)	83	(33¼)

Expressed in other figures, the greater transverse diameter of the thorax is indicated by the following proportion: At birth the anteroposterior diameter is to the transverse as 1 is to 1.5; at three years it is as 1 to 2; and in the adult it is as 1 to 3.

In both infant and adult it will be noted that the skeleton is formed of separate bones held together by bands of white connective tissue called ligaments, forming joints or articulations.

Articulations, or joints, are classed in three groups according to their movability:

1. An immovable joint or synarthrosis is one with no movement possible.

2. A slightly movable joint or amphiarthrosis is one with limited motion.

3. A freely movable joint, true joint, or diarthrosis is one in which movement is limited only by the shape of the bones and the contiguous parts.

Immovable joints are characteristic of the articulations in the skull. Here the union is spoken of as a *suture.* In most unions of this type the margin of the bones is very irregular and there is a small strip of fibrous tissue between the bones. Occasionally small bony islands exist in the course of a suture. They are called wormian bones (Fig. 92).

Slightly movable joints are found typically in the articulations of the spine, and between the two halves of the pelvis in front (symphysis pubis) and behind with the sacrum. These joints are characterized by an interarticular disk of fibrocartilage. Ligaments bind the bones closely together, allowing little movement.

* Feldman, W. M.: Prenatal and Postnatal Child Physiology, Longmans, Green & Co., New York, 1920, p. 326.

True or freely movable joints are found in the extremities. They are constructed for movement as shown by (1) the arrangement of the bony parts; (2) the synovial membrane that supplies a lubrication, the synovial fluid; (3) the articular surfaces of hyaline cartilage providing smooth, elastic bearings, and (4) the arrangement of the capsular ligaments of the joints permitting great freedom of movement and yet withal giving strength and support to the part (Fig. 93).

In close approximation to the joints at places where tendons slide over bone or ligament there are pad-like sacs filled with fluid. These are called *bursæ*.

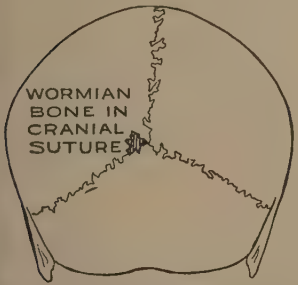

Fig. 92.—Wormian bone indicated by shaded area.

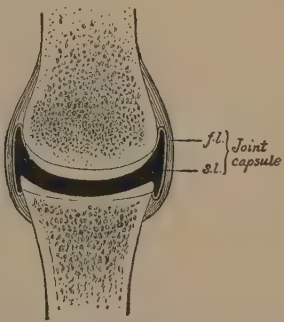

Fig. 93.—Diagram of section of true joint: *f.l.*, Fibrous layer; *s.l.*, synovial layer of joint capsule. The articular cartilages are white, bones dotted, and the joint cavity black in the figure. (Sisson, "Anatomy of Domestic Animals.")

Bursæ.—A bursa develops where friction occurs. Formed from fibrous tissue, the inner lining of a bursa exhibits a quality similar to synovial membrane and secretes a fluid resembling synovial fluid. Bursæ are of different sizes. The most prominent ones are located at the elbow, knee, hip, and heel, also underneath certain muscles, *e.g.*, the deltoid,* the trapezius, and around the tendons attaching to the upper part of the leg. There are

* The bursa under the deltoid is frequently called the subacromial bursa (Fig. 94). When this bursa is inflamed, movements of the arm are very painful, especially adduction and active abduction. Nurses in moving a patient with bursitis in this area must remember the action of the deltoid if they would avoid discomfort for the patient.

many other bursæ, but the above are always present in the adult. They may become markedly enlarged.

Movement in Articulations.—In the slightly movable joints a gliding movement may take place, but in the freely movable ones some or all of the following varieties occur: flexion, extension, abduction, adduction, rotation, and circumduction.

Flexion in a joint is movement in an anteroposterior plane with the angle between the anterior aspects of the parts getting smaller (Fig. 95). Examples: Making a fist, raising the knee forward.

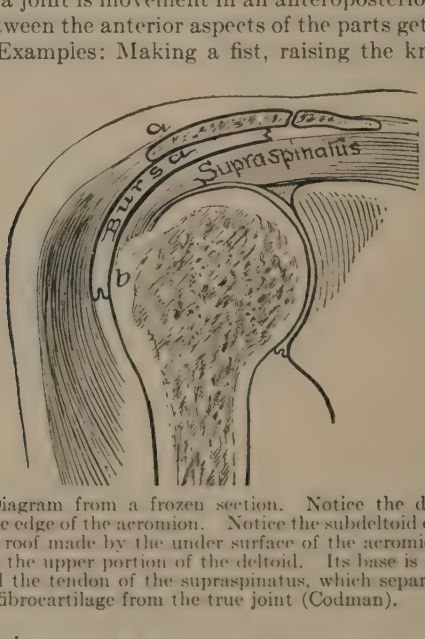

Fig. 94.—Diagram from a frozen section. Notice the deltoid and its origin, from the edge of the acromion. Notice the subdeltoid or subacromial bursa with its roof made by the under surface of the acromion and by the fascia beneath the upper portion of the deltoid. Its base is on the greater tuberosity and the tendon of the supraspinatus, which separates it like an interarticular fibrocartilage from the true joint (Codman).

Extension in a joint is movement in an anteroposterior plane with the angle between the anterior aspects of the parts getting larger (Fig. 96). Extension is, therefore, the reverse of flexion. Sometimes the term "backward flexion," or "hyperextension," is used to indicate a continuation of the extension posteriorly to the vertical position of the body. Commonly, flexion occurs forward and constitutes a bending of the body or a part; extension is usually a restitution of the part to the plane as given in the anatomic position of the body. Examples: Straightening the knee, pointing the toes downward (ankle extension).

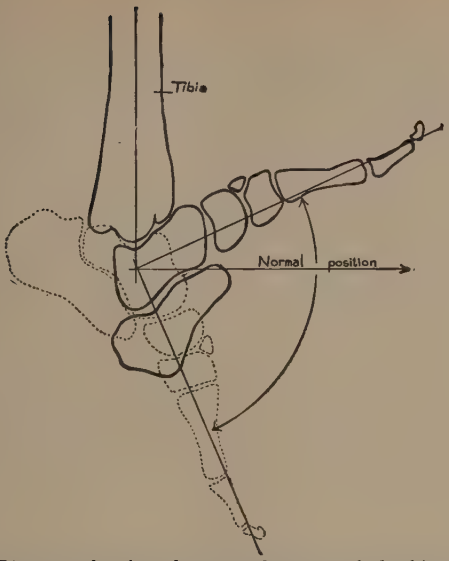

Fig. 95.—Diagram showing the normal extent of the hinge movement allowed by the ankle. Compare with Fig. 96. (From Walter's "The Human Skeleton," published by The Macmillan Company.)

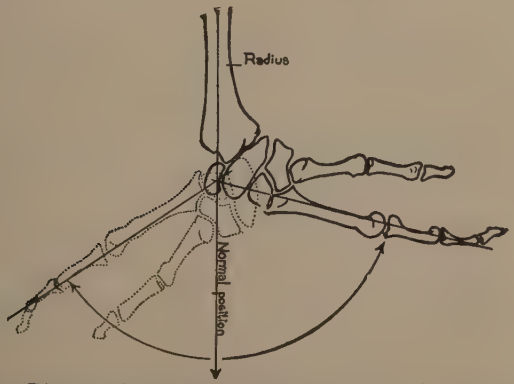

Fig. 96.—Diagram showing the normal extent of the hinge movement by the wrist. Compare with Fig. 95. (From Walter's "The Human Skeleton," published by The Macmillan Company.)

Abduction in a joint is movement away from the sagittal plane of the body with the angle between the parts getting larger. Abduction of the trunk is sideward bending of the trunk, in which the moving trunk is one part and the vertical line of the body in the anatomic position is the other. Frequently a projection of a line of the part is necessary, for example, in flexion in the shoulder-joint. Examples: Raising arms sideward, bending the trunk sideward.

Adduction in a joint is movement toward the sagittal plane of the body with the angle between the parts getting smaller. Examples: Bringing the fingers together, raising the trunk from a sideward position.

Rotation in a joint is rarely seen in the body in a pure form because some torsion usually accompanies the movement. It may be defined as movement around the axis of the part without displacement. Example: Rotation in the forearm.

Circumduction is movement that combines the elements of flexion, extension, abduction, and adduction. In circumduction

Fig. 97.—Circumduction the extremity (hand) describes a circle and the part (arm) describes the sides of a cone. (From Williams, "Healthful Living," published by The Macmillan Company.)

the extremity of the part describes a circle and the part itself the sides of a cone (Fig. 97). Example: Swinging the arms, legs, or trunk in a circle.

PRACTICAL EXERCISES

1. Study radioscopic plates of bone parts, noting the relative density of different areas in bone.

2. Secure a joint at the butcher's shop and study an articulation. Note ligaments, tendons attached near the ends of bone, synovial membrane. Note the cut end of a long bone, observing particularly the density of the compact bone, the marrow cavity, marrow, endosteum, and periosteum.

3. With a sharp knife or razor cut a thin slice from one of the joint ends of the bones of the specimen used above. Place strip on a slide, mount in water, and examine with the microscope. Notice the distance between the

cells. This represents intercellular substance derived from the cartilage cells.

4. Take a green stick and a dry one and note how the two break when force is applied to them. Are the parts easily separated in the dry one? Is there a tendency to split and not to break in the green one?

5. Locate on a skeleton a spine, a condyle, a crest, a fossa, a groove, a foramen. Make a corresponding observation on your own body so far as possible.

QUESTIONS

1. Describe how bone grows in length.
2. What would be your judgment of a method of therapy that purports to increase the height of persons after the age of twenty-five years?
3. How important is food in relation to proper growth of bone? What are the bony changes in rickets, cretinism, acromegaly, and fracture?
4. Name the distinguishing differences between an adult's and child's skeleton.
5. What is a bursa? What is bursitis?
6. Demonstrate flexion of the fingers, elbow, thigh, trunk; extension of the toes, leg, head; adduction of the trunk, arm; adduction of the thigh; rotation of the trunk; circumduction of the arm.
7. How is a fracture of a bone repaired?
8. How important is activity for proper growth of bone?
9. Why do fractures readily occur in the aged?
10. What is the function of the periosteum?

REFERENCES FOR FURTHER STUDY

1. Walter, H. E.: The Human Skeleton, The Macmillan Co., New York, 1918. The entire book.

2. Feldman, W. M.: Prenatal and Postnatal Child Physiology, Longmans, Green & Co., New York, 1920, pp. 342–347.

3. Allison, N., and Brooks, B.: Bone Atrophy, Archives of Surgery, November, 1922, p. 499.

4. Baldwin, B.: Physical Growth of Children from Birth to Nativity, University of Iowa Studies, 1921.

5. Grieves, C. J.: The Effect of Defective Diets on Teeth, Jour. Amer. Med. Assoc., November 4, 1922, pp. 1567–1573.

McCollum, E. V., and Associates: Experimental Rickets: VI. The Production of Rickets by Diets Low in Phosphorus and Fat-soluble A, Journal Biological Chemistry, August, 1921.

6. Tyler, J. M.: What Teachers Ought to Know, Nat. Educ. Assoc. Proceedings, 1918.

CHAPTER V

THE SKELETON—SPINE AND SKULL

I. The Spine.
II. Curves of the Spine.
III. Differences in the Spine of Child and Adult.
IV. A Typical Vertebra.
V. Characteristics in Different Regions.
VI. The Intervertebral Disks.
VII. The Ligaments of the Spine:
    1. The Anterior Common.
    2. The Posterior Common.
    3. The Ligamenta Subflava.
    4. The Supraspinous.
VIII. Movements of the Spine.
IX. Injuries of the Spine.
X. The Skull.
    1. The Occipital Bone.
    2. The Parietal Bones.
    3. The Frontal Bone.
    4. The Temporal Bones.
    5. The Ethmoid Bone.
    6. The Sphenoid Bone.
    7. The Maxilla Bones.
    8. The Mandible Bone.
    9. The Malar Bones.
    10. The Lacrimal Bones.
    11. The Nasal Bones.
    12. The Vomer Bone.
    13. The Palate Bones.
    14. The Inferior Turbinate Bones.
XI. The Skull as a Whole:
    1. Cavities.
    2. Sinuses.
    3. Fossæ.
    4. Processes.
    5. Sutures.
    6. Fontanels.
XII. Hyoid Bone.

The **spine,** or **vertebral column,** is the chief part of the axial skeleton. It is a segmented, flexible rod, supporting the head, protecting the spinal cord, and giving a base for the ribs, the upper and lower limbs. The structural unit of the column is the

vertebra, of which there are thirty-three, at times thirty-four, although in the young embryo as many as thirty-eight are found. The vertebræ vary in shape, size, and number in different regions of the spine, so that according to distinguishing characteristics of the different vertebræ there is recognized the *cervical* region with seven vertebræ; the *thoracic*, with twelve; the *lumbar*, with five; the *sacral*, with five; the *coccygeal*, with either four or five.

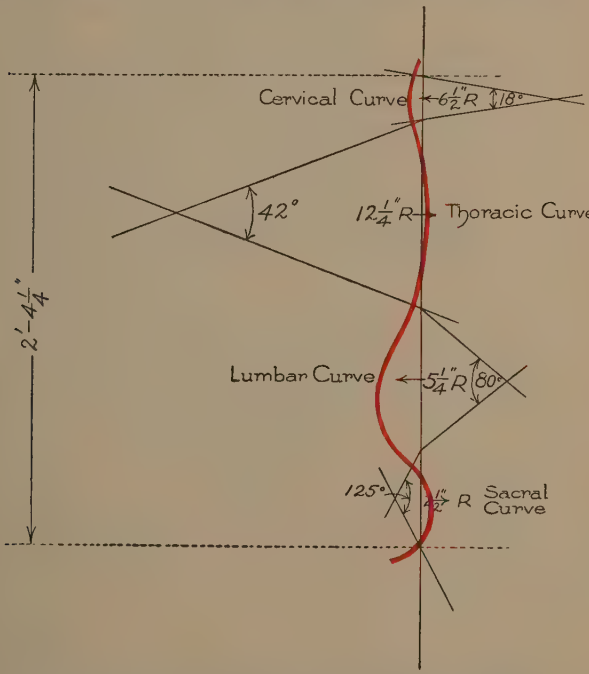

Fig. 98.—The data given above are from actual measurements. (From Lectures, Professor George Huntington.)

Curves of the Spine.—In the embryo the spine is in a position of flexion that is continuous as a concavity forward from head to sacrum. The newborn infant shows the persistence of this position which only begins to change as the child attempts to hold the head erect and, later on, to crawl. The erect position of the head

attained at about the fourth month produces a backward curve in the cervical region. The period of crawling shortens the ligaments and structures on the front of the hip-joint, and subsequently, when efforts are made to stand, the pelvis is held forward and a compensating curve results in the lumbar segment.

Fig. 99.—Human embryo of about twenty-eight days (His): *I*-V, Brain-vesicles; f^2, f^3, f^4, cervical, dorsal, and lumbar flexures; *ot*, optic vesicle; *ol*, olfactory pit; *mx*, maxillary process; h^1, h^2, heart; *l*, l^1, limbs; *als*, allantoic stalk; *ch*, villous chorion.

There results from this adjustment four curves (Fig. 98), as follows:

1. The *cervical curve*, extending from the first vertebra to the second thoracic. It is convex forward.

2. The *thoracic curve*, extending from the second thoracic to the twelfth thoracic. It is concave forward.

3. The *lumbar curve*, extending from the twelfth thoracic to the sacrum. It is convex forward.

4. The *sacral curve*, extending from the base to the tip of the sacrum. It is concave forward.

The thoracic and sacral curves are *primary*. They remain as parts of the original embryonic posture (Fig. 99). The cervical and lumbar curves are *secondary*. They result as compensations from balancing efforts in holding up the head and in assuming the erect posture.

Differences in the Spine of Child and Adult.—At birth the child's spine is very flexible. It can be twisted in nearly every direction. This is due to the cartilaginous character of the vertebræ, which begin to ossify in the third year of life, and the softness of the ligaments and muscles surrounding the parts. The relative and absolute lengths of the cervical, thoracic, and lumbar segments vary as indicated below:

Age.	Observer.	Absolute length in millimeters.				Relative length (total = 100).		
		Cervical.	Thoracic.	Lumbar.	Total.	Cervical.	Thoracic.	Lumbar.
Newborn....	Feldman	45	84	47.5	176.5	25.4	47.6	27
Newborn....	Ravenel	40	100	50	190	21	52.6	26.3
3 months...	Ravenel	50	100	58	208	24	48.1	27.9
6 months...	Aeby	52.5	103	60	215.5	24.3	47.5	27.8
10 months...	Dwight	61	125	77	263	23.2	47.5	29.2
2 years.....	Aeby	79.5	153.5	98	331	24	46.4	29.6
5 years.....	Symington	80	170	104	354	22.5	48	29.4
11 years.....	Aeby	91	218.7	153.5	463.2	19.7	47.2	33.1
17 years.....	Dwight	113	250	161	524	21.5	47.7	30.7
Adult.....	Feldman	129.9	273.4	184	587.3	22.1	46.5	31.3

Analysis of the above table shows that in growth from infancy to adult life there is a relative greater growth in the lumbar region than in either the cervical or thoracic, in fact, the latter two regions show a relative greater length in infancy than in adult life.

A Typical Vertebra.—The vertebræ vary in size and shape, but in general they conform to a plan of structure which is typical of all. Viewed from above the distinguishing characteristics may be noted (Fig. 100). The *body* is a central mass of bone, cancellous in character, that forms the anterior portion of the vertebra. This part gives the main support. The *pedicles* are two processes of bone extending posteriorly to join with the *laminæ* in the construction of the *neural arch* and *neural canal*. At the junction of laminæ and pedicles there pass off at each side the *transverse processes*, and where the laminæ meet behind is the

root of the *spine* of the vertebra.* The common meeting place of transverse process, lamina, and pedicle is marked on each side by two articular processes, making four in each vertebra. These

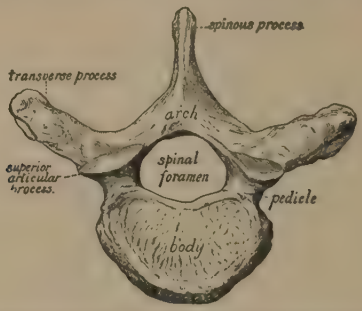

Fig. 100.—A vertebra seen from above (Sobotta and McMurrich).

are the *superior* and *inferior articulate processes.* The inferior ones of the vertebra above articulate with the superior ones of the vertebra below (Fig. 101). Viewed from the side this

Superior facet for head of rib
Inferior facet for head of rib
Inferior vertebral notch
Inferior articular process
Spinous process

Fig. 101.—The sixth thoracic vertebra from the side (Sobotta and McMurrich).

articulation is quite clear. At the junction of the pedicle with the body of the vertebra there occurs an articular facet for the head of the rib, and on the tip of the transverse processes there is one for the tubercle of the rib. Since the ribs are present only

* At times a defect of development of laminæ and spines occur, leaving a deficiency in the bony arch. This most often occurs in the lumbar region. Quite commonly there is a protrusion of the cord through the opening. The defect is called *spina bifida* (Fig. 222).

in the thoracic section, these facets appear on the thoracic vertebræ.

Characteristics in Different Regions.—Variations from this general plan occur in the different regions of the spine. In the cervical region, the first vertebra, the *atlas*, and the second, the *axis*, show an absence of the body in the former, and its fusion to the body of the latter, forming the *odontoid process*. The bodies of all the cervical vertebræ are small. The spinous processes are short and forked at the end. The transverse process is short and contains near its end a foramen which transmits the vertebral artery. The superior and inferior articular processes face upward and backward, and downward and forward respectively.

In the thoracic region the bodies are larger and all the processes longer and heavier than in the cervical. The spinous process is long and directed downward at a sharp angle. Facets for articulation with the ribs are present in this region. The superior articular processes face backward, slightly outward, and upward; the inferior ones look forward, slightly inward, and downward. The center of the circle of which these processes are arcs lies in the central line of the body of the vertebræ.

In the lumbar region the bodies are heavier and thicker than in the thoracic. The transverse and spinous processes are short, heavy, and thick. The superior articular processes face inward and slightly backward; the inferior ones look outward and slightly forward. The center of the circle of which these processes are arcs lies within the neural canal. Rotation of the spine must occur around the axis passing through the center of the circle marked out by the articulating processes. Such movement must take place without displacement of the bodies of the vertebræ, for if displacement occurred injury would result to the delicate structures within the canal. From the position of these processes it is clear that rotation occurs quite readily in the cervical region and also in the thoracic, except as hindered by the presence of the ribs. The positions of the processes make it clear why rotation does not occur in the lumbar region of the spine.

The sacrum as an adult bone seems to bear little relation to the vertebræ, but on closer study it will show certain characteristics that suggest its origin. Comparative study especially during embryonic life furnishes confirming evidence of its origin. It is formed by the fusion of five vertebræ, but is not completely ossified until the twentieth year of life. The large lateral masses

correspond to the transverse processes and ribs (Fig. 102); they form in the upper three fused vertebræ an articulating surface with the bones of the pelvis. This articulation is the sacro-iliac joint. The articulation of the top of the sacrum with the last lumbar vertebra makes the lumbosacral joint. The sacrum in the female is broader, less curved, and pointed backward more than it is in the male.

The terminal elements of the vertebral column have undergone marked degeneration in man, and although as many as eight units are laid down in embryonic life, only four or five develop. Those that develop show only the body, having lost entirely the pedicles,

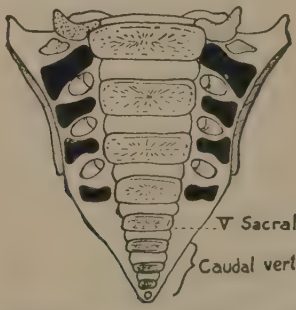

Fig. 102.—Sacrum of a five months' old human fetus showing sacral ribs (in black) (after Kollmann). (From Walter's "The Human Skeleton," published by The Macmillan Company.)

laminæ, and processes. They fuse together in one or two pieces to form the coccyx, a shriveled remnant of the tail of the ancestors of man.

The Intervertebral Disks.—Between the bodies of every two vertebræ is an elastic disk of yellow elastic fibrous tissue and cartilage. In the cervical region the disks are thin, in the thoracic they are larger, and in the lumbar segment thick and resilient (Fig. 103).

The Ligaments of the Spine.—The separate bones of the spine are held together by strong ligaments. The chief ones are as follows:

The *anterior common* ligament on the anterior aspect of the bodies runs the entire length of the spine from the axis to the sacrum (Fig. 104). It consists of shorter and longer fibers, some

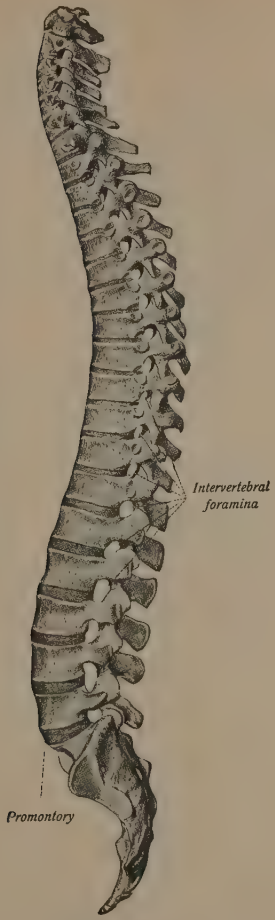

Fig. 103.—The vertebral column seen from the left side (Sobotta and McMurrich).

running from one vertebra to the next, and some skipping one or more, to attach to the second, third, fourth, or fifth one beyond.

The *posterior common* ligament runs from axis to sacrum on the posterior aspect of the bodies. It is more discrete than the anterior (Fig. 105).

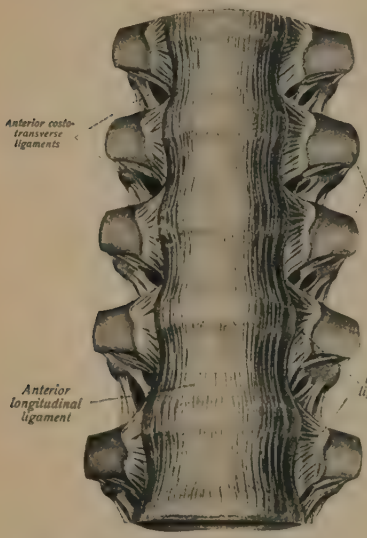

Fig. 104.—The anterior longitudinal ligament in the lower thoracic portion of the vertebral column, together with the costovertebral ligaments seen from in front (Sobotta and McMurrich).

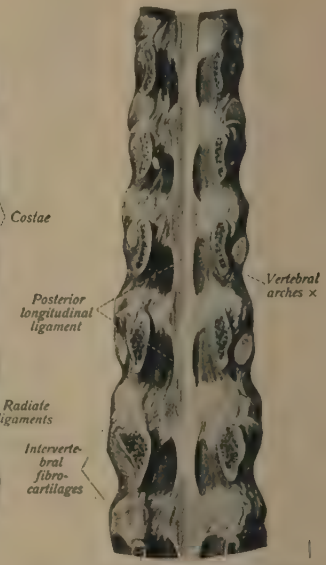

Fig. 105.—The posterior longitudinal ligament in the lower thoracic and upper lumbar portions of the vertebral column. The vertebral arches have been removed (Sobotta and McMurrich).

The *ligamenta subflava* are bands of considerable strength connecting the laminæ. They extend from the axis to the sacrum and are more marked in the lumbar region (Fig. 106).

The *supraspinous* ligament connects the tip of the spinous processes and extends between the borders of the spines as the interspinous ligament. This is a very well-developed ligament. In the cervical region a modification of the supraspinous ligament is seen in the *ligamentum nuchæ*. This structure, though markedly developed in quadrupeds with pendant heads, still shows in man as a rather thick band of tissue.

The *ligaments* of *occipital bone, atlas,* and *axis* connect the skull with the vertebral column, providing for security and free movement of the head.

The shape and articulations of the vertebræ and the strong inelastic ligaments that bind the separate bones together into a flexible but strong column are anatomic facts that suggest that the vertebræ are not easily displaced. Displacement may and does occur, but not with any high frequency.

Movements of the Spine.—The spine is freely movable.[1] There occurs flexion, extension, abduction, adduction, rotation, and circumduction. In most instances a pure type does not exist; there is probably a mingling of two or more types in all natural movements of man. Rotation does not occur in the

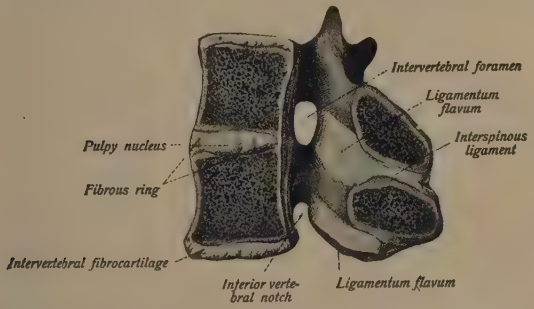

Fig. 106.—Two thoracic vertebræ divided longitudinally in the median line and showing the ligamenta flava (Sobotta and McMurrich).

lumbar region, but does in a limited fashion obtain in the cervical and thoracic segments. The spine normally shows four curves. It is not uncommon to find an increase in the thoracic region. Such increase over the normal curve of this region is called *kyphosis*. It may result from postural habits, occupation, or disease. An increase in the lumbar curve is called *lordosis* or hollow back (Fig. 107). Often these curves can be reduced to normal or be greatly improved by appropriate exercises and muscular education.[2]

Normally the spine appears from the rear as a straight line. In perfectly well persons a slight curvature to the right may be seen in the thoracic region. Due to muscular paralysis, weakness, or disease in the vertebræ a lateral curvature, *scoliosis*, may result.

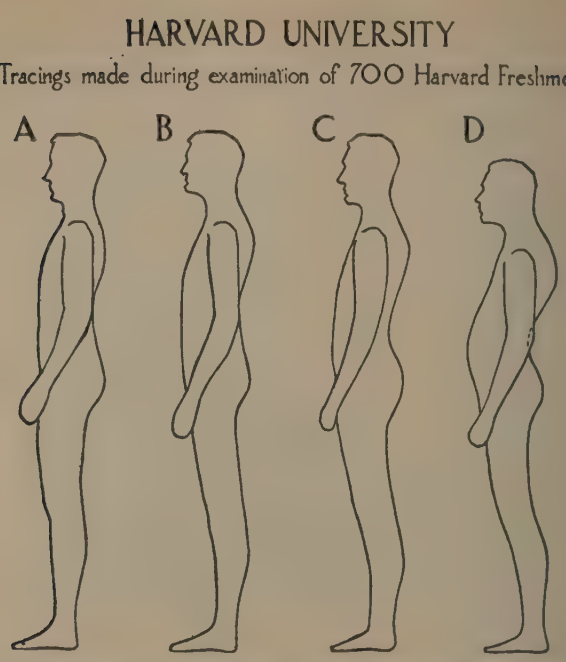

Fig. 107.—Group A, 7.5 per cent. Good mechanical use of the human body: 1, Head straight above chest, hips, and feet; 2, chest up and forward; 3, abdomen in or flat; 4, back, usual curves not exaggerated.

Group B, 12.5 per cent. Fairly good mechanical use of the human body: Note changes from Group A. 1, Head too far forward; 2, chest not so well up or forward; 3, abdomen very little change; 4, back very little change.

Group C, 55 per cent. Bad mechanical use of the body: Note changes from Group A. 1, Head forward of chest; 2, chest flat; 3, abdomen relaxed and forward; 4, back curves are exaggerated.

Group D, 25 per cent. Very bad mechanical use of the body: Note changes from Group A. 1, Head still farther forward; 2, chest still flatter and farther back; 3, abdomen completely relaxed, "slouchy"; 4, back, all curves exaggerated to the extreme.

The percentages indicated in the groups above were secured during the fall of 1916. Additional percentages since that time are as follows:

	A.	B.	C.	D.
1919	0.97	14.8	49.3	34.8
1920	2.33	17.19	51.41	29.04

While in the erect posture backward bending of the spine to straighten the thoracic curve results usually* in only an apparent straightening due to the increase in the lumbar curve. This fact is observed if the body is viewed without clothes. Persons with marked power of muscular localization may extend the thoracic spine, but while standing and for most adults and all children an increase in the lumbar curve is the product of an effort to bend

A B C D

Fig. 108.—A, Pelvic disbalance; right gluteal crease, posterior superior iliac dimple, iliac crest and anterior superior iliac spine are low; three folds in left iliocostal angle, none in right; marked right total scoliosis. B, 2-inch elevation under right foot; creases, dimples, crests, and iliac spines level; no scoliosis, iliocostal angles symmetric. C, Rhomboid tilted. D, rhomboid level. (From Journal of Amer. Med. Assoc., March 18, 1922.)

the spine backward. This is due to the following anatomic relations:

1. The greater mobility of the lumbar as contrasted with the thoracic segment.

2. The curvature in the thoracic spine is convex posteriorly; in the lumbar segment it is concave posteriorly. It is mechanically easier to continue the direction of curvature than to change it.

* Reference is here made to certain corrective exercises used in public school physical training.

3. The muscles in the back producing the movement are stronger, heavier, and thicker in the lumbar region than in the thoracic. (See Erector Spinæ, page 184.)

Injuries of the spine are not uncommon in the cervical, lumbar, and sacral regions. A sprain of the sacro-iliac joint is often serious and always distressing. Strains in the cervical and lumbar regions result from their marked mobility. Pure dislocations are, however, rare. In the former a partial dislocation occurs quite readily between the third and sixth cervical

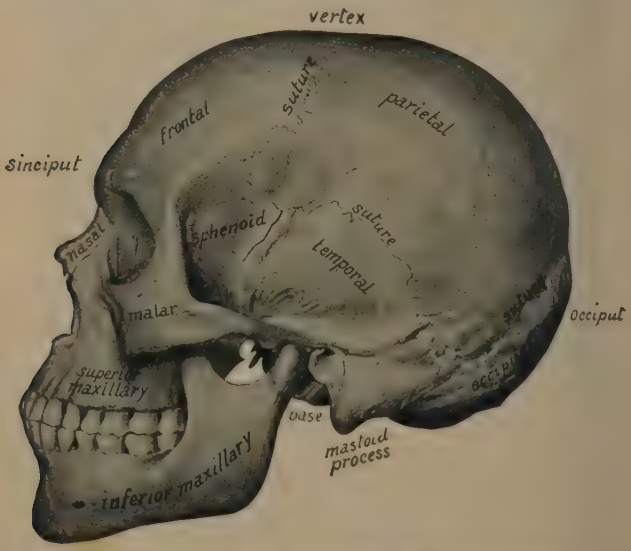

Fig. 109.—The skull seen from left side (Sobotta and McMurrich).

vertebræ. Restoration to normal is easily accomplished by bending the head backward and to the side toward which the face is turned. A condition of dislocation that occurs easily in the cervical region can result in the thoracic or lumbar segments only with the tearing of ligaments and the fracture of processes.

The normal contour and function of the spine are dependent upon equal length of the legs. The illustration* in Fig. 108 shows

* From an article by Dr. Philip Lewin, Jour. Amer. Med. Assoc., March 18, 1922.

he pelvic disbalance resulting from a shortened right leg. The orrection of the spinal curvature by elevation of the heel is ndicated.

Fig. 110.—The skull seen from in front (Sobotta and McMurrich).

The **skull** comprises the bones of the cranium (brain casket) and the bones of the face (Figs. 109, 110).

Bones of the Cranium.		*Bones of the Face.*	
Occipital	1	Maxilla	2
Parietal	2	Mandible	1
Frontal	1	Malar	2
Temporal	2	Lacrimal	2
Ethmoid	1	Nasal	2
Sphenoid	1	Vomer	1
	—	Inferior turbinate	2
	8	Palate	2
			—
			14

Study of the illustrations in Figs. 109 and 110 will reveal the position of most of the above bones in the skull. It will be noted that there are two main divisions of the skull:* the cranial portion, which houses the brain, and the facial portion, which serves as the doorway to the digestive and respiratory tracts. Examination of characteristics of the individual bones of the skull will help in understanding the skull as a whole.



Fig. 111. Sagittal diagram through the skulls of a salamander (*A*), deer (*B*), baboon (*C*), and man (*D*). The arrows indicate an evolutionary change in the relation of the external nose opening and the foramen magnum. (Modified from Wiedersheim.) (From Walter's "The Human Skeleton," published by The Macmillan Company.)

The *occipital bone* presents on its inferior surface as the most conspicuous feature a large opening, the *foramen magnum*,† for the transmission of the spinal cord on its way to connect with

* The evolution of the skull in mammals shows that the cranial portion compared with the facial portion becomes proportionately larger as we pass upward in the animal series (Fig. 111) and that the biped position has resulted in a change in the relation of nose opening and foramen magnum.

† Ibid.

the brain. On either side of the foramen magnum and along its anterior margin are two articulating processes, the *condyles*, for articulation with the atlas. Externally over the posterior surface of the bone are two ridges and a large projection, the *external occipital protuberance*. This process can readily be felt on most heads. Together with the ridges it serves for attachment of the trapezius muscles and the ligamentum nuchæ. Internally the occipital bone is marked by a deep groove, the *lateral sinus*, to which attach fibrous coverings of the brain, forming a channel for the venous blood (Fig. 112).

Fig. 112.—The falx cerebri and tentorium, and the relation of the sinuses (Campbell).

The *parietal bones* form the lateral and upper wall of the cranium (Fig. 109).

The *frontal bone* forms the forehead and the upper part of the eye sockets, where it is called the *supra-orbital margin*. It shows (Fig. 113) above the nose a small depression, the *glabella*, a landmark of considerable significance in cranial measurement. Between the two tables of bone in the supra-orbital portion are hollow spaces filled with air. These are the *frontal sinuses*. They open into the nose. The internal surface of the frontal bone is smooth, with a ridge on its sagittal plane that marks the separation of the two halves of the brain.

The *temporal bones* are paired. They contain within their bony walls two important structures—the middle and internal

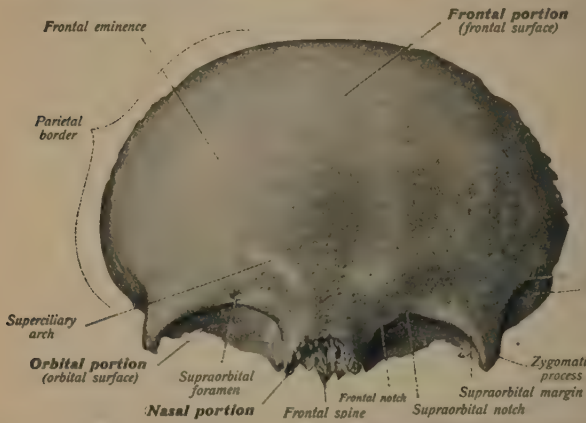

Fig. 113.—The frontal bone seen from in front (Sobotta and McMurrich).

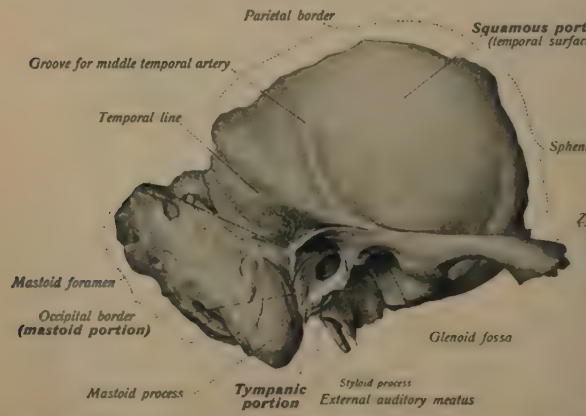

Fig. 114.—The right temporal bone seen from the outer (lateral) surface (Sobotta and McMurrich).

ear and the mastoid cells. The opening to the middle ear shows on the outer surface of the bone as a conical aperture, the *external*

auditory meatus. The *mastoid process* of the temporal bone projects downward behind the opening of the meatus (Fig. 114). Its internal structure is a soft, spongy bone containing numerous cavities, the *mastoid cells*. These cells open into the middle ear through a connecting passageway, the *antrum*. The mastoid portion of the temporal bone presents on its internal surface a groove, the *lateral sinus*, which is a continuation of the same structure on the occipital bone. The plate of bone between the lateral sinus and the mastoid cells is very thin,* although in young children there is a thick layer of cancellous bone between antrum

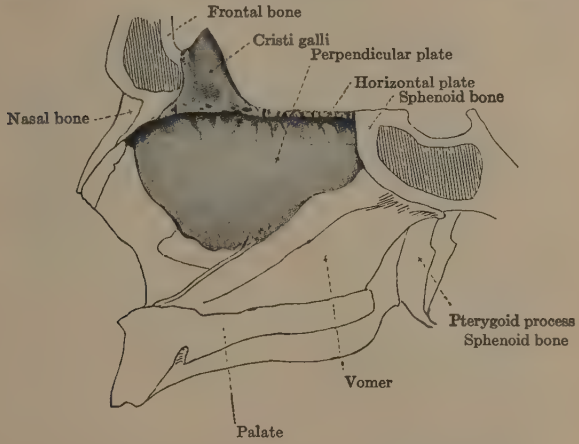

Fig. 115.—Ethmoid bone, from the left (Spalteholz).

and lateral sinus. Just above the meatus is a horizontal process of bone, the *zygoma*, that projects forward to articulate with the malar bone. Just below the zygoma and in front of the meatus is the *mandibular fossa* which receives the articulating process of the lower jaw. These points may be readily located on the head by placing the finger in front of the ear and below the zygoma, which is felt as a sharp ridge. Lowering of the jaw will reveal a depression which marks the mandibular joint. The internal ear,

* In severe infection of the mastoid this plate of bone may be eroded and the infection carry into the lateral sinus before operation is done to relieve the pressure and permit drainage externally. If such unfortunate condition develops the result is usually fatal.

containing the organs of hearing and equilibrium, is described in Chapter XIX.

The *ethmoid bone* is a small, irregular mass of spongy bone. On first appearances it seems to present no distinguishing character, but close observation shows it to have a horizontal plate perforated for the passage of the olfactory nerves to the mucous membrane of the nose, a perpendicular median plate that forms the upper part of the *nasal septum*, and two lateral masses con-

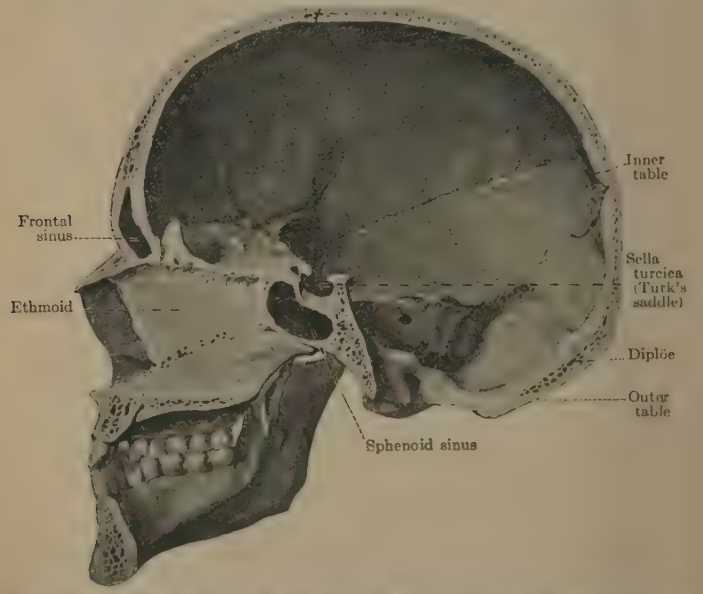

Fig. 116.—Sagittal section of the skull showing sphenoid bone and other important structures, from the left (Spalteholz).

taining the *ethmoidal cells* and the convolutions of the *superior* and *middle turbinate bones*. Riding above the median plate and the lateral masses is a ridge projecting into the cranial cavity. This is the *cristi galli*, to which is attached the covering of the brain (Fig. 115). The ethmoidal cells form the *ethmoidal sinuses*.

The *sphenoid bone* lies in the center of the skull and forms a portion of the base of the cranial cavity by its body and two broad

wing-like processes. The upper part of the body presents a depression with anterior and posterior elevations, forming a structure very like a saddle, and called the *sella turcica*, or Turk's saddle (Fig. 116), in which rests the pituitary gland. In the center of the body of the sphenoid is a cavity forming the *sphenoidal sinus* which drains into the nasopharynx. From the wings extend downward the *pterygoid processes* (Fig. 115) for attachment of muscles of the palate and pharynx.

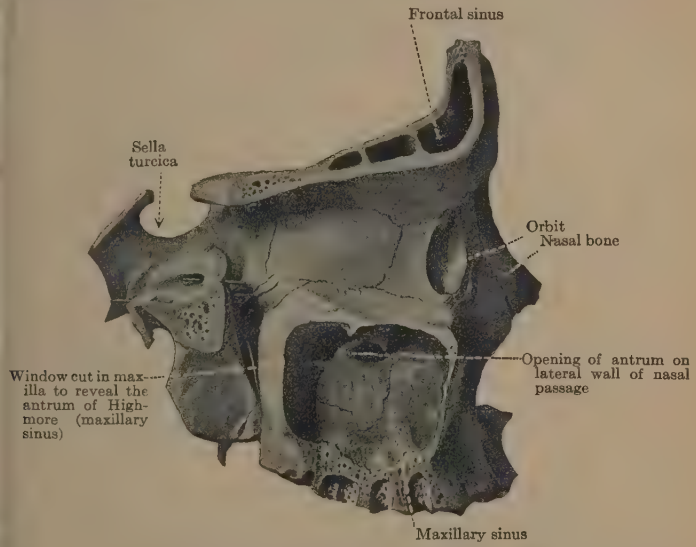
Frontal sinus
Sella turcica
Orbit
Nasal bone
Opening of antrum on lateral wall of nasal passage
Window cut in maxilla to reveal the antrum of Highmore (maxillary sinus)
Maxillary sinus

Fig. 117.—Right maxilla with maxillary sinus exposed. Note close relation with alveolar processes (Spalteholz).

The *maxilla bone* forms with its fellow the upper jaw. It gives a base for the upper teeth in a margin of spongy bone, the *alveolar process*. The body of the bone is hollow, presenting the *maxillary sinus* or the *antrum of Highmore*. This sinus opens into the nose. Its close relation to the roots of the upper teeth is indicated in Fig. 117. The outer surface of the maxilla presents two openings or foramina, the *infra-orbital foramen* and the *posterior dental canal*. The under surface of the bone exhibits a horizontal portion that forms with the palate bone the roof of the mouth.

The *orbit*, a bony fossa for the eye, is formed by the maxilla, frontal, ethmoid, sphenoid, and lacrimal bones. At its posterior surface is the *optic foramen*, an opening in the portion of the sphenoid that enters into the orbit. The optic foramen transmits the optic nerve in its passage from the eye to the brain.

The *mandible bone* forms the lower jaw, and presents also an *alveolar process* for the teeth. The shape of the mandible is determined in part by the teeth and varies also according to age (Fig. 118). The bone projects upward at its posterior extremity to

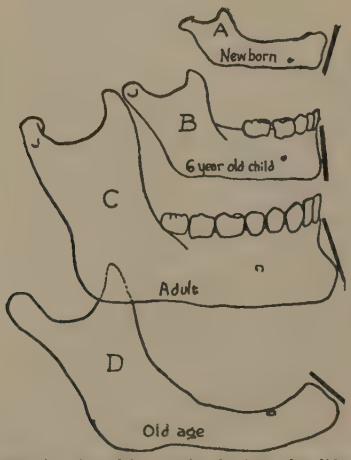

Fig. 118.—Changes in the chin angle during the life of the individual. (From Walter's "The Human Skeleton," published by The Macmillan Company.)

form the *ramus* of the jaw. This portion (Fig. 119) shows an articulating *condyle* for the mandibular fossa of the temporal bone and the *coronoid process* for the attachment of the temporal muscle. Just below the alveolar process of the first bicuspid and half-way between the upper and lower margins of the jaw is the *mental foramen* which passes terminal branches of the *inferior dental nerve*. This nerve supplies the lower teeth and may be anesthetized by injection at the site of the mental foramen. The nerve enters the mandible on its inner aspect near the center of the ramus at another foramen, the *inferior dental foramen*.

The *malar bones* are two small bones that make up the promontories of the cheeks. They give the lateral wall to the orbit and articulate with the zygomatic process of the temporal bones (Fig. 110).

The *lacrimal bones* are two small bones forming the inner wall of the orbit (Fig. 110).

The *nasal bones* comprise the upper part of the bridge of the nose, the lower part being formed from the nasal cartilages (Fig. 109).

The *vomer bone* is the ploughshare-like structure that articulates with the perpendicular plate of the ethmoid and the nasal cartilage to form the median septum of the nose (Fig. 115).

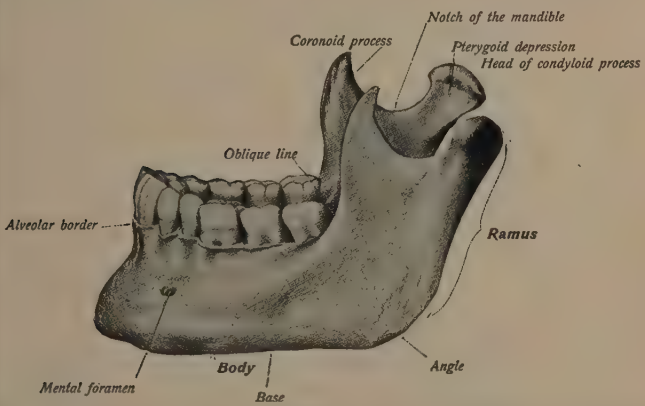

Fig. 119.—The mandible seen from the lateral surface (Sobotta and McMurrich).

The *palate bones* with the assistance of the palatine processes of the maxillæ complete the roof of the mouth (palate).

The *inferior turbinate bones* lie on the lateral wall of the nasal cavity forming the lowest of the three convolutions on that surface (Fig. 110).

The Skull as a Whole.—Study of the separate bones of the skull will reveal the nature of the structure that has developed to house the most elaborate portion of the nervous system and has modified its facial aspect to meet the changing needs of the upright organism (Fig. 111). The main features of the skull[3] may be summarized as follows:

1. *Cavities.*—The *cranial cavity* (Fig. 116) is the outstanding characteristic of the skull. Its size is determined by the growth of the brain. Its capacity varies from 1000 to 1800 c.c. Welcker submits the following means and extremes for white races:

	Capacity of the skull.		
	Mean c.c.	Maximum c.c.	Minimum c.c.
Males	1450	1790	1220
Females	1300	1550	1090

A megacephalic skull exceeds 1450 c.c.; a mesocephalic skull measures from 1350 to 1450 c.c., and a microcephalic skull shows below 1350 c.c.

Fig. 120.—External auditory meatus and tympanic cavity showing the three ear bones (Campbell).

The *cavity of the middle ear* in the temporal bone shows in the natural state three small bones—the *malleus*, *incus*, and *stapes* (Fig. 120). These assist in the transmission of sound waves to the internal ear. The internal ear is a minute spiral cavity housing the *cochlea* and a system of three bony canals in which lie the *semicircular canals*.

2. *Sinuses.*—There are five well-developed sinuses[1] between the inner and outer tables of bone: (*a*) The *frontal sinuses* (Fig. 121), one on either side just above the supra-orbital arch. They

open into the nasal cavity. (*b*) The *ethmoidal sinuses* which consist of the numerous spaces in the lateral masses of the ethmoid bone. These open into the nasal cavity. (*c*) The *sphenoidal sinus* in the body of the sphenoid. This opens into the nasopharynx. (*d*) The *maxillary sinus* or *antrum of Highmore* in the body of each maxilla. These open on the lateral walls of the nasal passages. (*e*) The *mastoid cells* are not typically a sinus, but they resemble the structure of a sinus. They differ in not draining readily and of the greater danger attendant upon infection.

Fig. 121.—Surface markings of the face: *A*, Supra-orbital notch; *B*, infra-orbital notch; *C*, mental foramen; *D*, alar cartilages; *E*, frontal sinus; *F*, nasal bones; *G*, lateral cartilages of nose; *H*, antrum of Highmore. (Campbell.)

In the infant the sinuses are not correspondingly well developed. At the end of the first year there is only a slight protuberance for the mastoid, which is not fully formed until the end of the third year. The sinuses in the maxilla, frontal, ethmoid, and sphenoid bones are very small and do not become readily infected in the infant as they do in the adult. On the other hand, infection in the middle ear is very common in infancy.

3. *Fossæ.*—There are several well-marked fossæ. The most conspicuous ones are the *orbital fossæ*, housing the eye structures. The *nasal fossæ* connect with the orbital fossæ by the lacrimal

canals. The *zygomatic fossæ* are the depressions under the zygomatic arch; the *temporal fossæ* are above the arch, and the *auditory fossæ* are the openings into the ear (Fig. 109).

4. *Processes.*—Each bone of the skull has some projections that are dignified by the name process, but the most significant ones are: (*a*) the *alveolar processes* of the maxilla and mandible; (*b*) the *zygoma*, that forms the arch from the temporal to the malar bone; (*c*) the *mastoid process*, that large projection downward behind the ear; (*d*) the *styloid process*, a sharp, dagger-like projection downward from the under part of the temporal bone, and (*e*) the *pterygoid process* from the wings of the sphenoid extending downward to the upper part of the pharynx, giving attachment to muscles of mastication, and the muscles of the palate and pharynx.

5. *Sutures.*—The sutures of the skull (Figs. 109, 110) are the lines of articulation of the different bones of the skull. The *sagittal suture* separates the parietal bones and divides the skull into right and left halves. The *coronal suture* is at right angle to the sagittal and separates the frontal and parietal bones. Occasionally the *metopic* suture persists. It divides the two halves of the frontal bone and coincides with the sagittal suture. The *lateral anteroposterior* suture runs from the junction between frontal and nasal bones in front backward to its junction with the lambdoidal suture. The *lambdoidal suture* begins at the mastoid process of the temporal bone and continues as the boundary line between the occipital and parietal bones. In this suture occur many wormian bones.

6. *Fontanels.*—In the formation of the skull bones ossification of the membranous plates takes place from centers of ossification situated in the central portion of the bones. This process is not complete at the time of birth of the human infant, and hence there occurs spaces between the converging bones. These spaces are called *fontanels*. In the human infant there are usually six fontanels present at birth (Figs. 122, 123, 124). The *anterior fontanel* lies at the junction of the frontal and parietal bones. Its anteroposterior diameter is about 2.5 cm., its transverse, about 2 cm. (1 by $\frac{7}{8}$ inch). The degree of tension of the membrane over the brain varies with the pressure within the cranium. Thus, it is tense in crying, in meningitis, and depressed in exhaustion states, as in bad diarrhea and collapse. This fontanel closes at about the eighteenth month. Normal variation is between the

fourteenth and twenty-second month. Late closure of this fontanel is seen in rickets and in untreated cretinism. It may remain open in cases of increased intracranial pressure, as in

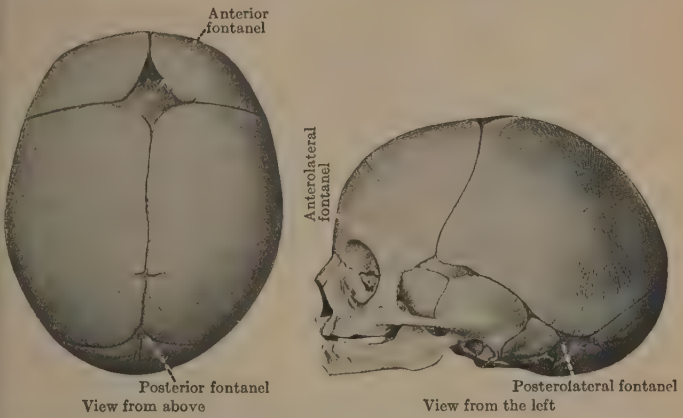

Figs. 122 and 123.—Skull of the newborn child showing fontanels and sutures (Sobotta and McMurrich).

hydrocephalus. Early closure of the fontanel (long before the eighteenth month) may be observed in cases of retarded brain growth, as in microcephalus.



Fig. 124.—Side view of skull showing molding (DeLee).

The *posterior fontanel* is smaller than the anterior one. It lies (Fig. 122) at the junction of the occipital and parietal bones. This closes usually by the second month.

The *anterolateral fontanels* are paired, lying at the junction of the frontal, parietal, temporal, and sphenoid bones (Fig. 123). They close usually by the third month. They are quite small.

The *posterolateral fontanels* are paired openings lying at the junction of the parietal, occipital, and temporal bones (Fig. 123). They decrease in size greatly by the second month, but do not close completely until the second year.

The presence of the fontanels in the structure of the skull is an adaptive mechanism for childbirth. During labor the bones of

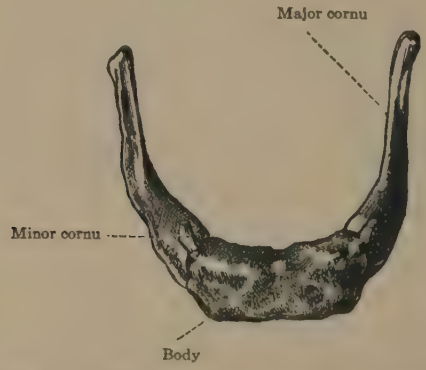

Fig. 125.— The hyoid bone, viewed from above (Toldt).

the skull override each other, allowing considerable compression and reduction in the diameters* of the skull (Fig. 124).

The **hyoid bone** lies at the root of the tongue and may be felt in the neck between the lower jaw and the thyroid cartilage (Adam's apple). The bone has a centrally placed portion, the *body*, and two projections or horns on each side, called the *great* and *small cornua* (Fig. 125).

* The shape of the head of the newborn infant varies widely, due to molding in the first stage of labor. Normal shape of the infant's head at full term is indicated in children born by cesarean section. In the unmolded head the occipitomental diameter is 13 cm. and the biparietal 10 cm. (average). With molding there may be a variation of several centimeters from these figures.

PRACTICAL EXERCISES

1. Examine the spine of a living subject. Have the back exposed. Ask the subject to bend the trunk forward (flexion of the trunk), allowing the arms to hang free. Mark with a skin pencil the tips of the spines that are prominent in such position. Then ask the subject to stand erect. Deviation from the normal vertical may show.

2. Observe a scoliotic spine and note in what segments the curve or curves exist.

3. Examine the temporal bone of the skull and note the relation existing between mastoid process and lateral sinus. How is the ear related to the mastoid?

4. Study the maxilla and observe the proximity of the alveoli to the antrum of Highmore. Would it be possible for an infection in a tooth "to work" upward and open into the antrum?

5. Note the mental foramina of the mandible. Accurately locate it in relation to the tooth above. What use is made of this foramen in dentistry?

6. Locate on the skull the different sinuses. Note the relation of these structures to the respiratory passages.

7. Locate on the skull the infra-orbital foramina and the supra-orbital foramina. What nerves do they transmit?

QUESTIONS

1. Study the articulations of the vertebral column and the ligamentous support. From such knowledge, what would be your judgment concerning displacement of the vertebræ? Would displacement readily occur?

2. What is a fontanel? At what age should the anterior fontanel close?

3. If the anterior fontanel closes early, of what may this be an indication? What may it mean if it closes late?

4. What are the differences between the spine of adult and child?

5. Why does rotation not occur in the lumbar region? What hinders rotation in the thoracic segment?

6. What are the normal movements of the spine?

7. Locate on the head the glabella, external occipital protuberance, mastoid process, zygoma.

8. What is "molding" of the head?

9. Describe the relation between mastoid cells and the lateral sinus.

10. Why does backward bending of the spine take place easily in the lumbar region?

REFERENCES FOR FURTHER STUDY

1. Bowen, W. H.: Applied Anatomy and Kinesiology, Lea & Febiger, Philadelphia, 1917.

2. Drew, Lillian: Individual Gymnastics, Lea & Febiger, Philadelphia, 1922.

3. Sobotta and McMurrich: Atlas and Text-book of Human Anatomy, three volumes, W. B. Saunders Co., Philadelphia, 1914.

Spalteholz, W.: Hand Atlas of Human Anatomy, three volumes, S. Hirzel, Leipsic, 1900. Two works with excellent illustrations, especially of the bones.

4. Coakley, C. G.: A Manual of Diseases of the Nose and Throat, Lea & Febiger, Philadelphia, 1914, pp. 17–25.

CHAPTER VI

THE SKELETON—THORAX, PELVIS, AND EXTREMITIES

I. The Thorax:
   1. Ribs.
   2. Costal Cartilages.
   3. Sternum.

II. The Shoulder-girdle:
   1. Clavicle.
   2. Scapula.

III. The Pelvic Girdle:
   1. The Os Innominatum.
   2. Ligaments of the Pelvis.
   3. Disease and Deformity of the Pelvis.

IV. The Upper Extremity:
   1. The Humerus.
   2. The Ulna.
   3. The Radius.
   4. The Carpus.
   5. The Metacarpus.
   6. The Phalanges.
   7. Ligaments of the Upper Extremity.
   8. Injuries of the Upper Extremity.

V. The Lower Extremity:
   1. The Femur.
   2. The Tibia.
   3. The Fibula.
   4. The Tarsus.
   5. The Metatarsus.
   6. The Phalanges.
   7. Ligaments of the Lower Extremity.
   8. Injury and Deformity of the Lower Extremity.

VI. Arches of the Foot:
   The Arch of the Child's Foot.

The Thorax.—The ribs are attached to the axial skeleton. They form the thorax, which gives support to the bones of the shoulder-girdle and upper extremity. The thorax is a bony, cage-like structure composed of twelve pairs of ribs, articulating posteriorly with the thoracic vertebræ, and attached anteriorly by means of *costal cartilages* to the breast bone, or *sternum* (Fig. 126). The thorax at birth* resembles the thoraces of quadrupeds

*The marked differences at birth and later are shown in Fig. 89. Note the cartilaginous sternum at birth, the later ossifications, and the sinking of the thorax, with increase in rib obliquity.

and is nearly round; in adult life it is an ellipse with a greater transverse diameter. The bony parts of the thorax are the ribs, costal cartilages, and sternum.

Ribs.—The ribs are curved bones, somewhat triangular in shape on cross-section. They attach to the thoracic vertebræ

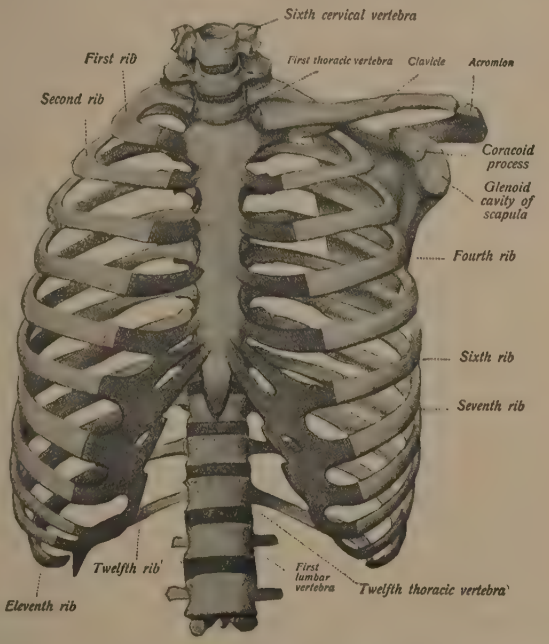

Fig. 126.—Anterior view of thorax and left shoulder-girdle (Sobotta and McMurrich).

by two articular facets, one with two contiguous bodies, the other with the transverse process (Fig. 127). These articulations permit movement of the rib around the axis of the two joints. This movement is slight in the first two ribs, but beginning with the third there follows a progressive increase in mobility so that the very lowest ribs have a considerable amplitude of movement. Strong ligaments bind the articulations with the vertebræ (Fig.

104); the costal cartilages form the union in front. The ribs most frequently broken are the sixth, seventh, and eighth.

Costal cartilages connect the first seven ribs directly with the sternum, the eighth, ninth, and tenth cartilages being successively joined to the cartilage of the rib above (Fig. 89). The costal cartilages favor movement of the ribs by interposing an elastic, flexible shaft between the rib and sternum. During childhood the cartilages are very soft, but after adult life they become harder, and in late adult life undergo a partial ossification. In

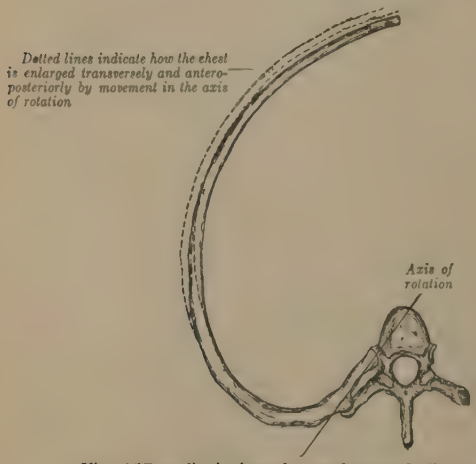
Dotted lines indicate how the chest is enlarged transversely and antero-posteriorly by movement in the axis of rotation
Axis of rotation

Fig. 127. Sixth dorsal vertebra and rib (Reichert).

childhood rickets frequently attack the costal cartilages, producing enlargements at their junction with the ribs. If the enlargements are bilateral and numerous, the name *rachitic rosary* is applied to the condition from its resemblance to a string of beads.

Sternum.—Developmentally the sternum arises as three separate parts, the upper or *manubrium*, the middle or *gladiolus*, and the lower or *ensiform cartilage*. At birth the sternum consists of several unossified pieces, the middle portion alone arising from four separate ossifications. Complete union does not occur until about nineteen years of age. This fact accounts for the variety in shape of this bone occasioned by posture, clothing, and nutrition during the years of childhood.

The **shoulder-girdle** consists of four bones, two clavicles (collar bones) and two scapulæ (shoulder-blades). The former articulate with the sternum; the latter lie embedded in the muscles of the back and gain an attachment to the thorax only through the clavicles. This girdle serves as an arrangement for articulating the bones of the upper extremity to the axial skeleton.

The *clavicle* (Fig. 128) is a double-curve bone with anterior and posterior borders, superior and inferior surfaces, sternal and acromial extremities. The sternoclavicular and acromioclavicular articulations are not very secure, due to the shape of the bones as they meet in their respective joints, and due also to the weakness of the investing ligaments. In the male the clavicle is more curved, heavier, rougher, and longer than in the female.

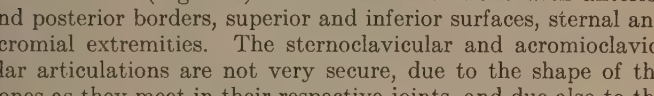

Fig. 128.—The left clavicle seen from above (Sobotta and McMurrich).

The *scapula* (Figs. 129, 130) is a triangular bone with three borders, *superior, vertebral,* and *axillary;* two surfaces, *anterior* and *posterior;* and three corners or angles, the *superior, inferior,* and *lateral.* The lateral angle is marked by an articulating surface, the *glenoid cavity,* above which is a depression, the *supraglenoid fossa,* and below which is also one, the *infraglenoid fossa.* A hooked projection, the *coracoid process,* juts out forward from the superior border close to the glenoid cavity. A heavy ridge, the *spine,* runs obliquely across the posterior surface. The tip of the spine is called the *acromion.* It articulates with the clavicle, forming the *acromioclavicular* joint. The spine on the posterior surface divides this area into two parts: the *supraspinous fossa* and the *infraspinous fossa.* The anterior surface is hollowed out in a saucer-like depression, the *subscapular fossa.*

The Pelvic Girdle.—The shoulder is not a complete girdle; it does not meet behind. The bones of the pelvis form a complete girdle; the *sacrum* filling in behind the space between the two *ossa innominata* (Fig. 131). On examination of the pelvis it is seen to be made of very oddly shaped bones, and yet certain definite

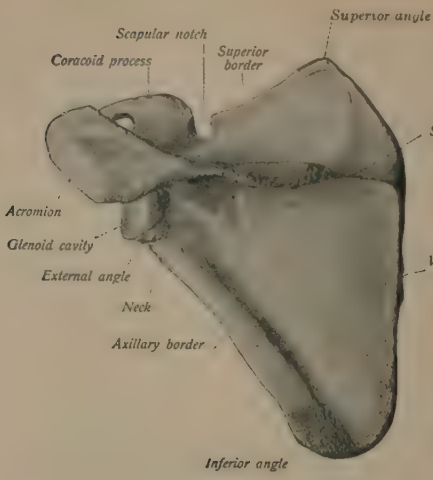

Fig. 129.—The posterior surface of the left scapula (Sobotta and McMurrich).

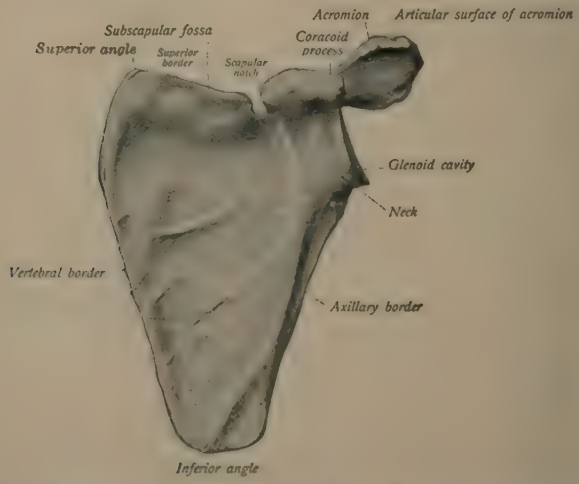

Fig. 130.—The anterior surface of the left scapula (Sobotta and McMurrich)

parts stand out clearly. There is a definite hollow or cavity formed by the union of the three bones; this is the *true pelvic cavity*, or *true pelvis*. Its upper limit is marked by the joint between the top of the sacrum and the last lumbar vertebra behind, and a definite ridge, the *iliopectineal line*, on the front part of the pubic bone. A plane passing through the lumbosacral joint and the iliopectineal line would also mark the inlet to the pelvic cavity and is called the *plane of the pelvic inlet*. When the individual stands erect the plane of the pelvic inlet is normally at

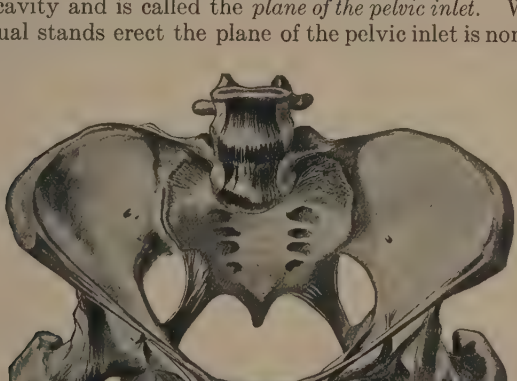

Fig. 131.—Normal female pelvis showing the complete girdle formed by sacrum and ossa innominata (DeLee).

an angle of 60 degrees with the horizon (Fig. 132). An increase in this angle with the accompanying lordosis or hollow back is very undesirable in standing or walking.[1] Above the plane of the pelvic inlet is the wide flaring part of the pelvis, known as the *false pelvis*.

In the adult the pelvic cavity holds the bladder, sigmoid, and the rectum, and, in the female, in addition, the uterus, tubes, and ovaries. In the infant the bladder is not a pelvic organ, but rides in the abdomen.*

* An abdominal tumor in infancy may be removed at times by passing a catheter.

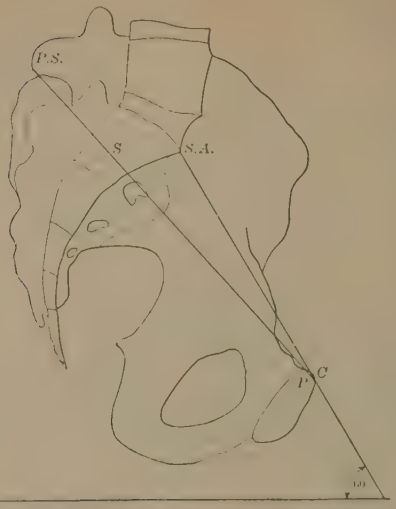

Fig. 132.—Sagittal section through pelvis showing angle of inclination: *P*, Symphysis pubis; *C*, pubic crest; *S*, sacrum; *S.A.*, sacral angle; *P.S.*, posterior spine. (Spalteholz.)

Fig. 133.—Development of the hip-bone showing the union of the three portions in the acetabulum (Testut).

There are marked sex differences. The female pelvis is broader and shorter. The pubic arch formed by the junction of the ossa innominata in front is much broader in the female. There are three diameters of the pelvis—the *anteroposterior*, the *transverse*, and the *oblique*. The left oblique in the female pelvis is about ½ cm. smaller at the inlet than the right. These diameters taken at the inlet, outlet, and half-way between show very clearly important sex differences:

Diameter.	Male.			Female.		
	Inlet, cm.	Intermediate, cm.	Outlet, cm.	Inlet, cm.	Intermediate, cm.	Outlet, cm.
Anteroposterior	10.25	11.5	8.25	11.50	13.50	11.5
Transverse	12.75	12.0	9.00	13.00	12.50	11.0
Oblique	12.00	11.5	10.25	12.50	13.25	11.5

The sacrum has been described in connection with the spine; there remains of the pelvis the ossa innominata.

The *os innominatum*, of such irregular shape that its lack of resemblance* to other objects secured this peculiar name for it, arises as three separate and distinct bones—the *os pubis*, *ilium*, and *ischium*. Even at six years the separation of these parts is well indicated. Complete union does not occur until about the seventeenth year (Fig. 133). The *os pubis* comprises the anterior part of the innominate bone and joins with its fellow of the opposite side to form the anterior joint of the pelvis, the *symphysis pubis*. The os pubis has a *body* and two limbs, known as *rami*. The descending ramus of the os pubis unites during adolescence with the ascending ramus of the ischium. The ascending ramus of the os pubis passes laterally to join with the ilium.

The *ischium* comprises the lower part of the innominate bone. In addition to the ascending ramus there are *body*, *tuberosity*, *spine*. The os pubis and ischium bound an opening in the os innominatum, the *obturator foramen*.

The *ilium* comprises the upper part of the innominate bone and corresponds largely with the wide flaring portions of the false pelvis. Its superior border is the *crest* of the ilium which has

* Os innominatum means bone having no name.

three lips—lateral, middle, and mesial. On its anterior aspect are two projections—the *anterior superior spine* and the *anterior inferior spine*. The mesial surface shows a smooth depression, the *iliac fossa;* and on its posterior mesial aspect is a rough surface in part articular for the *sacro-iliac joint*, and in part non-articular for the ligaments of that region. The lateral surface is quite smooth, showing three curved lines—*superior*, *middle*, and

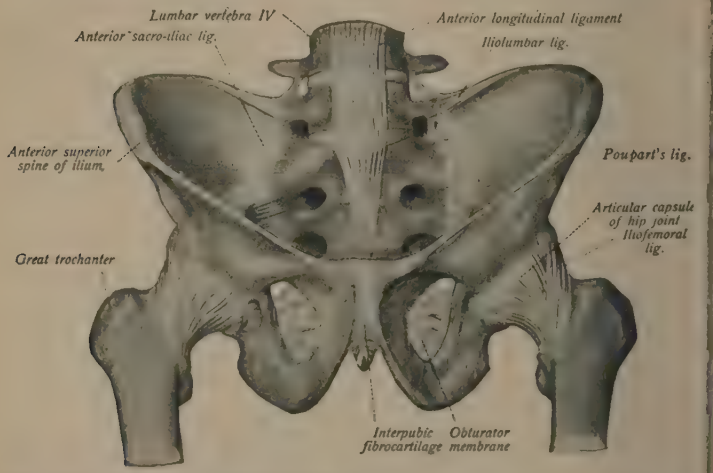

Fig. 134.—The male pelvis with its ligaments seen from in front (Sobotta and McMurrich).

inferior. All three bones enter into the formation of the articular cup, the *acetabulum*, on the lateral aspect of the os innominatum.

Ligaments of the Pelvis (Figs. 134, 135).—The symphysis pubis is held by a strong capsular ligament. The sacro-iliac joint is elaborately strengthened by numerous bands: (1) Strong ligaments run from the side of the sacrum and coccyx to the spine and tuberosity of the ischium, forming the *great sacrosciatic* and the *lesser sacrosciatic* ligaments; (2) the *posterior sacro-iliac* ligament fills in the space between sacrum and ilium; (3) in front of the joint strong bands pass from the fifth lumbar vertebra to the ilium, forming the *iliolumbar* ligament; and (4) also in front binding sacrum and ilium are the two *anterior sacro-iliac* liga-

ments. *Poupart's ligament* is a strong band running from the anterior superior spine of the ilium to the pubic spine.

Disease and Deformity of the Pelvis.—Rickets may produce deformity of the pelvis and interfere with its normal diameters. Sprain of the sacro-iliac joint is not uncommon.* This condition may result from lifting heavy weights, from a fall, or come on as a gradual development from improper posture in which the weight

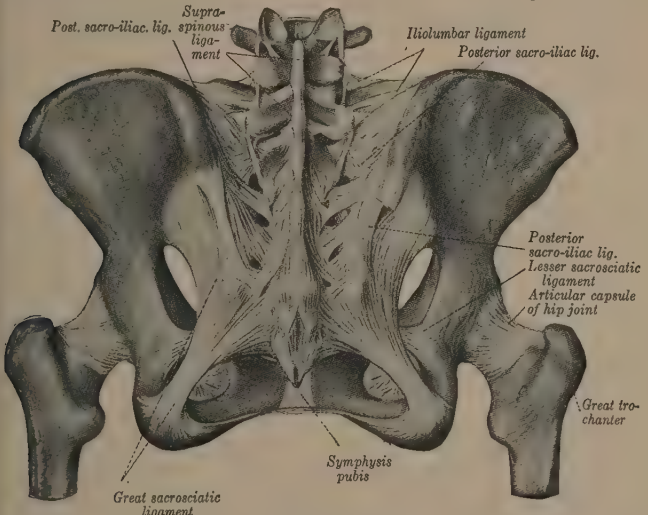

Fig. 135.—The female pelvis with its ligaments seen from behind (Sobotta and McMurrich).

of the abdomen is hung from the lumbar spine, causing a lordosis and an increase in the angle of inclination of the pelvis. The sacrococcygeal joint may be severely strained in labor and from falls on the buttocks. Disturbance in this region is marked by pain on rising from a sitting position, or the opposite, due to the pull of the gluteus maximus on its origin from this region. During pregnancy in the female all the joints of the pelvis undergo a relaxation which becomes more marked in the last month, and is the occasion for some discomfort in walking at this time.

* Goldthwait, J.: Boston Medical and Surgical Journal, March 9, 1905.

The Upper Extremity.*—Commonly the upper extremity is called the arm. In anatomy the term refers to the part above the elbow only. The part between the elbow and wrist is the forearm. Below the wrist are the hand and fingers. The bones of the upper extremity located as to parts are as follows:

Arm—humerus.
Forearm—ulna, radius.
Wrist—carpus (eight small bones).
Hand—metacarpus (five bones).
Fingers—phalanges (three to a digit, except the thumb, which has only two).

The *humerus* is a long bone† with shaft and two extremities (Fig. 136). The proximal end of the humerus comprises a *head* for articulation with the glenoid cavity of the scapula, and two tuberosities, the *greater* and *lesser*, between which is the *bicipital groove*. Between the head and tuberosities is a constricted portion, the *anatomic neck;* below the tuberosities is the *surgical neck*, so called because of the frequency of fracture at this point.

The distal end of the humerus shows an articulating surface, the *trochlea* and *capitellum*, for articulation with the ulna and radius respectively. Above these surfaces the bone swells out on the lateral and mesial aspects into projections—the *condyles*. Above the trochlea in front is a depression, the *coronoid fossa;* in a similar position behind is the *olecranon fossa*.

The shaft is somewhat triangular in shape, with anterior, mesial, and lateral borders, mesial, lateral, and posterior surfaces. These borders and surfaces are not particularly well marked, and for descriptive purposes the shaft may be viewed as regards its anterior and posterior aspects. There are no markings of note on the anterior. The posterior exhibits a well-defined groove running downward and laterally. This is the *musculospiral groove*. It shelters the musculospiral nerve. About half-way down the shaft on the lateral border is a rough projection, the *deltoid tuberosity*.

* Anthropology recognizes a relation between arm and forearm that is normal for certain races. Computing the length of the arm as 100, the forearm in the European equals 73, and in the negro 80. Excessive length of the forearm is an ape-like characteristic and a stigma of degeneration. This condition is frequently found in degenerates.

† The humerus and other long bones show plainly the provision for nourishment of bone. The periosteum gives many small vessels to the surface, but one special artery, the *nutrient artery*, enters the nutrient foramen to supply the interior.

The *ulna* is the mesial bone of the forearm (Fig. 137). It enters prominently into the formation of the elbow-joint and its

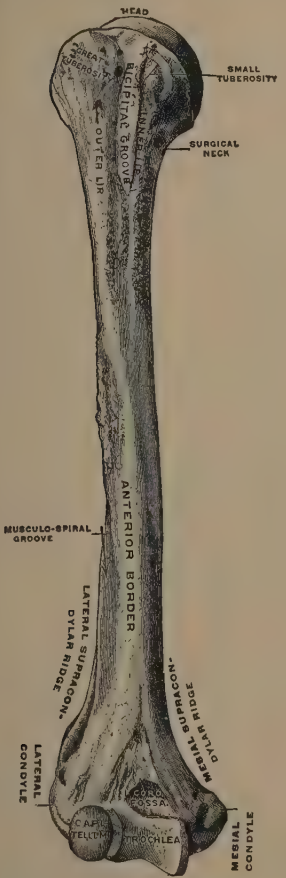

Fig. 136.—The right humerus, anterior view (Testut).

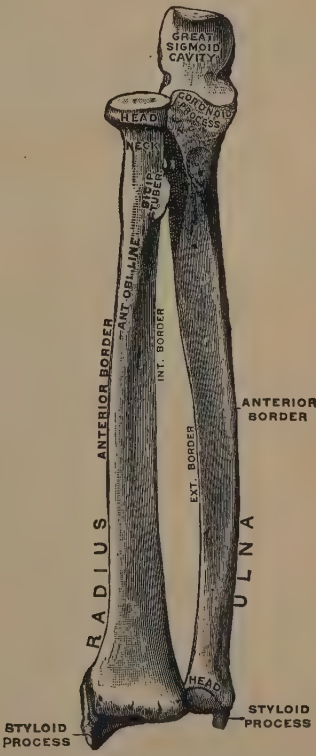

Fig. 137.—The bones of the right forearm, ventral view (Testut).

tip is the part felt as a prominence at this place. Its upper end, in addition to its articulation with the humerus, has a small

cup-like cavity for the rotating head of the radius. Just below the articulation is a rough projection on the anterior aspect, the *coronoid process*. Posteriorly at the upper end the *olecranon process* forms the base for the articulating part, as well as the extreme tip of the bone. The distal end of the ulna is marked by a long pointed process, the *styloid process*.

The *radius* is the lateral bone of the forearm. While the ulna is more prominent in the elbow articulation (Fig. 138), the radius alone articulates with the bones of the wrist. Its proximal end articulates with the humerus and the ulna by a smooth rounded disk-like extremity. Just below this on the anterior aspect is a

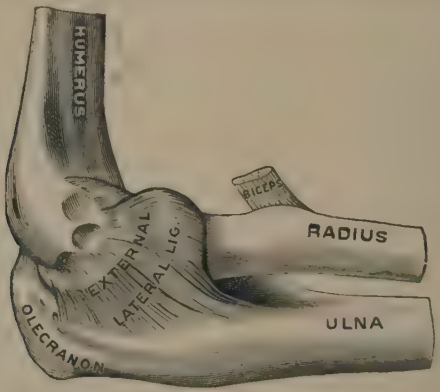

Fig. 138.—Elbow-joint, outer side (Testut).

rough projection, the *bicipital tuberosity*, for the insertion of the biceps muscle. The distal end is broad for the wrist articulation. It, too, shows a *styloid process*.

The *carpus*, or wrist, comprises eight small bones, called the carpal bones. They are arranged in two rows (Fig. 139) and are named as follows: *scaphoid*, *semilunar*, *cuneiform*, *pisiform*, *trapezium*, *trapezoid*, *os magnum*, and *unciform*.

The *metacarpus* comprises five small bones that form the framework for the hand (Fig. 139).

The *phalanges* correspond to the fingers; there are three for each of the four fingers and two for the thumb (Fig. 139).

The relation of the principal bones of the upper extremity to the surface is shown in Fig. 140.

Ligaments of the Upper Extremity.—The humerus is held in articulation with the scapula by a strong *capsular ligament* (Fig. 141). Within the sheath of this capsule are strong reinforcing fibers that support the capsule of the joint. The integrity of the joint is maintained also, as in all joints, by the action of the surrounding muscles. In the shoulder-joint, because of the shape

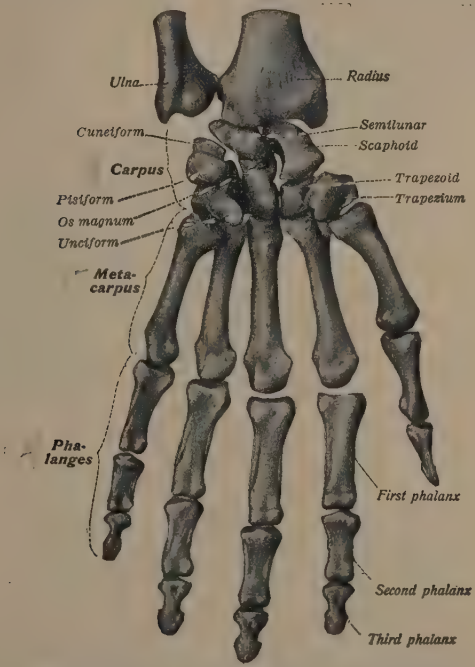

Fig. 139.—Bones of the left hand with lower ends of radius and ulna seen from the anterior surface (Sobotta and McMurrich).

of the joint, atmospheric pressure is a supporting factor. The joints of the elbow, wrist, and fingers (Figs. 142, 143) are maintained by ligaments that form complete investments for each articulation.

Injuries of the Upper Extremity.—In dislocation of the shoulder the head of the humerus breaks through the capsule of the joint.

Fig. 140.—Relations of the bones of the arm, posterior view (Campbell).

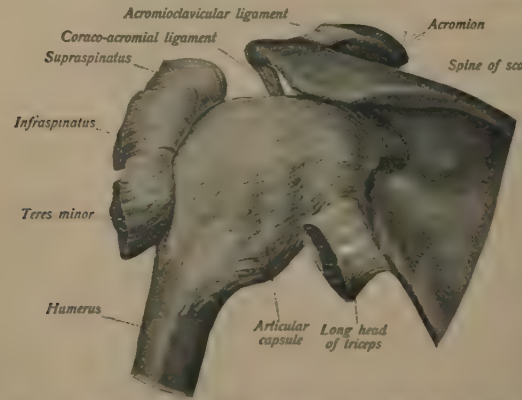

Fig. 141. The left shoulder-joint seen from behind, the long head of the triceps being cut and the terminal portions of the supraspinatus, infraspinatus, and teres minor muscles cut and turned outward (Sobotta and McMurrich).

This may take place in different places. When the dislocation is *reduced* and the head returned to the normal position in the joint, the hole in the capsule is repaired by connective-tissue fibers. This portion so restored is never as strong afterward as it was before the injury, accounting for the fact that a dislocation predisposes to future dislocations. Fracture of the bones of the upper extremity is not uncommon. A particularly distressing one is fracture of the distal end of the radius (Colles' fracture).

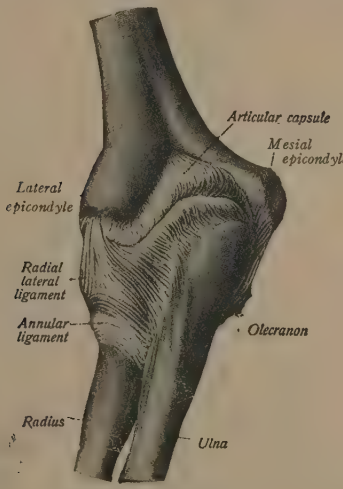

Fig. 142.—The left elbow-joint seen from behind and from the radial side (Sobotta and McMurrich).

The ligaments of the wrist are strong and are formed of numerous bands. The character of this support explains in part the deforming effects that result from allowing the hand to be retained in position of flexion in cases of paralysis of the muscles of the extensor side of the arm. Injuries to the nerves of the forearm or arm result at times in such paralysis.

The Lower Extremity.—Commonly the lower extremity is called the leg. In anatomy the term "leg" refers to the part between the knee and ankle; the part between the knee and hip is called thigh. Below the ankle are the foot and toes. The bones of the lower extremity, located as to parts, are as follows:

Thigh—femur.
Leg—tibia, fibula.
Ankle—tarsus (seven small bones).
Foot—metatarsus (five bones).
Toes—phalanges (three to a digit, except the great toe, which has only two).

The similarity of parts in the upper and lower extremities will be noted. There are marked functional differences. The oppos-

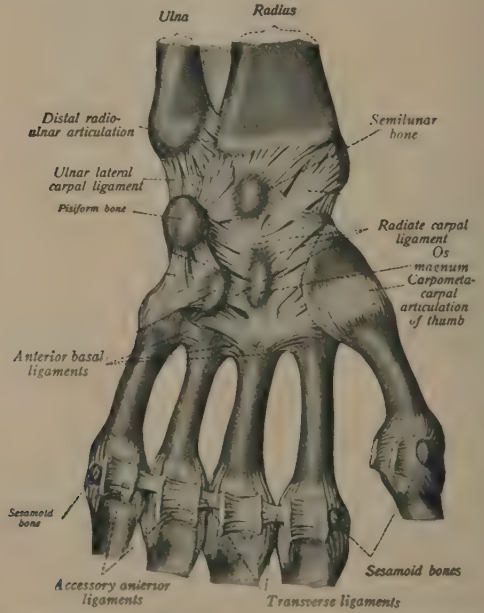

Fig. 143.—Articulations and ligaments of the hand seen from the anterior surface, the transverse carpal ligament having been removed (Sobotta and McMurrich).

able thumb renders the hand a most efficient instrument for grasping. Also the range of movement in the wrist is much greater than in the ankle (Figs. 95, 96). Marked differences occur in the foot. In the hand the phalanges combined are as long as the metacarpals; in the foot the phalanges are very short and the metatarsals much longer.

The *femur* (Fig. 144) is a long bone with a shaft and two extremities. The proximal end of the femur comprises a smooth articular *head* for articulation with the acetabulum; two *trochanters,* the *greater* and the *lesser;* and two lines between the two

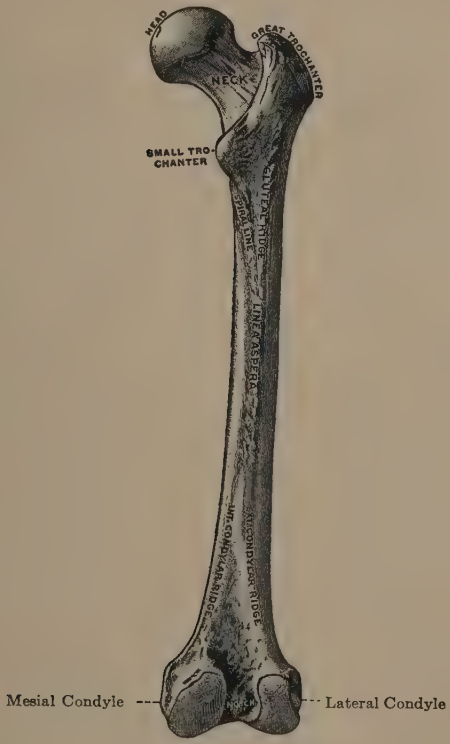

Fig. 144.—The right femur, posterior view (Testut).

trochanters, in front, the *anterior intertrochanteric line,* and behind, the *posterior intertrochanteric line.* Between the head and trochanters is a constricted portion, the *neck.*

The distal end of the femur has a smooth articular surface for articulation with the tibia, forming the knee-joint, and two well-

marked projections, the *mesial* and *lateral condyles*. In front the articular surface runs upward between the swellings of the condyles and makes a smooth area for the patella; behind, the articular surface is separated by the *intercondylar notch* the site of ligamentous attachments of the knee-joint.

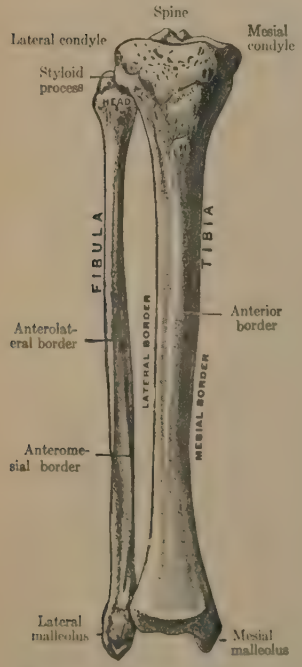

Fig. 145. The right tibia and fibula in their normal relations, anterior view. (From Gerrish, modified from Testut.)

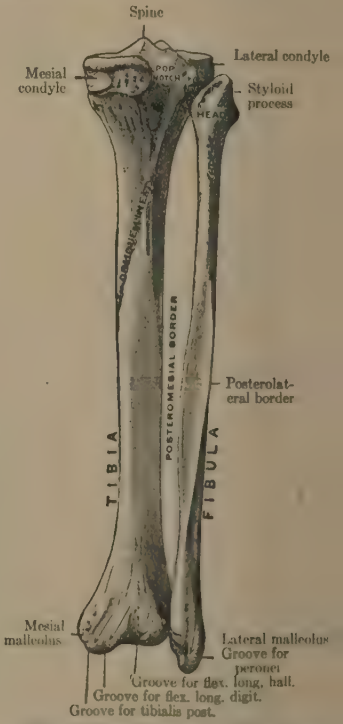

Fig. 146. The right tibia and fibula in their normal relations, posterior view (Testut).

The shaft is somewhat triangular in shape, with mesial, lateral, and posterior borders, anterior, mesial, and lateral surfaces. The posterior border is especially well defined and is known as the *linea aspera*. The inner prolongation of the linea aspera below

ends in the *adductor tubercle*, a sharp projection on the mesial condyle that gives attachment to the adductor magnus muscle. The linea aspera has mesial and lateral lips and a variety of markings that are represented by the letter H with four marks above and one below the bar, indicating the muscular attachments.

The *tibia* (Figs. 145, 146) is the mesial and larger bone of the leg. The head or proximal part shows an articular surface above, marked by a sharp projection, the *spine*. In front, where the shaft and head join, is the *tuberosity of the tibia*. The distal end of the tibia projects downward on its mesial side to make the inner ankle bone, the *mesial malleolus*. At this same end is the articular surface for the astragalus, forming the ankle-joint. The shaft is triangular, with an anterior border, well defined and known commonly as the shin, and the mesial and lateral borders. The surfaces are the mesial, which is subcutaneous throughout its whole length, lateral and posterior. The posterior surface is marked by a ridge on its upper part near the head, the *oblique line*, that runs downward and mesially.

Fig. 147.—Notice the arteries *A*, *B*, on the plantar surface of the arch (Campbell).

The *fibula* lies beside the tibia, articulating above with the tibial head, but not entering into the knee-joint. Below it forms the outer ankle bone, the *lateral malleolus*, and shares with the tibia in boxing the astragalus between the two malleoli.

The Tarsus.—The bones of the ankle are larger than the carpal bones of the wrist and are arranged in the foot to form with the metatarsals a distinct arch, the *longitudinal arch* (Figs. 147, 152). There are seven tarsal bones, as follows: *astragalus*, *os calcis*, *scaphoid*, *cuboid*, *mesial cuneiform*, *middle cuneiform*, and *lateral cuneiform*.

The astragalus articulates with the tibia and fibula, riding at the top of the long arch of the foot. Below is the large os calcis,

the heel bone and mesially in front of the astragalus is the scaphoid (Fig. 148) and laterally in front is the cuboid. In

Fig. 148. — Bones of the right foot, plantar surface, showing transverse arch (Spalteholz).

front of the scaphoid are the three cuneiform bones. It will be seen that the cuneiform bones and the cuboid form the articulating line for the metatarsals.

Fig. 149.—Relations of the surface markings to the bones of the lower extremity, anterior view: *A*, Anterior superior spine; *B*, great trochanter; *C*, mesial condyle; *D*, head of fibula; *E*, mesial malleolus; *F*, base of fifth metatarsal bone. (Campbell.)

Fig. 150.—Relation of the surface markings to the bones of the lower extremity, posterior view. *A*, Posterior superior spine; *B*, tuberosity of the ischium; *C*, the gluteal fold; *D*, tendon of the biceps muscle; *E*, adductor tubercle; *F*, calf muscles; *G*, lateral malleolus; *H*, mesial malleolus. (Campbell.)

The five *metatarsals* comprise the forepart of the foot arching from the lateral to the mesial border to shape the *transverse* or *mediotarsal arch* (Fig. 148).

The *phalanges* attach to the metatarsals, three each to the lateral four and two to the mesial one.*

The relation of the bones of the lower extremity to the surface is shown in Figs. 149, 150.

Ligaments of the Lower Extremity.—The hip-joint is maintained by the *round ligament*, a weak band of tissue running from the center of the articular head to a notch in the floor of the acetabulum, and the *capsular ligament*, a heavy covering that invests the entire joint. The front aspect of the capsular liga-

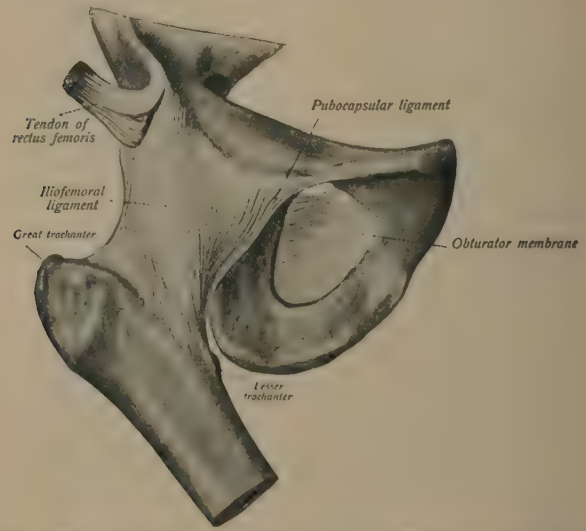

Fig. 151.—The right hip-joint seen from in front (Sobotta and McMurrich).

ment shows an exceedingly strong band of fibers much resembling an inverted Y, and known as the *iliofemoral or Y ligament* (Fig. 151).

The knee-joint, like the hip-, has internal and external supporting bands. Internally in the knee-joint are the *crucial ligaments* which run from the spine of the tibia to the intercondylar notch of the femur. These are very strong bands. Outside the

* Degenerate types may show an opposable big toe. This condition never results from adaptation. Degenerates possessing this prehensile ability can perform certain work with their feet, such as knitting, picking up objects, etc.

joint is invested by the capsular ligament strengthened on the mesial and lateral sides by ligaments, and behind by the posterior ligament. The knee-joint is unusual because of the relation of the patella or knee-cap to the capsular joint. The patella lies embedded in the tendon of the quadriceps extensor femoris muscle, which passes in front of the joint to reach the tuberosity of the

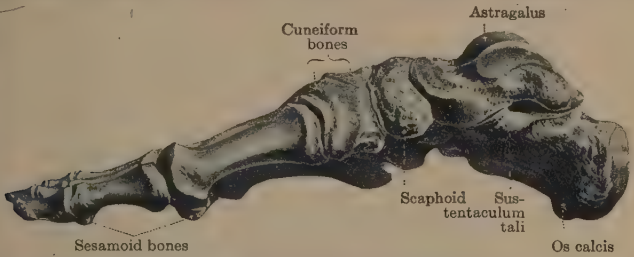

Fig. 152.—Bones of the right foot showing longitudinal arch (Spalteholz).

tibia. The tendon and capsular ligament are intimately bound together and the posterior surface of the patella presents an articular surface in the cavity of the joint articulating with the femur. The knee-joint is unusual in another respect. On the articular head of the tibia lie two *semilunar cartilages* that deepen

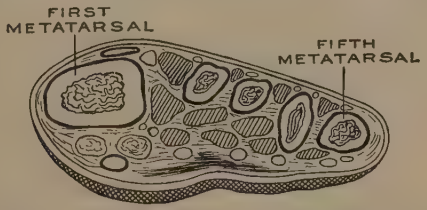

Fig. 153.—Tendons, muscles, and ligaments maintain the transverse arch. Section of right foot through metatarsal bones.

the tibial articulation, giving a better surface for the femur. The cartilages are thick at the periphery, where they are attached, but centrally they are thin and free. The bursæ of the joint are particularly large and numerous.

The ankle-joint exhibits a *capsular ligament* strengthened on each side by strong ligaments. Sprain of the ankle involves one or both of these ligaments. The important ligaments of the

arches of the foot will be described in connection with a discussion of the foot arches.

Injury and Deformity of the Lower Extremity.—Deformity of the lower extremity is not uncommon. Both knock-knee (genu

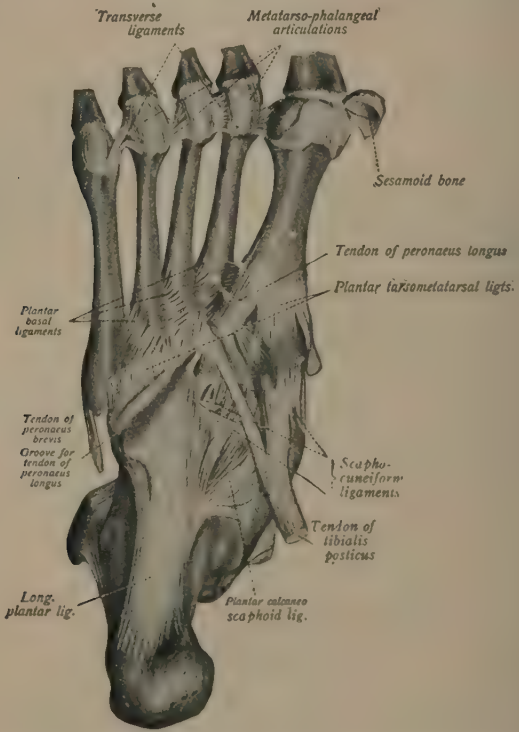

Fig. 154.—The ligaments of the foot seen from the plantar surface (Sobotta and McMurrich).

valgum) and bow-leg (genu varum) occur; both are most always caused by rickets, although infantile paralysis is at times the causative agent for the former.

Dislocations of the hip and the patella are the common displacements in the joints; also the cartilages of the knee-joint may be dislodged from their position. Dislocation of the other

joints does not often occur. Fracture of the bones of the lower extremity is not uncommon.

The space between tibia and fibula is occupied by a thin partition of connective tissue called the *interosseous membrane.*

Arches of the Foot.—There are two arches (Figs. 152, 153) of the foot:* one running the long way of the foot, the *longitudinal arch,* and the other forming across the foot in the metartarsal region, the transverse or *mediotarsal arch.*

The *longitudinal arch* (Fig. 152), formed by the position of the tarsal bones, is marked on the mesial aspect of the foot and absent on the lateral. This position of the arch indicates† that the foot

Fig. 155.—*x*-Ray of woman's foot in high heel showing weight thrown forward on the transverse arch (Harriet Wilde in "The Nation's Health").

s constructed to carry the superimposed weight on the outer and ıot the inner side of the foot. The long arch is maintained by

* While the arch may be broken down and destroyed, an acquired pathoogic condition, its absence may exist as a racial deformity, *e. g.,* Australian ıatives and American negroes. Flat-foot is more prevalent among short aces. It is more frequently found in heavy persons and "all physical types ·f men who become heavy may gain flat-foot." (The Medical Department Jnited States Army in the World War, vol. xv, Statistics, p. 370, Washngton, D. C., 1921.)

† Other anatomic facts indicate that the foot is constructed to carry the veight on its lateral side involving the straight foot position. The os calcis r heel bone is placed to the lateral side in its articulation with the astragalus; he tendons from the calf muscles pass to the bottom of the foot on the mesial spect of the joint, indicating the support that is brought to bear to keep the nesial side up and the weight outside.

numerous ligaments (Fig. 154): (1) *capsular ligaments* that invest each joint of the tarsus; (2) *calcaneocuboid ligaments*, also called the *long* and *short* plantars, running from the under surface of the os calcis to the cuboid and the three outer metatarsals; (3) the *calcaneoscaphoid* ligament, passing from a projection, the *sustentaculum tali*,* on the mesial aspect of the os calcis to the under surface of the scaphoid; and (4) the *scaphocuneiform* ligaments, running from the scaphoid to the cuneiform bones, their fibers intimately joined with the tendon of the tibialis posticus.

A *B*

Fig. 156.—Print of a normal foot sole (*A*) and of a flat-foot sole (*B*) (Albert).

The *transverse arch* (Fig. 153) of the foot is supported by the first and fourth metatarsals, between which are ligaments, muscles, and fascia. The fifth metatarsal does not enter much into the formation of the arch. The wearing of improper shoes[2] is frequently the cause of trouble with the arch in this region (Fig. 155).

The Arch of the Child's Foot.—The sole of the infant's foot does not appear to have an arch, but this appearance is only apparent and not real because the sole of the infant's foot is heavily padded with fat which obscures the arch that is so evident about the third and fourth years. Accurate measurements[3] show that infants' feet are arched in the same way that the feet of adults are, and, further, that proportionately the arch in infants is about as high as in the adult.

PRACTICAL EXERCISES

1. Place the index-finger on the sternoclavicular joint and note the movement that occurs there on elevation of the shoulder.

2. In fracture of the clavicle what sort of bandage would hold the broken parts in good position?

3. Try standing in such fashion to increase the angle of inclination of the pelvis. To decrease the angle. Note what happens to the abdominal wall and lumbar spine in each instance.

4. Compare the range of flexion and extension possible in ankle- and wrist-joints. (See Figs. 95, 96.)

5. If available, study formalin preparation of joints of the arms and legs. Note particularly the capsular, the iliofemoral, and crucial ligaments.

* The position of the sustentaculum is very important, as the ligament that runs from this projection is the first one to be effected in weakness of the longitudinal arch. Beginning weakness of the longitudinal arch is marked by tenderness over the sustentaculum tali, the point of attachment of the calcaneoscaphoid ligament. Eliciting of tenderness over the tali is an important early sign of arch disturbance.

6. Place a subject prone on a table. Fasten with a strap or hold securely the pelvis to the table. Note whether hyperextension of the hip-joint is possible. When standing on one foot what causes the apparent hyperextension when the lower extremity is carried backward?

7. Measure the length of the lower extremities. The limbs should be placed parallel and in line with the trunk. The tape should be held at the same relative position at the top of the anterior superior spine of the ilium and carried downward to the lateral malleolus. Any difference in length between the two extremities should be indicated.

8. Difference in length of the lower extremities may be determined in another way. A posterior view of the body will show in the sacral region the rhomboid described by Michaelis. This is a diamond-shaped area formed by the dimples of the posterior spines of the ilia, the margins of the gluteal muscles, and the groove of the spine (see Fig. 108, D). When the legs are of even length, the vertical axis through the rhomboid will be parallel with the long axis of the body.

9. Wet the soles of the feet and stand on a wooden floor, or place lampblack on the soles and stand on white paper. Notice the longitudinal arches. What imprint should a normal arch give? (Fig. 156.)

10. The prepatellar bursa is frequently injured and inflamed. Locate the bursa and explain why the condition is called "housemaid's knee."

11. Locate the nutrient foramina in the humerus, femur, tibia, and radius.

12. Locate linea aspera, acetabulum, greater tuberosity, symphysis pubis, and olecranon.

QUESTIONS

1. What deformity of the costal cartilages is observed in rickets? How may rickets be prevented?

2. Name the important parts of the scapula. Locate the acromion, inferior angle, spine, vertebral border, and superior angle.

3. Define the plane of the pelvic inlet.

4. What are the chief differences between the male and female pelvis?

5. Describe the ligaments holding the sacrum and os innominata together.

6. Name the bones of the upper and lower extremities.

7. Where is the surgical neck of the humerus? Why is it so called?

8. Why does fracture of the humerus at times cause a paralysis of the extensor muscles of the forearm?

9. What is the difference between a dislocation and a fracture?

10. What is the sustentaculum tali?

11. Describe the anatomy of the foot that is important in determining the proper use of the foot.

12. At what age should a child wear a shoe with arch construction?

13. Give one reason why Colles' fracture is serious.

REFERENCES FOR FURTHER STUDY

1. Bowen, W. H.: Applied Anatomy and Kinesiology, Lea & Febiger, Philadelphia, 1917, pp. 227–232.

2. Wilde, H.: The Foot Factor in the Future of Women, The Nation's Health, September, 1922, pp. 520–524.

3. Dane, J.: Further Studies Upon the Arch of the Foot in Infancy and Childhood, Trans. Amer. Orthopedic Assoc., ix, 1899, p. 54.

CHAPTER VII

THE SKELETAL MUSCLES

I. Development of the Muscular System.
II. The Attachment of Muscles:
    1. Origin and Insertion.
    2. Mode of Attachment.
    3. Tendon Sheaths.
III. Blood-vessels and Lymphatics.
IV. Contraction of Muscle:
    1. Chemistry of Muscle.
    2. Fatigue of Muscle.
    3. Factors in Contraction.
V. Nerves to the Muscles.
VI. The Action of Muscles.
VII. The Names of Muscles.
VIII. Muscles of the Abdominal Wall:
    The Inguinal Canal and Hernia.
IX. Muscles of the Back.
X. Muscles of the Thorax:
    Openings in the Diaphragm.
XI. Muscles of the Chest.
XII. Muscles of the Neck:
    Triangles of the Neck.
XIII. Muscles of the Head and Face.
XIV. Muscles of the Scapula.
XV. Muscles of the Arm.
XVI. Muscles of the Forearm and Hand.
XVII. Classification of the Muscles of the Trunk and Upper Extremity.
XVIII. Muscles of the Pelvis:
    1. Muscles of the Pelvic Floor.
    2. Muscles of the Hip-joint.
XIX. Muscles of the Thigh.
XX. Muscles of the Leg.
XXI. Muscles of the Foot.
XXII. Classification of the Muscles of the Hip and Lower Extremity.
XXIII. The Measurement of Muscular Strength.
XXIV. Norms for Amplitude of Voluntary Movement.
XXV. Motor Points and Reaction of Degeneration.

Development of the Muscular System.—The muscles of the body, with the exception of the muscles of the hairs and the ciliary muscles of the eye, arise from the middle one of the embryonic layers—the mesoderm. At an early period in develop-

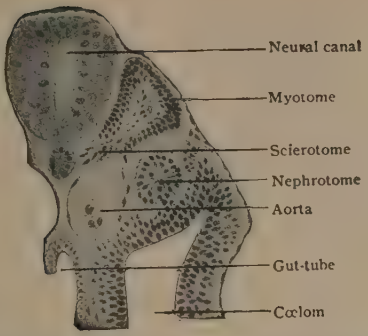

Fig. 157.—Transverse section of human embryo of about twenty-one days, showing differentiation of somite; × 90 (Kollmann).

Fig. 158.—Human embryo of about twenty-eight days showing grouping of myotomes (diagrammatic) into anterior and posterior masses (His).

ment the masses lateral to the developing spinal cord enlarge and transverse constrictions appear, forming the body somites (Fig. 28). Subsequently each somite breaks up (Fig. 157) into an inner portion, the *sclerotome*, which later forms the bones of the vertebral column, and an upper part, the *myotome*, which gives rise to the musculature of the body. The growth of the myotome proceeds ventrally to invest the trunk and to form the muscles for the arms and legs (Fig. 158). These myotomes correspond with similar structures in all vertebrates and even with non-vertebrates. It should be understood that the terms myotome and sclerotome are given to groups of cells that have differentiated. They are not special parts or organs but merely characteristic cell groups that are named for convenience. The myotomes producing the muscles of the trunk are

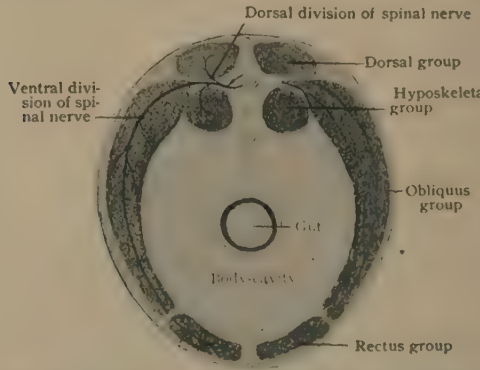

Fig. 159.—Diagrammatic cross-section of body showing primary groups of trunk muscles.

the oldest racially. The extension of their cellular masses into the arms, legs, hands, and feet is relatively recent in animal life.[1] The smooth or involuntary muscles arising from the mesoderm separate from the skeletal myotomes and become attached to the special parts which they serve. Thus, mesodermic elements go to make up the muscular walls of the digestive tract, the walls of the arteries and veins, the muscular parts in the respiratory and excretory systems. A diagram of a cross-section of the trunk (Fig. 159) gives the beginnings of the body muscula-

ture and illustrates the firm wall of the torso formed by the trunk muscles.

The Attachment of Muscles.—The smooth or involuntary muscle of the body is arranged as a tube in most portions of the body. This tubular arrangement shows usually two and at times three layers of muscle tissue. Not attached to any particular structure, but comprising the wall of the part concerned, the smooth musculature differs markedly from the striated type.

The striated, voluntary, or skeletal muscles forming the mass of the body are built upon the skeleton; they take numerous attachments to the bones of the different parts, and occasionally connect through an aponeurosis with the muscle of the opposite side without the intervention of bone.

Origin and Insertion.—Attachments of striated muscle may be classified according to the fixed or movable, central or peripheral part. The origin of a muscle is more fixed as contrasted with the insertion which is the more movable portion. As a rule the origin is central and the insertion is peripheral.

Mode of Attachment.—Some muscles attach directly to the periosteum of the bone, others begin their origin by a tendinous slip. All muscles end by insertions that have either tendon or aponeurosis as the terminal portion. A muscle may have two tendons of origin, as the biceps of the arm and the biceps of the thigh. Each muscle is invested with fascia that sends its prolongations into the muscle between the bundles of tissue. Such fascia is spoken of as the fascia of the particular muscle covered, *e. g.*, the fascia of the deltoid, the fascia of the triceps, etc. Many muscles will show attachment to the fascia that covers them. These varieties of attachment only illustrate the simple fact that muscle tissue attaches to parts that will serve as a base from which it may contract and produce motion. Whether the form of attachment is tendon, fascia, or aponeurosis matters very little. All three structures used for purposes of attachment are composed of the same kind of tissue; they vary only in the amount and organization of this fibrous tissue. For illustrative purposes they may be likened to well-known objects in which fascia may be said to resemble a fine material, such as crêpe de chine, aponeurosis may be compared with a piece of heavy canvas, and tendon may be likened to a small rope in its shape, size, and strength. Tendons should not be confused with ligaments, although they are composed of similar tissue. Ligaments

bind bones together to form joints; tendons attach muscles to bone.

Tendon Sheaths.—Where tendons run in grooves of bones, layers of strong, fibrous, connective tissue often convert the grooves into canals by connecting the two margins of the groove

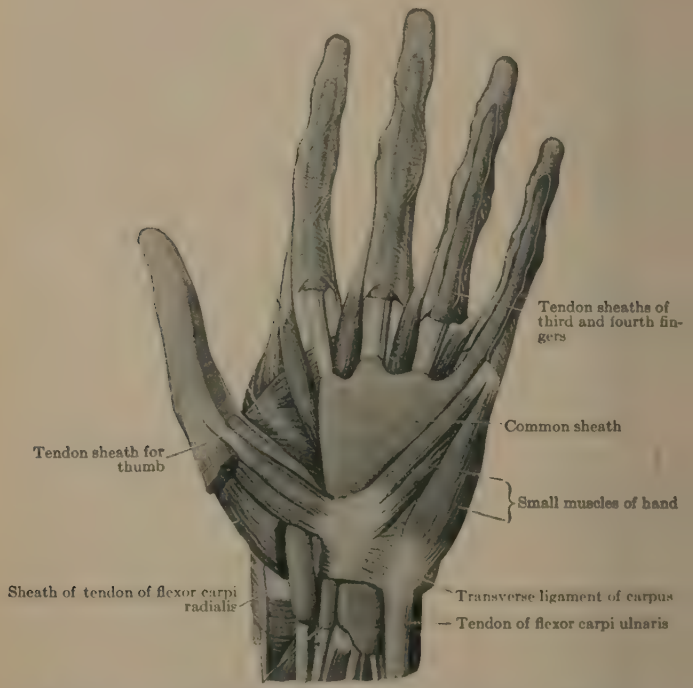
Tendon sheaths of third and fourth fingers
Common sheath
Tendon sheath for thumb
Small muscles of hand
Sheath of tendon of flexor carpi radialis
Transverse ligament of carpus
Tendon of flexor carpi ulnaris

Fig. 160.—Tendon sheaths of the hand, anterior surface. Note the continuity of sheath of little finger with the common sheath of the other three tendons (Sobotta and McMurrich).

over the tendon. Such structures are *tendon sheaths* (Fig. 160). They are lined with synovial membrane and contain a synovial fluid. From the floor of the groove bands of loose tissue pass up to connect with the tendon (Fig. 161). They serve to carry

a few blood-vessels to the tendon, a structure of very small vascularity.

Blood-vessels and Lymphatics.—Muscles are supplied by vessels that penetrate the muscle bundles, breaking up into capillaries to course between the separate cells (Fig. 68). The tissue spaces between the cells serve as exchange places for the substances of the blood and lymph. Nourishment is here given to the muscle cells and waste products are removed by the lymph and venous circulation. Contraction of muscle facilitates the exchange, and although the work done by the muscle results in more waste being produced, the general effect of the activity, if it has not been too vigorous, is to improve the character of the fluid in the spaces around the individual muscle-cells.

Contraction of Muscle.—In the brief statement of the function of muscular tissue on p. 76 some of the elementary facts of muscular action were noted. In *smooth* muscle the character, arrange-

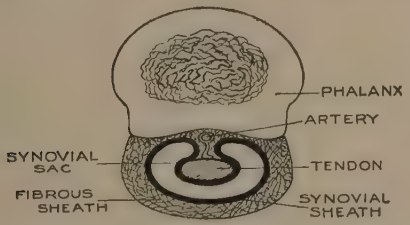

Fig. 161.—Diagram of cross-section of phalanx, tendon, and sheath showing vascular supply to tendon.

ment, and innervation of the cells (see Fig. 9) produce a contraction that passes as a slow and sluggish wave of movement through the part. This is the characteristic contraction of smooth muscle and is seen in the gall-bladder, esophagus, stomach, intestines, ureters, bladder, uterus, blood-vessels, bronchial tubes, and in other structures.

In *striated* muscle the individual cells show a characteristic striation due to the arrangement of the material within the cell. This gives an effect of dark and light bands, the nature of which is offered as an explanation of the phenomenon of contraction. In contraction the muscle grows shorter and thicker, there is a shift of material, and the dark and light bands alter their appearance.

The exact nature of this change is not known, but some important facts have been worked out lately.

Chemistry of Muscle.—In the contraction of muscle *glycogen* (a substance built up in the body from the digestion of starches and sugars) in the muscle decreases, *lactic acid* appears in amount equivalent to the glycogen lost, *carbon dioxid* is given off, heat is produced in proportion to the lactic acid formed, and the *acid reaction* (expressed as hydrogen-ion concentration) rises.

The above are the only chemical changes known definitely.* The glycogen stored in the muscle is used for the production of heat and is replenished from the store in the liver, which, in turn, is accumulated by the digestion of carbohydrates. The lactic acid is formed as a product from the oxidation of glycogen. The carbon dioxid that is given off is preformed in the muscle during the resting stage. The heat produced by the chemical changes in the muscle bears some responsibility for the shifting of the contractile material and is related intimately to the speed of muscular contraction. The acid reaction cannot be demonstrated after ordinary muscular activity, but only after extreme fatigue.

Fatigue of Muscle.—During muscular contraction the glycogen stored in the muscle is burned to produce heat, which is the active cause of the contractile changes in the muscle. As a result of this oxidation there is produced fatigue substances derived from the glycogen. These substances are mainly lactic acid and carbon dioxid. At first they increase the irritability of the muscle, enabling it to do more work, as is shown by the success attendant with "warming up" in all athletic exercises. This initial increase in irritability is soon lost, however, and excessive amounts of fatigue[2] substances act to decrease the irritability and the contractility (Fig. 162).

After exercise rest is necessary to give the muscles opportunity to replenish their supply of glycogen and to be relieved of the waste accumulated in the tissue spaces. Massage is very helpful in assisting the removal of waste. Rest and sleep are, however, the two most important remedies for fatigue.

The soreness in muscles after unusual exercise, or after prolonged exercise is due in the former case to little tears in the muscle-

* Hill, A. V., Muscular Activity (The Herter Lectures). Williams and Wilkins Co., Baltimore, 1926, p. 58.

fibers, and in the latter to an accumulation of waste materials. When the soreness is due to tears heat should be applied, but the part shoud not be rubbed; when it results from fatigue substances heat and rubbing are both indicated.

Factors in Contraction.—Experimentally a number of responses of muscle may be shown that give a clue to the influences that vary the character of muscle response. First is the strength of the stimulus. In general the height of the contraction is proportional to the strength of the stimulus.



Fig. 162.—Normal fatigue curve of the flexors of the middle finger of right hand. Weight 3 kilograms, contractions at intervals of two seconds (Maggiora).

Second is the duration of the stimulus. Stimuli of moderate duration produce the highest contractions. Third is the weight of load. The height of muscle contraction decreases with increase of load. Some load is necessary, however, to get the best response.

Fourth is the influence of temperature. Warmth increases the strength and speed of muscle contraction. For men the most favorable body temperature is 37° C.

Nerves to the Muscles.—Muscles are dependent upon nerve excitation for every motor response in the living animal. Motor nerves to the muscles are distributed to the muscle-cells as delicate filaments (effectors) at the end of nerves. These effectors, also called motor plates, are in contact with the sheath covering the muscle-cell (Fig. 72).

The Action of Muscles.—Muscle is contractile tissue, and its chief action is the bringing of origin and insertion nearer each

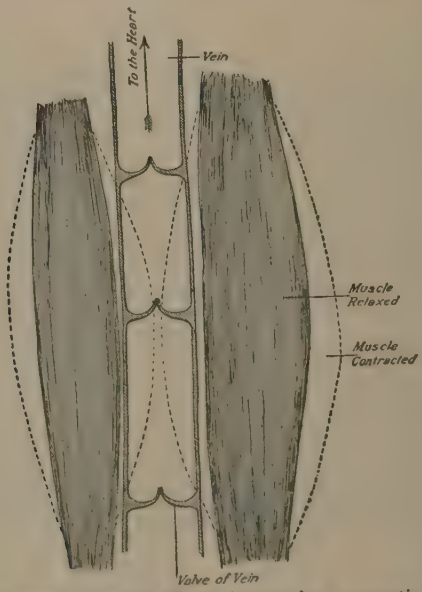

Fig. 163.—Diagram showing effect of muscular contraction upon venous circulation. The valves prevent the blood from flowing in two directions; it can only flow toward the heart. (From Williams' "Healthful Living," published by The Macmillan Company.)

other. It has accessory functions in the body, *e. g.*, assisting the flow of venous blood and lymph (Fig. 163). Its contractile power is paramount, however, exhibiting several kinds of contraction—tonic, static, concentric, and eccentric. *Tonic contraction* is the normal state of muscle tissue (see page 77). This varies with bodily states and is a very important factor in supporting the

joints of the skeleton. In this respect it may be said to have a "ligamentous action." *Static contraction* is a continuous state represented by the muscles of the forearm when the fist is held in a clenched position. *Concentric contraction* is the normal shortening of the muscle pulling the origin and insertion nearer

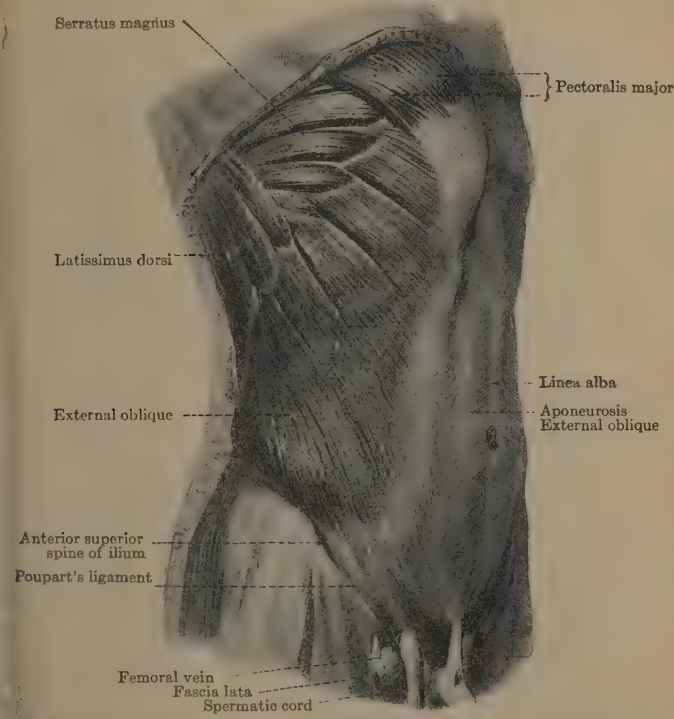

Fig. 164.—Muscles of the abdomen viewed from the right side (Spalteholz).

each other. In *eccentric contraction* the muscle contracts, but at the same time lengthens, giving up to the movement, yet holding the part momentarily. Thus, the movement in the joint is determined by the power of the contraction just as it is in the concentric type. An example of eccentric contraction is the muscular action of the front thigh muscles in bending the knees;

the same muscles in straightening the knees show concentric contraction.

The Names of Muscles.—The muscles are named for characteristics they possess in form, size, attachment, location, or

Fig. 165. Muscles of the abdomen, second layer, viewed from in front (Spalteholz).

function. The names are usually of Latin derivation, but the anglicized form is used often. They occur in pairs, usually as the paired somites of the body would suggest. Where they occur as single muscles they are situated in the median line and represent

a fusion of two lateral parts. There are a great many small muscles that are of no particular interest to the student of the practical arts. They will not be described here. The important ones concerned in movement or other functions that are significant will be described in terms of origin, insertion, and action.

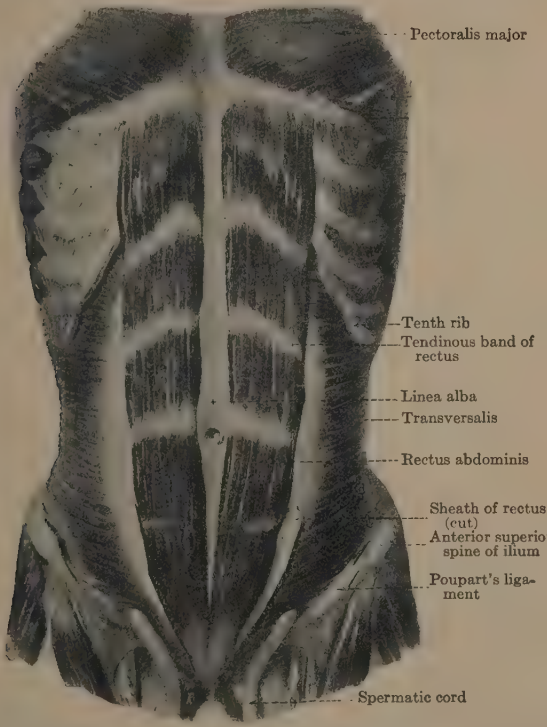

Fig. 166.—Rectus abdominis and transversalis viewed from in front (Spalteholz).

Muscles of the Abdominal Wall:

. *External oblique:*

Origin—The outer surface of the lower eight ribs near their costal ending.

Insertion—Anterior half of the outer lip of the crest of the ilium, Poupart's ligament, and the linea alba (the line of fusion in the median line of the abdominal wall made by the union of the two aponeuroses of the left and right external obliques) (Fig. 164).

Action—Compression of the abdominal cavity; flexion of the trunk; with the pelvis fixed, rotation of the trunk to the opposite side, and with the thorax fixed, rotation of the pelvis to the same side.

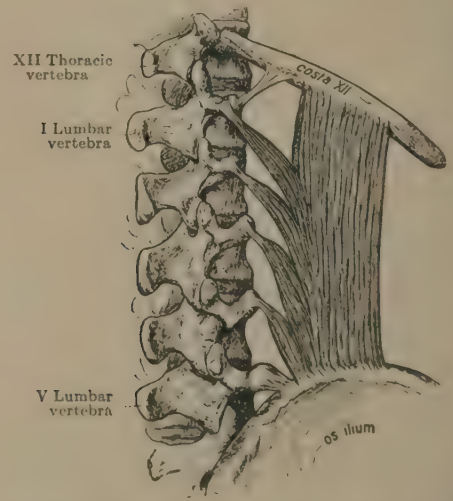

Fig. 167.—Quadratus lumborum viewed from right side (Sobotta and McMurrich).

2. Internal oblique:

Origin—The outer half of Poupart's ligament, anterior half of the middle lip of the crest of the ilium, and the lumbar fascia.

Insertion—The costal cartilages of the lower six ribs, the linea alba by means of the aponeurosis of the internal oblique, and the superior portion of the os pubis (Fig. 165).

Action—Compression of the abdominal cavity; flexion of the trunk; with the pelvis fixed, rotation of the trunk to the same side, and with the thorax fixed, rotation of the pelvis to the opposite side.

3. *Transversalis:*

Origin—The lower six costal cartilages, transverse processes of the lumbar vertebræ, anterior half of the inner lip of the crest of the ilium, and outer third of Poupart's ligament.

Insertion—The linea alba by means of the aponeurosis of the transversalis, and the crest of the os pubis (Fig. 166).

Action—Compression of the abdominal cavity.*

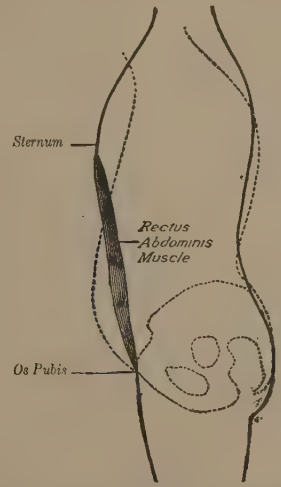

Fig. 168.—Diagram of good posture showing well-developed rectus abdominis muscle in tonic contraction, dotted line showing poor posture with relaxed and flabby abdominal wall. (From Williams, "Healthful Living," published by The Macmillan Company.)

Aponeuroses of the Obliques and Transversalis.—The aponeuroses of the external oblique meet in the midline, forming the linea alba. The one from the internal oblique splits into two layers at the lateral margin of the rectus abdominis (Fig. 170) for the upper three-fourths of its course. The anterior layer passes in front of the rectus, blends with the aponeurosis of the external oblique to reach the linea alba. The posterior layer passes

* The usefulness of the three muscles of the anterior abdominal wall in compression of the abdominal cavity is observed in the different stages of labor and in other emptying mechanisms. The illustration in Fig. 170 shows how well adapted the muscles are for doing such work.

behind the rectus, blends with the aponeurosis of the transversalis, and reaches the linea alba. In the lower fourth the

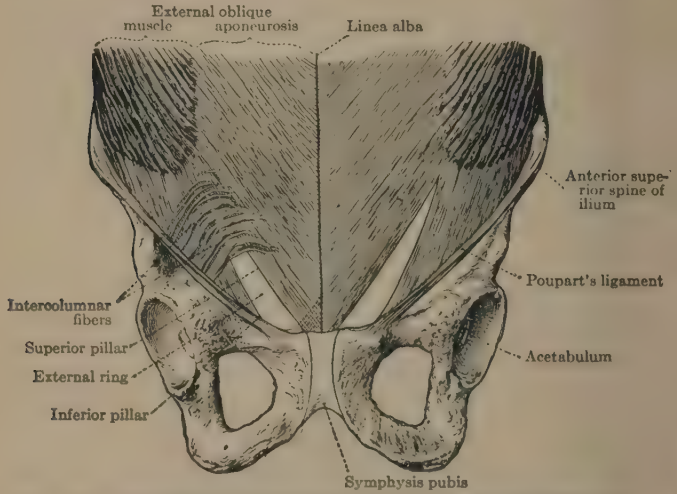

Fig. 169.—Diagram of the inguinal canal (Sobotta and McMurrich).

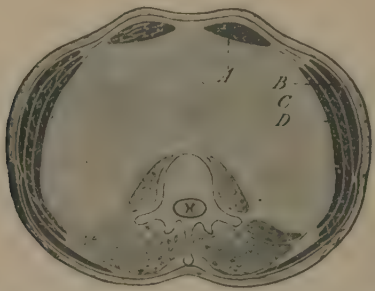

Fig. 170.—Transverse section showing arrangement of abdominal muscles. *A*, Rectus; *B*, external oblique; *C*, internal oblique; *D*, transversalis. (Campbell.)

aponeurosis of the internal oblique passes altogether in front of the rectus. Thus, over three-fourths of its course, the rectus has

aponeuroses of external and internal obliques in front, and internal oblique and transversalis behind. What is the distribution over the lower fourth?

4. *Quadratus lumborum:*

Origin—The posterior part of the inner lip of the crest of the ilium and iliolumbar ligament (Fig. 167).

Insertion—The last rib and the transverse processes of the upper four lumbar vertebræ.

Action—Depression of the last rib, especially in expiration, and abduction of the trunk.

5. *Rectus abdominis:*

Origin—The tip of the sternum, and fifth, sixth, and seventh ribs.

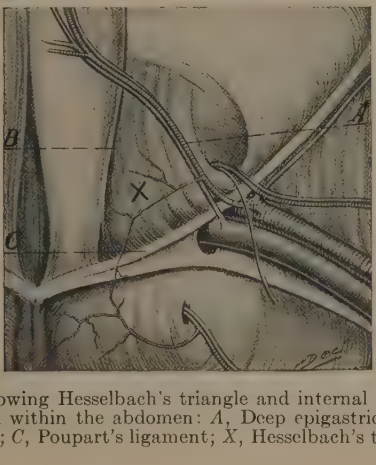

Fig. 171.—Showing Hesselbach's triangle and internal orifice of inguinal canal, seen from within the abdomen: *A*, Deep epigastric artery; *B*, outer margin of rectus; *C*, Poupart's ligament; *X*, Hesselbach's triangle. (Campbell.)

Insertion—The crest of the os pubis (Fig. 166).

Action—Compression of the abdominal cavity and flexion of the trunk. Extremely important in maintaining the normal contour of the abdominal wall (Fig. 168).

The Inguinal Canal and Hernia.—Lying just above Poupart's ligament is a canal or passageway through the anterior abdominal wall. This structure serves for the passage of the spermatic cord in the male and the round ligament in the female. It is marked

externally by the external abdominal ring (Fig. 169) and internally by the internal abdominal ring. The anterior wall of the canal is formed by the tendon of the external oblique and the fibers passing between the two pillars (Fig. 169); the lower wall is bounded by Poupart's ligament, the superior wall is formed by the fibers of the internal oblique, and the posterior wall is supported by the aponeurotic fibers of the transversalis muscle. The external opening of the canal is shown in Fig. 164, and the inner orifice in Fig. 171.

This opening through the abdominal wall constitutes a weak spot, and under certain conditions* a portion of the abdominal contents may be forced through the wall, giving rise to a hernia. In the male the hernial sac may descend into the scrotum and be of pronounced size.

Muscles of the Back:

1. *Erector spinæ:*

Origin -The lower two thoracic and all lumbar spines, the lower and posterior part of the sacrum, and the posterior tip of the iliac crest

Insertion —By three divisions that attach to the ribs and vertebræ all the way up the back as far as the mastoid process of the temporal bone (Fig. 172).

Action—Extension of the trunk.

2. *Trapezius:*

Origin—The occipital bone, the ligamentum nuchæ, the spinous processes of the seventh cervical, and of all the thoracic vertebræ.

Insertion —The upper fibers go to the lateral half of the posterior aspect of the clavicle, the middle fibers pass to the mesial margin of the acromion, and the lower fibers ascend to insert into the upper border of the spine of the scapula (Fig. 173).

* There are two main categories that include the conditions favoring hernia: (1) Increased intra-abdominal pressure, and (2) decreased resistance of the abdominal wall. Under the former would be included all heavy lifting, violent coughing, or expiratory movements; under the latter would be placed old age, any weakening or debilitating condition associated with muscular weakness. Hernia is quite common in the first year of life and more common in males than in females, due in the latter instance to the larger external ring in the male and the heavier work done. Hernia is found prevailingly in slender persons. (See The Medical Department of the United States Army in the World War, vol. xv, Statistics, p. 369, Washington, D. C. 1921.)

Action—Extension and hyperextension of the head, cervical and thoracic spines; elevation, adduction, depression, and upward rotation* of the scapula.

3. *Latissimus dorsi:*

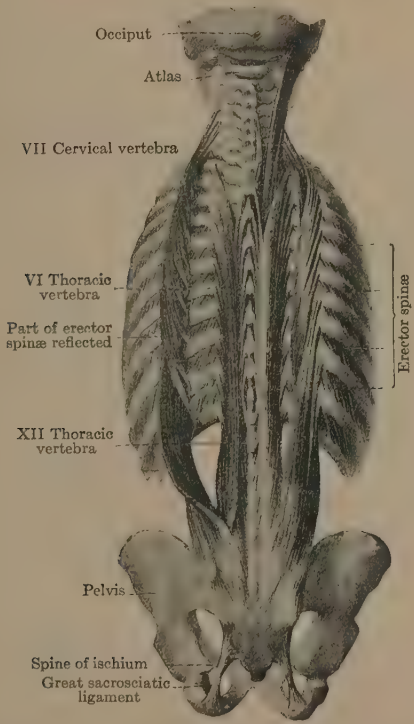

Fig. 172.—Erector spinæ muscles. On the right side one part has been pulled lateralward, on the left side it has been reflected (Spalteholz).

Origin—The spines of the lower six thoracic vertebræ, the lumbar aponeurosis (which comes from the spines of the lumbar

* Rotation of the scapula is considered to be movement around an anteroposterior axis through the center of the bone. Upward rotation swings the glenoid cavity upward; downward rotation returns it to its normal position.

vertebræ, the sacral spines, and the posterior third of the outer lip of the crest of the ilium), and the last three ribs (Fig. 173).

Insertion—The floor of the bicipital groove of the humerus.

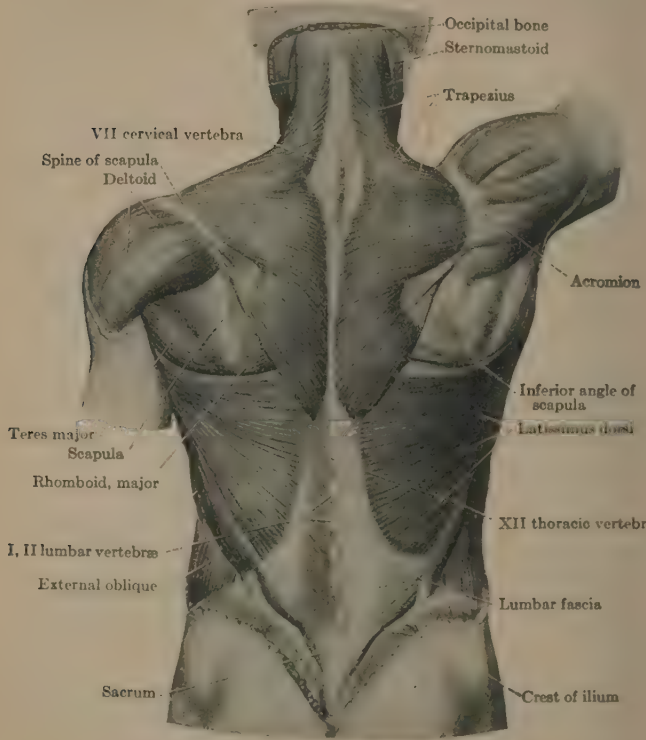

Fig. 173.—Muscles of the back (Sobotta).

Action—Extension, adduction, and inward rotation of the humerus; depression of the scapula acting indirectly on this bone through its articulation with the humerus.

Muscles of the Thorax:

1. *Diaphragm:*

Origin—The cartilages of the lower six ribs and by two *ligaments:* one of which runs from the body of the first lumbar

vertebra to the transverse process of the same bone, the other arching from the transverse process of the first lumbar to the last rib; and by two *crura* or strips of muscle attaching to the bodies of the upper two lumbar vertebræ on the left side and the upper three on the right (Fig. 174).

Insertion—A central tendon (Fig. 174).

Action—Increase of the vertical diameter of the thorax, and compression of the abdominal cavity from above.

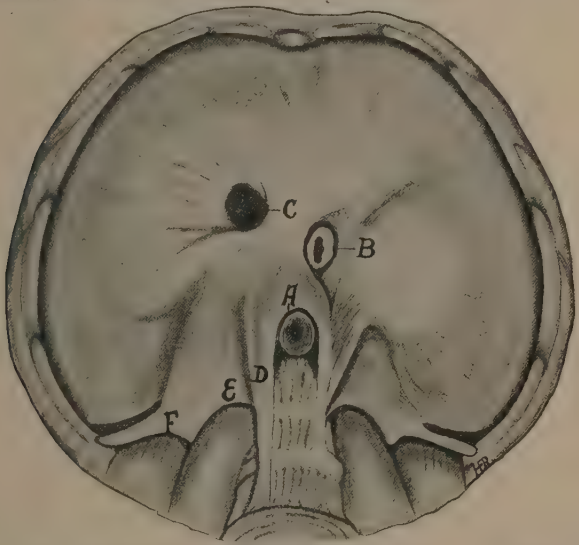

Fig. 174.—The abdominal surface of the diaphragm: *A*, Middle arcuate ligament and aortic orifice; *B*, esophageal orifice; *C*, caval orifice; *D*, right crus; *E*, mesial arcuate ligament; *F*, lateral arcuate ligament. (Radasch.)

Openings in the Diaphragm.—The diaphragm has three openings through which pass structures between the abdominal and thoracic cavities. The openings and their contents are: (1) the *aortic*, which contains the aorta, thoracic duct, and the large azygos vein, (2) the *esophageal*, anterior to the aorta opening, contains the esophagus and the two vagi nerves, and (3) the *caval*, situated to the right of the other two, passes the inferior vena cava.

2. *External intercostals:*

Origin—The lower border of the upper eleven ribs.
Insertion—The upper border of the last eleven ribs.
Action—Elevation of the ribs.

3. *Internal intercostals:*

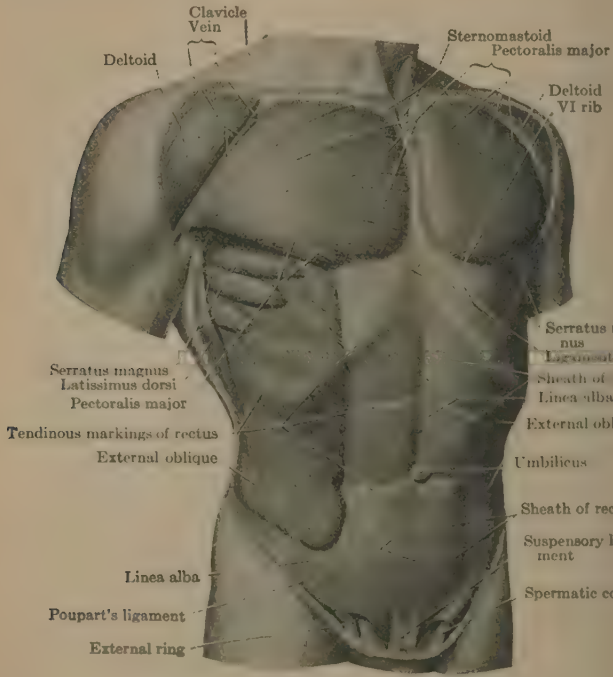

Fig. 175.—Muscles of the chest (Sobotta).

Origin—Inner surface of the upper eleven ribs just above the lower border.

Insertion—Upper border of the last eleven ribs.

Action—Depression of the ribs. There is wide difference of judgment on this action of the internal intercostals. Some anatomists state that the internal set elevate the ribs, while others insist that the opposite action is correct. One view not often represented states that the intercostals act both in elevation and

depression of the ribs. Whether the former action occurs depends upon the point of fixation. If the upper ribs are fixed by the cervical muscles, intercostal contraction will cause elevation; if the lower ribs are fixed, then depression will result from their combined action.

Muscles of the Chest:

1. *Pectoralis major:*

Origin—The mesial half of the anterior aspect of the clavicle, the corresponding half of the anterior surface of the sternum, the cartilages of the upper six ribs, and the aponeurosis of the external oblique (Fig. 175).

Insertion—The lateral lip of the bicipital groove of the humerus.

Action—Flexion, adduction, and inward rotation of the arm; abduction of the scapula (indirectly). If the arms are carried or fixed above the head, elevation of the ribs will result from the pull of the pectoral muscles.

2. *Pectoralis minor:*

Origin—The third, fourth, and fifth ribs by three digitations.

Insertion—The coracoid process of the scapula.

Action—Depression and downward rotation of the scapula. If the scapula is fixed, contraction of the pectoralis minor will raise the ribs.

Muscles of the Neck:

1. *Sternocleidomastoid:*

Origin—The sternal end of the clavicle and upper border of the manubrium.

Insertion—The mastoid process of the temporal bone.

Action—Acting with its fellow of the opposite side, it flexes the head. Acting alone, it twists the head to the opposite side.

Triangles of the Neck.—There are many small muscles on the front and side of the neck that are used in all movements of the head. When well developed they keep the neck firm, preventing the loose, relaxed appearance that is commonly seen. The muscles of the neck define important triangles.

The sternocleidomastoid serves to divide the side of the neck into two important triangles (Fig. 176). The anterior triangle lies with its apex downward. Its base, directed upward, is formed by the lower border of the mandible and a line continued from the angle of the mandible to the mastoid process. The lateral border of the triangle is the anterior border of the sterno-

cleidomastoid and the mesial boundary of the triangle is the median line of the neck. The posterior triangle lies with its apex upward. It is not so well defined as the anterior one. Its three sides are formed by the borders of the sternocleidomastoid and trapezius muscles and the clavicle.

Muscles of the Head and Face:

1. *Occipitofrontalis:*

This is a fibromuscular structure covering the skull from neck to forehead (Fig. 176). The central portion is an aponeurosis. At either end are the muscular portions: the *occipital*, attaching to

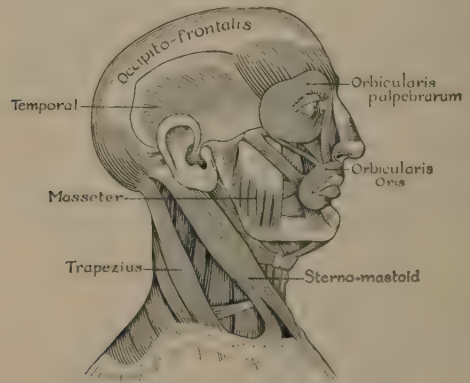

Fig. 176.—Muscles of head and neck.

the occipital and temporal bones; the *frontal*, attaching to the frontal bone.

Action—The frontal portion raises the eyebrows and draws the scalp forward; the occipital portion draws the scalp backward.

2. *Temporal:*

Origin—Temporal fossa of skull, the hollow mesial to the zygoma (Fig. 176).

Insertion—Coronoid process of mandible.

Action—To raise mandible against maxilla.

3. *Masseter:*

Origin—Zygoma and adjacent portions of maxilla.

Insertion—The angle and lateral surface of ramus of mandible.

Action—To raise mandible against maxilla.

4. *Orbicularis oris:*

Consists of numerous small, muscular fibers which surround the opening of the mouth. In action it closes the lips and protrudes them.

5. *Orbicularis palpebrarum:*

Origin—The mesial angle of the orbit.

Insertion—The lids of the eye and the skin of the cheeks.

Action—This is a true sphincter. It closes the eyelids gently, as in sleep, or more forcibly, as shown when the skin of the face is drawn toward the mesial margins of the orbits.

6. *Orbital muscles* (Fig. 390):

All of the orbital muscles, except the inferior oblique, arise from the sphenoid and the margins of the optic foramen. Their names, insertions, and actions are as follows:

(*a*) *Superior levator:*

Insertion—The skin of the upper lid.

Action—Elevates the upper lid.

(*b*) *Superior rectus:*

Insertion—Superior surface of the eyeball, into sclerotic coat, near cornea.

Action—Turns the eyes upward.

(*c*) *Inferior rectus:*

Insertion—Inferior surface of the eyeball, into sclerotic coat, near cornea.

Action—Turns the eyes downward. This action of the superior and inferior muscles is assisted by the obliques, for otherwise their single action would produce also some rotation and mesial deviation.

(*d*) *Lateral rectus:*

Insertion—Lateral aspect of the eyeball.

Action—Turns the eye laterally.

(*e*) *Mesial rectus:*

Insertion—Mesial aspect of the eyeball.

Action—Turns the eye mesially. The lateral and mesial recti produce a purely horizontal movement.

(*f*) *Superior oblique:*

Insertion—After passing through a pulley slung at the mesial margin of the orbit, it passes beneath to the sclerotic coat of the eyeball between the superior and lateral recti.

Action—Rotation of the eyeball on its anteroposterior axis, counter-clockwise for the left eye and clockwise for the right eye.

(*g*) *Inferior oblique:*

Origin—Lower margin of the orbit.

Insertion—The lateral aspect of the eyeball between the inferior and lateral recti.

Action—Rotation of the eyeball on its anteroposterior axis, clockwise for the left eye and counter-clockwise for the right eye.

Muscles of the Scapula:

1. *Levator scapulæ:*

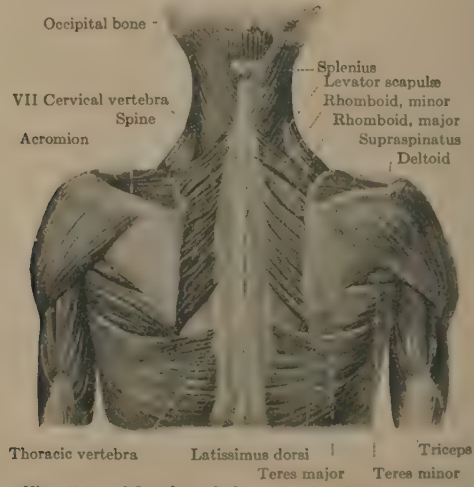

Fig. 177.—Muscles of the scapula (Spalteholz).

Origin—The transverse processes of the upper four cervical vertebræ.

Insertion—The vertebral border of the scapula between the superior angle and the root of the spine (Fig. 177).

Action—Lifting of the angle of the scapula.

2. *Rhomboids, major and minor* (Fig. 177):

Origin—The spines of the seventh cervical and first thoracic (minor) and the spines of the upper four thoracic (major) vertebræ.

Insertion—The vertebral border of the scapula between the root of the spine and the inferior angle.

Action—Adduction and downward rotation of the scapula.

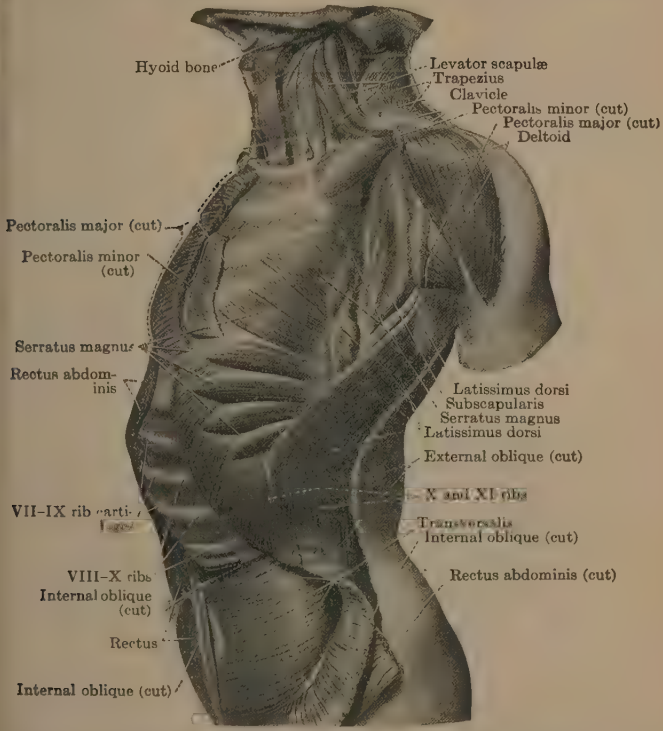

Fig. 178.—Side view of chest and scapular muscles. By cutting and reflecting parts deeper muscles are shown (Sobotta).

3. *Serratus magnus:*

Origin—By nine digitations from the upper eight ribs (Fig. 178.)

Insertion—The anterior aspect of the vertebral border of the scapula.

Action—Abduction and upward rotation of the scapula.

4. *Supraspinatus:*

Origin—The supraspinous fossa of the scapula (Fig. 179).

Insertion—Passing under the acromion it reaches the superior portion of the greater tuberosity of the humerus.

Action—Abduction of the arm.

5. *Infraspinatus:*

Origin—The infraspinous fossa of the scapula (Fig. 179).

Insertion—The middle part of the greater tuberosity of the humerus.

Action—Outward rotation of the arm.

6. *Teres minor:*

Origin—The upper two-thirds of the axillary border of the scapula (Fig. 179).

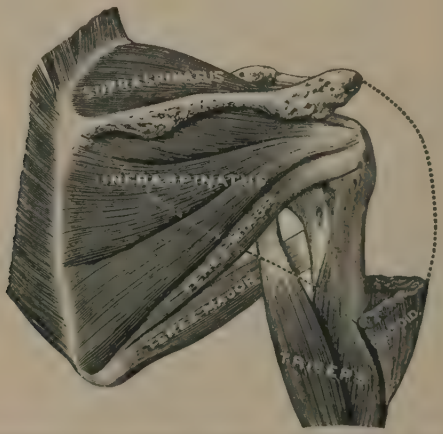

Fig. 179.—Muscles of the posterior surface of the scapula, right side (Testut).

Insertion—The inferior part of the greater tuberosity of the humerus.

Action—Outward rotation of the arm.

7. *Teres major:*

Origin—The lower third of the axillary border of the scapula (Fig. 179).

Insertion—The mesial lip of the bicipital groove.

Action—Inward rotation, adduction, and extension of the arm.

8. *Subscapularis:*

Origin—The subscapular fossa of the scapula.

Insertion—The lesser tuberosity of the humerus.

Action—Inward rotation of the arm.

9. *Deltoid:*

Origin—The lateral half of the anterior aspect of the clavicle, the lateral margin of the acromion, and the lower lip of the spine of the scapula (Fig. 173).

Insertion—The deltoid tubercle of the humerus.

Action—Abduction of the arm. The anterior portion assists in flexion, and the posterior portion assists in extension of the arm.

Muscles of the Arm:

1. *Biceps:*

Origin—The long head* from the supraglenoid fossa, and the short head from the coracoid process of the scapula (Fig. 180).

Insertion—The bicipital tuberosity of the radius.

Action—Flexion of the arm and forearm; supination of the hand.

2. *Coracobrachialis:*

Origin—The coracoid process of the scapula (Fig. 180).

Insertion—The middle of the mesial border of the humerus.

Action—Flexion of the arm.

3. *Brachialis anticus:*

Origin—From the lower two-thirds of the anterior surface of the humerus.

Insertion—The coronoid process of the ulna.

Action—Flexion of the forearm.

4. *Triceps:*

Origin—The long head comes from the infraglenoid fossa of the scapula, the lateral head from the posterior surface of the humerus above the musculospiral groove, and the mesial head from the posterior surface of the humerus below the musculospiral groove (Fig. 179).

Insertion—The olecranon of the ulna.

Action—Extension of the arm and the forearm.

Muscles of the Forearm and Hand.—The small muscles (Fig. 181) of the forearm and hand will not be described in detail (see tabulation on page 198). Arising from the mesial condyle of the humerus and from the anterior aspect of the ulna and radius

* The long head of the biceps passes over the head of the humerus and, after crossing the anatomic neck, lies in the bicipital groove, which gets its name from this occupancy.

are a group of muscles attaching to the carpal and metacarpal bones and the phalanges. They are concerned with the flexion of the fingers, pronation of the hand; flexion, abduction, and

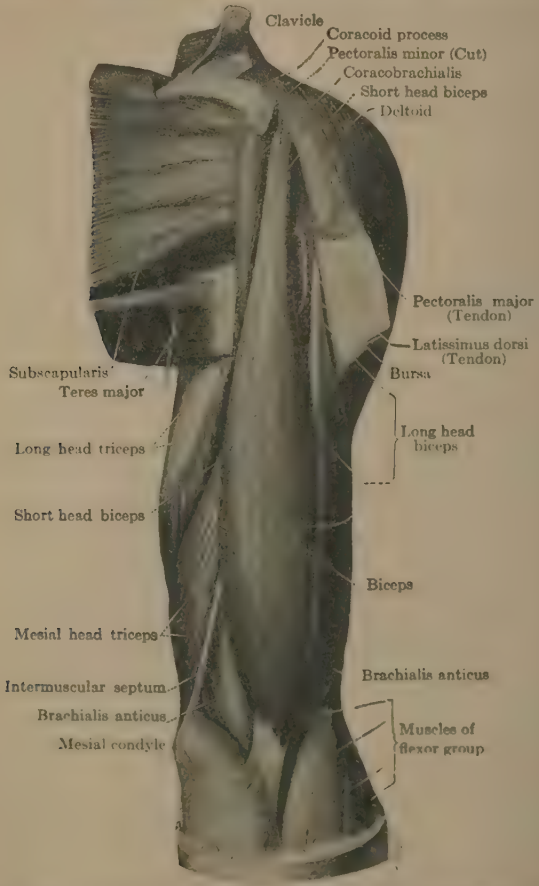

Fig. 180.—Anterior view of arm and scapular muscles (Sobotta).

adduction of the wrist; and some of them with flexion of the forearm. This anterior forearm group comprise the following: (1) pronator radii teres, (2) flexor carpi ulnaris, (3) palmaris

longus, (4) flexor carpi radialis, (5) flexor sublimis digitorum, (6) flexor profundus digitorum, (7) flexor longus pollicis, and (8) pronator quadratus.

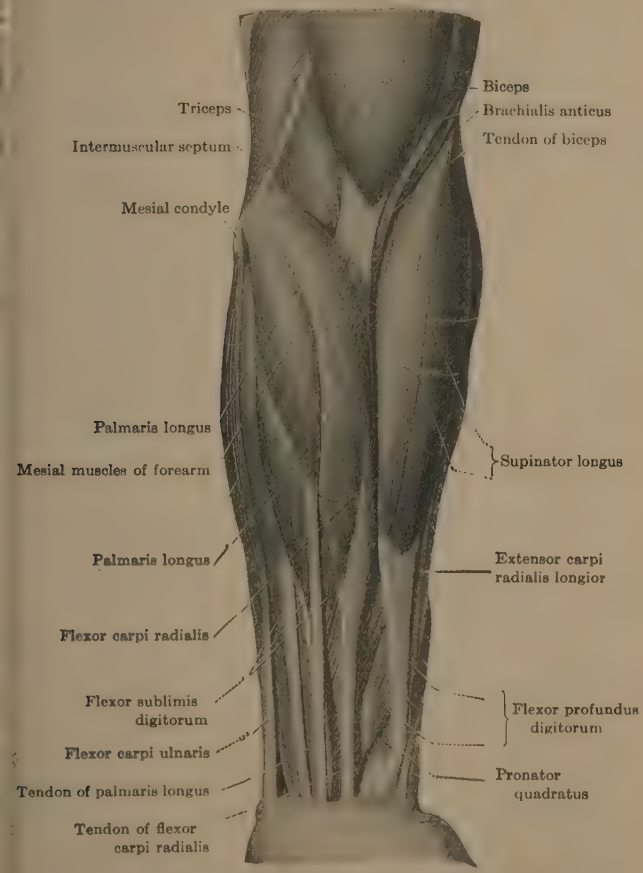

Fig. 181.—Muscles of the forearm, mesial and anterior view (Sobotta.)

Arising from the lateral condyle of the humerus and the posterior aspect of the ulna and radius are a group of muscles

attaching to the carpus, metacarpus, and phalanges. They are concerned with extension of the fingers; supination of the hand; extension, abduction, and adduction of the wrist; and extension of the forearm. This group comprises the following: (1) supinator longus, (2) extensor carpi radialis longior, (3) extensor

TABULATION OF MUSCLES OF FOREARM AND HAND

Flexors and Pronators

Name of muscle.	Origin.	Insertion.	Function.
Pronator radii teres	Humerus and ulna	Radius	Pronation of hand and flexion of forearm.
Flexor carpi ulnaris	Humerus and ulna	Pisiform, unciform and fifth metacarpal.	Flexion and adduction of hand.
Palmaris longus	Humerus	Palmar fascia	Flexion of hand.
Flexor carpi radialis	Humerus	Second and third metacarpals.	Flexion and pronation of hand.
Flexor sublimis digitorum	Humerus and radius	Second phalanges of the four fingers.	Flexion of second joint of four fingers and then of hand.
Flexor profundus digitorum	Ulna	Peripheral phalanges of the four fingers.	Flexion of peripheral phalanges and then of hand.
Flexor longus pollicis	Radius and ulna	Peripheral phalanx of the thumb.	Flexion of peripheral phalanx and then thumb.
Pronator quadratus	Ulna	Radius	Pronation of the forearm.

Extensors and Supinators

Supinator longus	Humerus	Lower end radius	Flexion of elbow and supination of hand.
Extensor carpi radialis longior	Humerus	Second metacarpal	Extension and abduction of hand.
Extensor carpi radialis brevior	Humerus	Third metacarpal	Extension of hand.
Extensor communis digitorum	Humerus	Middle and peripheral phalanges of 2, 3, 4, 5 fingers.	Extension of phalanges of the four fingers and extension of hand.
Extensor minimi digiti	Humerus	Middle and peripheral phalanges of little finger.	Extension of adduction of the hand.
Extensor carpi ulnaris	Humerus	Fifth metacarpal	Extension and adduction of the hand.
Supinator radii brevis	Humerus and ulna	Radius	Supination of forearm.
Extensor ossis metacarpi pollicis	Ulna and radius	Fifth metacarpal	Abduction and extension of the thumb.
Extensor brevis pollicis	Radius	Proximal phalanx of the thumb.	Extension of first phalanx of thumb.
Extensor longus pollicis	Ulna	Peripheral phalanx of the thumb.	Extension of the peripheral phalanx
Extensor indicis	Ulna	Middle and peripheral phalanges of index finger.	Extension of index finger.

carpi radialis brevior, (4) extensor communis digitorum, (5) extensor minimi digiti, (6) extensor carpi ulnaris, (7) supinator radii brevis, (8) extensor ossis metacarpi pollicis, (9) extensor brevis pollicis, (10) extensor longus pollicis, and (11) extensor indicis.

Located in the hand are numerous small muscles concerned with movement of the thumb and fingers. The thumb muscles form a palmar group running from the carpal and metacarpal bones to the phalanges and first metacarpal of the thumb. These constitute a mass on the palmar surface called the *thenar eminence* (Fig. 160). A similar but smaller group is present on the ulnar side of the palm associated with the action of the little finger (Fig. 160). These form the *hypothenar eminence.* Between the metacarpal bones and attaching to phalanges are small muscles shaped much like feathers and known as lumbricales and interossei (Fig. 160).

Classification of the Muscles of the Trunk and Upper Extremity.—The muscles of the regions studied may be classified with reference to their action and may be placed in groups as they affect the motion in different joints.

Flexors of the spine:
Rectus abdominis,
External oblique,
Internal oblique.

Abductors of the spine:
Erector spinæ (same side),
Quadratus lumborum (same side),
Internal oblique.

Rotators of the spine:
Internal oblique,
External oblique.

Abductors of the scapula:
Serratus magnus,
Pectoralis major.

Elevators of the scapula:
Trapezius.

Upward rotators of the scapula:
Trapezius,
Levator scapulæ,
Serratus magnus.

Flexors of the humerus:
Pectoralis major,
Biceps,
Deltoid,
Coracobrachialis.

Extensors of the spine:
Erector spinæ,
Trapezius,
Latissimus dorsi.

Adductors of the spine:
Erector spinæ,
Quadratus lumborum,
Internal oblique.

Adductors of the scapula:
Trapezius,
Rhomboids.

Depressors of the scapula:
Pectoralis minor,
Serratus magnus,
Latissimus dorsi,
Trapezius.

Downward rotators of the scapula:
Latissimus dorsi,
Pectoralis minor,
Levator scapulæ,
Rhomboids.

Extensors of the humerus:
Triceps,
Latissimus dorsi,
Teres major.

Abductors of the humerus:
Deltoid,
Supraspinatus.

Adductors of the humerus:
Pectoralis major,
Subscapularis,
Latissimus dorsi,
Triceps,
Teres major.

Inward rotators of the humerus:
Pectoralis major,
Teres major,
Latissimus dorsi.

Outward rotators of the humerus:
Infraspinatus,
Teres minor.

Extensors of the forearm:
Triceps,
The group of forearm muscles attaching to the lateral condyle of the humerus.

Flexors of the forearm:
Biceps,
Brachialis anticus,
The group of forearm muscles attaching to the mesial condyle of the humerus.

The muscular action of the groups involving the wrist, hand, and fingers has been indicated.

Fig. 182.—Levator ani and coccygeus from below (DeLee).

Muscles of the pelvis comprise two groups: the pelvic floor muscles and the hip-joint muscles.

Muscles of the pelvic floor form a diaphragm at the pelvic outlet, in which there are two openings in the male and three in the female. The important muscles viewed from below (Fig. 182) are the levator ani, coccygeus, and pyriformis.

1. *Levator ani:*

Origin—The posterior surface of the body of the os pubis, the spine of the ischium, and a fascial border that runs between these two points of origin.

Insertion—The tip of the coccyx and a median tendinous band that runs from coccyx to rectum. In front of the rectum the fibers pass downward and backward to reach the rectum, leaving in the male an opening for the urethra, and in the female an aperture for the vagina and urethra.

Action—Supporting and raising of the pelvic organs.

2. *Coccygeus:*

Origin—The spine of the ischium.

Insertion—The coccyx and the sides of the sacrum.

Action—Supporting and raising of the pelvic organs.

3. *Pyriformis:*

Origin—The anterior surface of the sacrum near the margin of the great sacrosciatic notch (Fig. 183).

Insertion—The superior surface of the great trochanter of the femur.

Action—Supporting of the pelvic floor and rotation of the thigh outward.

Muscles of the hip-joint pass from the pelvis to the femur and form the main muscle mass of the hip in front and behind.

4. *Psoas magnus:*

Origin—The last thoracic and the five lumbar vertebræ (Fig. 183).

Insertion—The small trochanter of the femur.

Action—Flexion and outward rotation of the thigh.

5. *Iliacus:*

Origin—The iliac fossa of the ilium (Fig. 183).

Insertion—The small trochanter of the femur. The fibers of the psoas and iliacus are intimately blended as they cross the brim of the pelvis, and their point of insertion is very close together.

Action—Flexion and outward rotation of the thigh

6. *Gluteus maximus* (Fig. 184):

Origin—The posterior fourth of the crest of the ilium; the lateral aspect of the ilium between crest and superior curved line, and the lumbar aponeurosis.

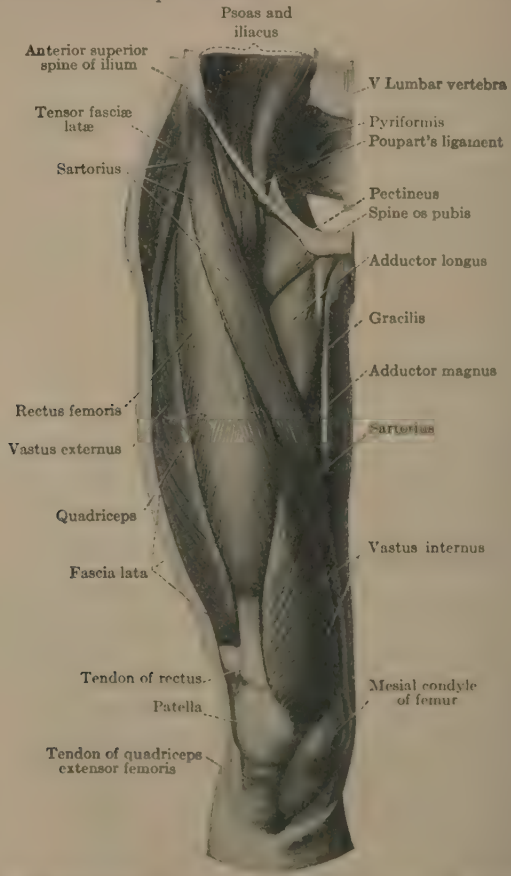

Fig. 183.—Anterior view of hip and thigh muscles (Sobotta).

Insertion—Posterior aspect of the great trochanter and the upper part of the linea aspera of the femur.

Action—Extension and outward rotation of the thigh.

7. *Gluteus medius* (Fig. 184).

Origin—The lateral aspect of the ilium between the superior and middle curved lines.

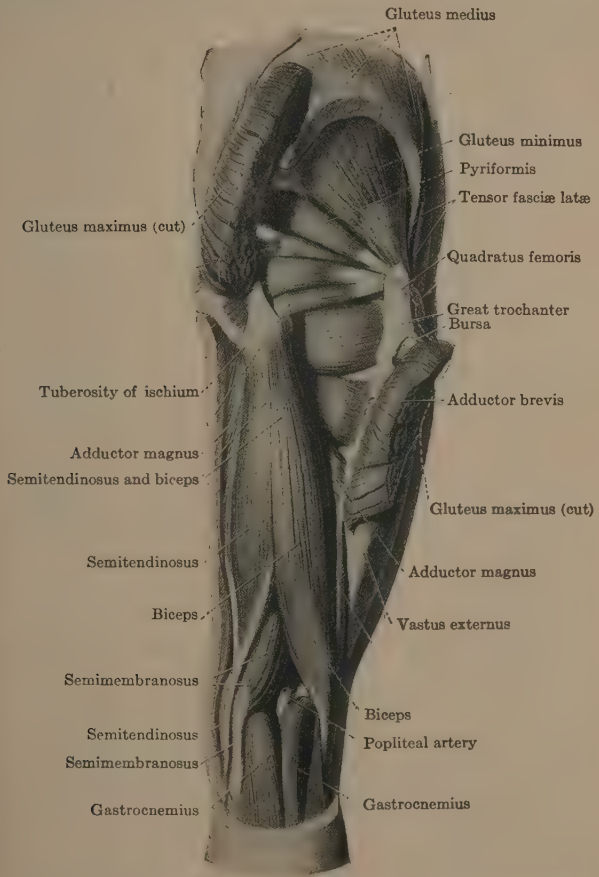

Fig. 184.—Posterior view of hip and thigh muscles (Sobotta).

Insertion—The lateral surface of the great trochanter of the femur.

Action—Abduction of the thigh.

8. *Gluteus minimus* (Fig. 184):

Origin—The lateral aspect of the ilium between the middle and inferior curved lines.

Insertion—Anterior aspect of the great trochanter of the femur.

Action—Abduction of the thigh.

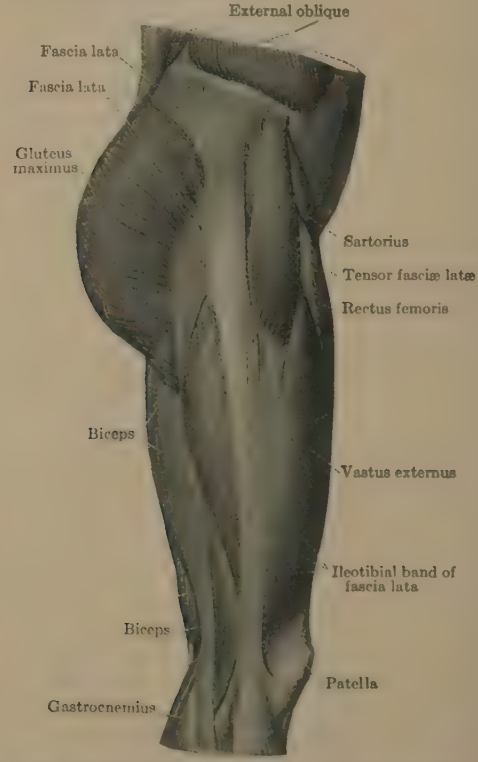

Fig. 185.—Lateral view of hip and thigh muscles (Sobotta).

Muscles of the Thigh.—Some of the following muscles attach to the pelvis, and some to the tibia and fibula, as well as to the femur, but they are placed in this group because they comprise the muscular mass known as the thigh. The *anterior* group follows.

1. *Tensor fasciæ latæ:*

Origin—The crest of the ilium just posterior to the anterior superior spine (Fig. 185).

Insertion—A broad, heavy fascial covering known as the fascia lata. This fascia covers the thigh muscles, attaching below to the ligaments of the knee-joint, and fusing above with the fascia of the thigh muscles. The fibers of this muscle insert into the fascia lata about half-way down the thigh.

Action—Abduction and inward rotation of the thigh and tightening of the fascia lata. This muscle serves important functions in walking and especially in keeping the balance of the body.

2. *Sartorius:*

Origin—The anterior superior spine of the ilium (Fig. 183).

Insertion—The mesial aspect of the tibia at the junction of the head and shaft.

Action—Flexion and outward rotation of the thigh.

3. *Quadriceps extensor femoris* (Fig. 183):

This muscle has four parts: rectus femoris, vastus internus, vastus externus, and crureus.

Origin—(1) The rectus femoris arises from the anterior inferior spine and by a reflected tendon from the margin of the acetabulum.

(2) The vastus internus arises from the mesial lip of the linea aspera of the femur.

(3) The vastus externus arises from the lateral lip of the linea aspera of the femur.

(4) The crureus arises from the anterior surface of the femur.

Insertion—The muscle-fibers from the four heads of origin come together to a common tendon just above the knee-joint. Passing over the front of the knee-joint the tendon inserts into the tuberosity of the tibia. As it passes over the joint it receives within itself the patella, in intimate contact with the articulating surface of the femur.

Action—The muscle is badly named because it does not extend the femur; its action is quite the reverse. The rectus portion acts as a flexor of the thigh; the entire muscle is a powerful extensor of the leg.*

* This muscle is frequently injured in athletic sports due to sudden effort before warming up, or bruising of the tissue by impact, as being tackled in football. The name "Charley horse" is commonly applied to the condition. It is found that in the middle section of the rectus an inflammatory area is present with a lump or hard spot that is extremely tender.

The *adductors of the thigh* form a muscular partition on the mesial aspect of the thigh dividing the anterior from the posterior muscles.

4. *Adductor magnus:*

Origin—The lateral surface of the body and ascending ramus of the ischium.

Insertion—The entire length of the linea aspera of the femur running diagonally between the origins of the vasti muscles and ending below at the adductor tubercle.

Action—Adduction, flexion, and outward rotation of the thigh.

5. *Adductor brevis:*

Origin—The anterior surface of the body of the os pubis.

Insertion—The upper third of the linea aspera between the vastus internus and the adductor magnus (Fig. 184).

Action—Adduction, flexion, and outward rotation of the thigh.

6. *Adductor longus:*

Origin—The descending ramus of the os pubis (Fig. 183).

Insertion—Below the adductor brevis.

Action—Adduction, flexion, and outward rotation of the thigh.

7. *Gracilis:*

Origin—The descending ramus of the os pubis.

Insertion—On the tibia beside the sartorius.

Action—Adduction of the thigh and flexion of the leg.

8. The *hamstrings:*

These are a group of muscles on the posterior aspect of the thigh, so called because their tendons in the hog are used in hanging up the ham of the animal. There are three muscles which may be considered as a group:

Semitendinosus, semimembranosus, and *biceps:*

Origin—All three come from the tuberosity of the ischium; the biceps has an additional head of origin from the linea aspera of the femur between the adductor magnus and the vastus externus (Fig. 184).

Insertion—(1) The semitendinosus inserts beside the gracilis and sartorius on the tibia, where the shaft and head join.

(2) The semimembranosus inserts into the posterior aspect of the mesial condyle of the tibia.

(3) The biceps inserts into the upper end of the fibula.

Action—Extension of the thigh and flexion of the leg. The first two produce inward rotation of the femur if the knee is flexed.

Muscles of the Leg.—In describing the muscles of the upper extremity the forearm muscles (corresponding to the leg muscles in position) were tabulated and not described in any detail. The

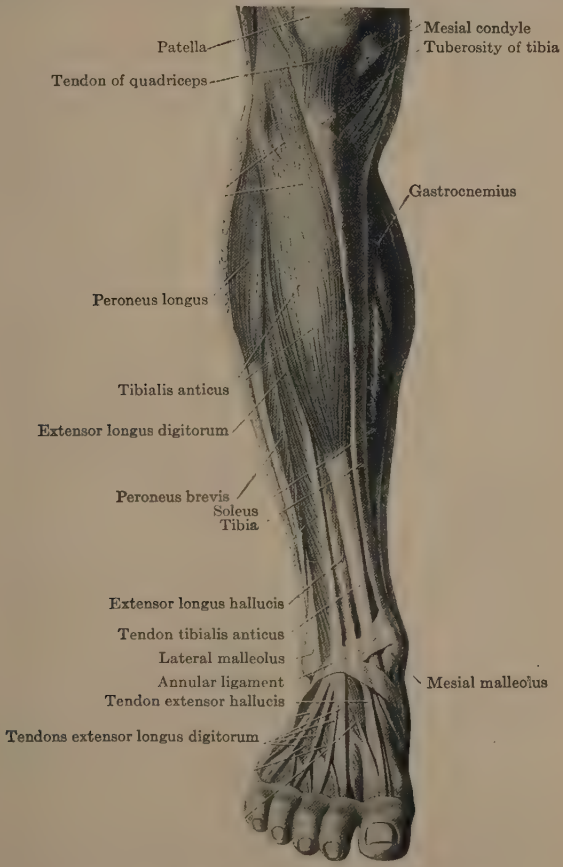

Fig. 186.—Anterior view of leg muscles (Sobotta).

muscles of the leg are so important in maintaining the arches of the foot that more detailed consideration of them would seem to

be indicated. They may be divided into three groups: (1) an anterior or extensor group, (2) a posterior or flexor group, and (3) a lateral or everter group.

The anterior leg muscles (Fig. 186):

1. *Tibialis anticus:*

Origin—The upper two-thirds of lateral surface of the tibia.

Insertion—The proximal end of the first metatarsal and the mesial aspect of the mesial cuneiform bone.

Action—Flexion of the foot and elevation of its mesial border. It helps to maintain the longitudinal arch.

2. *Extensor longus digitorum:*

Origin—The upper two-thirds of the anterior surface of the fibula.

Insertion—By four tendons into the middle and distal phalanges of the four outer toes.

Action—Extension of the four outer toes and flexion of the foot.

3. *Extensor longus hallucis:*

Origin—The middle part of the fibula on its mesial and anterior aspect.

Insertion—The distal phalanx of the great toe.

Action—Extension of the great toe and flexion of the foot.

The posterior leg muscles (Fig. 187).

4. *Gastrocnemius:*

Origin—The posterior aspect of the mesial and lateral condyles of the femur.*

Insertion—The tendo Achillis, which also receives the fibers of the soleus before inserting into the os calcis.

Action—Extension of the foot and flexion of the leg.

5. *Soleus:*

Origin—The posterior aspect of the upper end of the fibula and the oblique line of the tibia.

Insertion—The tendo Achillis.

Action—Extension of the foot.

6. *Tibialis posticus:*

* In falling of the arch of the foot there is frequently associated a shortening of the gastrocnemius. Consequently, often the first sign of arch trouble is pain behind the knee at the heads of origin of the gastrocnemius, or the pain may locate in the belly of the muscle itself. This pain is due to the static contraction of the muscle and the pull on the tendons of origin. At times pain from this condition may be located in the hip-joint or back. This represents a compensatory adjustment in these areas and a corresponding strain in the effort to overcome the foot condition.

Origin—Mainly from a membranous partition between tibia and fibula, called the interosseous membrane; also from adjacent parts of the tibia and fibula.

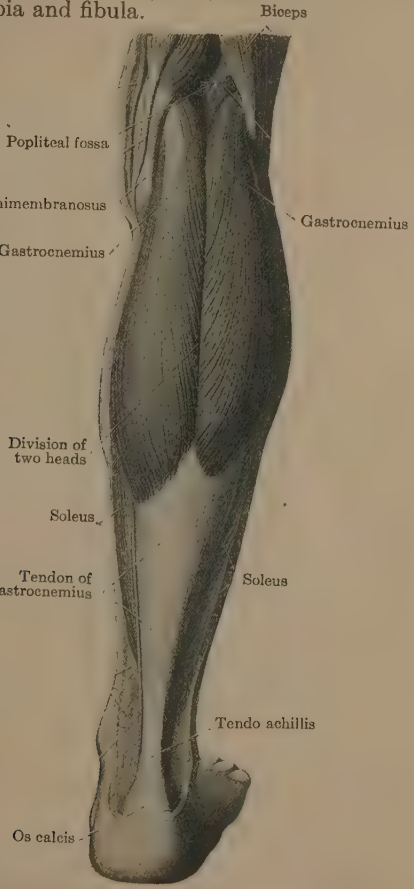

Fig. 187.—Posterior view of leg muscles (Sobotta).

Insertion—The under surface of the tarsus, attaching to the os calcis, scaphoid, cuboid, the three cuneiform bones, and the second, third, and fourth metatarsals.

Action—Extension of the foot and elevation of the mesial border.

7. *Flexor longus digitorum:*

Origin—The middle part of the posterior surface of the tibia.

Insertion—By four tendons to the distal phalanges of the four outer toes.

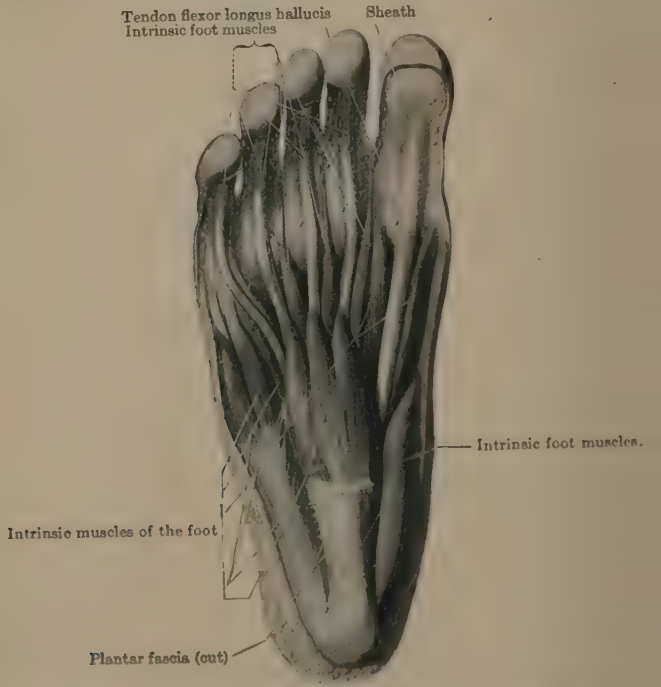

Fig. 188.—Plantar surface of foot showing superficial intrinsic foot muscl (Sobotta).

Action—Flexion of the four outer toes and extension of th foot.

8. *Flexor longus hallucis:*

Origin—The lower two-thirds of the posterior surface of th fibula.

Insertion—The distal phalanx of the great toe.

Action—Flexion of the great toe and extension of the foot.

The lateral leg muscles:

9. *Peroneus longus:*

Origin—The upper two-thirds of the lateral surface of the fibula.

Insertion—The tendon passes under the lateral malleolus to reach the cuboid bone where it lies in a groove of that bone and continues across the sole of the foot to reach the proximal end of the first metatarsal and mesial cuneiform.

Action—Extension and eversion of the foot.

10. *Peroneus brevis:*

Origin—The lower third of the lateral surface of the fibula.

Insertion—The proximal end of the fifth metatarsal bone.

Action—Extension and eversion of the foot.

The Muscles of the Foot.—The muscles of the leg that have been described have important relations with the foot. Because their muscle bodies lie outside the foot they are called the *extrinsic foot muscles.* The muscles that lie within the foot proper are called the *intrinsic foot muscles.* The intrinsic foot muscles (Fig. 188) are important structures in all movements of the foot, in walking, running, standing, and jumping. The integrity of the arches of the feet are dependent very largely upon the strength of these muscles, assisted by the tendons of the extrinsic muscles (those of the large flexor group passing on the mesial aspect of the ankle). Nurses, physiotherapists, specialists in corrective gymnastics, and teachers of physical education should make a careful study of the foot with reference to its proper use and the correction of abnormalities.[3]

Classification of the Muscles of the Hip and Lower Extremity.—The muscles of the regions studied may be arranged with reference to their action:

Flexors of the femur:
- Psoas magnus
- Iliacus,
- Sartorius,
- Rectus femoris,
- Adductor magnus,
- Adductor longus,
- Adductor brevis.

Extensors of the femur:
- Gluteus maximus,
- Semitendinosus,
- Semimembranosus,
- Biceps.

Abductors of the femur:
- Tensor fasciæ latæ,
- Psoas magnus,
- Iliacus,
- Gluteus medius,
- Gluteus minimus.

Adductors of the femur:
- Adductor magnus,
- Adductor longus,
- Adductor brevis,
- Gracilis.

Outward rotators:
Psoas magnus,
Iliacus,
Sartorius,
Gluteus maximus,
Pyriformis.
Adductor magnus.
Adductor longus.
Adductor brevis.

Flexors of the leg:
Semitendinosus,
Semimembranosus,
Biceps,
Gastrocnemius,
Sartorius,
Gracilis.

Flexors of the foot:
Tibialis anticus,
Extensor longus digitorum,
Extensor longus hallucis.

Inward rotators:
Tensor fasciæ latæ,
Semimembranosus,
Semitendinosus.

Extensors of the leg:
Quadriceps extensor femoris.

Extensors of the foot:
Gastrocnemius,
Soleus,
Tibialis posticus,
Flexor longus digitorum,
Flexor longus hallucis,
Peroneus longus,
Peroneus brevis.

Measurement of Muscular Strength.—The testing of the strength of different muscle groups shows a wide variation due to age and sex.[4] The following table, compiled from numerous observations by Quetelet, gives the lifting power without distinguishing between the part played by back, legs, hips, and arms

Age in years.	Weight lifted in kilograms:		Annual gain:		Difference between a and b.
	Male (a).	Female (b).	(a)	(b)	
10	45	31	..	..	14
11	48	35	3	4	13
12	52	39	4	4	13
13	63	43	11	4	20
14	71	47	8	4	24
15	80	51	9	4	29
16	95	67	15	6	28
20	132	74	..	..	58
27	154	83	..	..	71

The above table shows that the strength of a male child of ten is between one-third and one-fourth as much as the adult of the same sex, and that the strength of the female child of the same age is about three-eighths as great as the strength of the adult of the same sex. It also appears from the above table that the lifting power of girls while actually increasing from the age of ten to twenty-seven, decreases relatively to the increase in

strength for boys.[5] Baldwin* in recent observations draws a similar conclusion, stating that girls are inferior to boys in all strength tests, and showing after fifteen years of age little increase and frequently a decrease in strength.

Feldman† gives the following figures in kilograms for the strength of left and right forearm for males:

Age in years.	Right hand.	Left hand.	Both hands.
6	4	2	10.3
7	7	4	14.0
8	7.7	4.6	17.0
9	8.5	5	20.0
10	9.8	8.4	26.0
11	10.7	9.2	29.2
12	13.9	11.7	33.6
13	16.6	15.0	39.8
14	21.4	18.8	47.9

Females for all ages up to fifteen years show about 60 per cent. of the strength exhibited by males. It is to be noted that both hands are stronger than twice the strength of the best hand alone. The infant gains slowly the power of voluntary muscular movement.[6] The first voluntary movements are made between the third and fourth months. The infant‡ can hold up the head usually by the fourth month. It sits at the seventh month, stands at the tenth to twelfth month, and is able to walk alone and freely by the fourteenth to fifteenth month.

Norms for Amplitude of Voluntary Movement.—The range of movement or amplitude in a joint is the greatest possible movement in any plane. Thus the range in flexion-extension of the elbow is the number of degrees described by the forearm in passing from the position of greatest extension to the position of greatest flexion. The normal range of voluntary movement in the different parts of the body was of very great importance in the treatment of soldiers of the World War. It is important

* Baldwin, B.: Physical Growth of Children from Birth to Maturity, University of Iowa Studies, No. 50, 1921.

† Ibid., p. 376.

‡ During the first weeks of life the irritability of muscle tissue in the child is very low. The child's curve of contraction and relaxation is very slow, due probably to the smaller diameter of the muscle-fibers. The aged show a similar physiologic state. Structurally, their muscle-fibers are both smaller and fewer in number.

NORMS IN DEGREES

Joint movement.	Average amplitude.	Average deviation.*	Range.
Shoulder:			
Flexion—extension	261.0	9.1	228–282
Abduction—adduction	207.5	6.6	180–222
Elbow:			
Flexion—extension	152.3	6.0	135–173
Wrist:			
Flexion—extension	166.0	6.5	147–183
Abduction—adduction	96.5	10.3	68–132
Finger:			
Flexion—extension, carpophalangeal:			
2 (index)	96.0	9.0	70–127
3	80.0	9.0	52–105
4	77.5	8.0	50–130
5	98.5	9.5	67–130
Mesophalangeal:			
2 (index)	134.5	9.5	102–165
3	136.0	8.5	110–161
4	131.5	9.5	90–161
5	118.5	12.5	82–152
Distal:			
2 (index)	108.5	10.5	77–155
3	104.5	10.0	70–140
4	91.5	11.5	55–125
5	95.5	12.5	46–137
Hip:			
Flexion—extension	129.0	11.4	85–162
Abduction	54.5	7.1	35–80
Knee:			
Flexion—extension	133.0	7.5	110–155
Ankle:			
Flexion—extension	53.0	4.0	41–66

* The range above and below the average which includes approximately half of the cases.

today because of the injuries to joints from accident or disease. The determination of the norms, offered by Gilliland, were made by the use of metrotherapy apparatus.* The subjects selected were male college students. The range for women, children, or old persons would probably be different. It would be reasonable to accept as normal any amplitude above the lowest range given in the table above.

Motor Points and Reaction of Degeneration.—Muscle and nerve are a unit. Alone the muscle is helpless; it requires a motor

* Described in Jour. Amer. Med. Assoc., October 9, 1920, p. 983.

nerve for action. Hence, the neuromuscular unit forms the basis for all functional activity of the muscles. Muscles may be artificially stimulated to contract by the application of the galvanic current to the nerves going to the muscles. The most superficial position of the nerve is known as the *motor point* of the nerve for the muscle concerned. The motor points for the

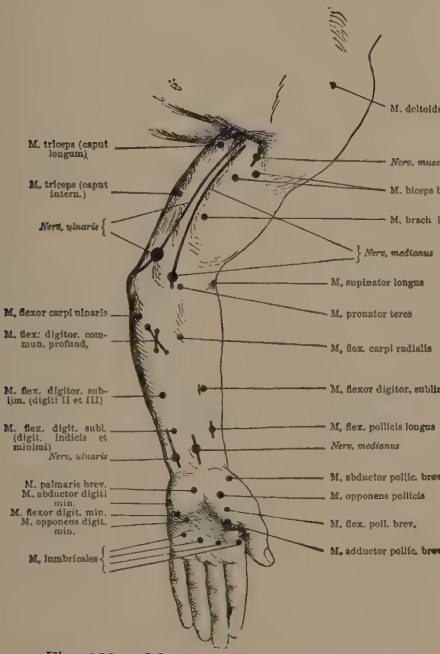

Fig. 189.—Motor points in upper extremity.

muscles of the upper and lower extremities are shown in Figs. 189, 190.

If the nerve connection to a muscle is interrupted the nerve and muscle degenerate. This degeneration may be detected by electric means. Change in the normal response of nerve and muscle to the electric currents is called the *reaction of degeneration* (R. D.). In such condition the nerve fails to respond to the galvanic and induced currents. Normally the contraction of the

muscle comes with closing of the negative pole, cathodal closing contraction (C. C. C.), while in the degenerated muscle the response is more marked to the closing of the positive pole, anodal closing contraction (A. C. C.). Moreover, degeneration in

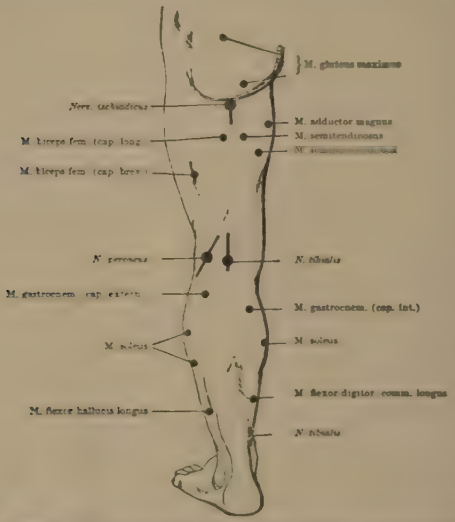

Fig. 190.—Nerves and motor points in lower extremity.

muscle is shown by an extreme sensitiveness to the galvanic current, but it fails to respond to the induced current. The use[7] of these anatomic and physiologic facts is extremely important in physiotherapy.*

PRACTICAL EXERCISES

1. Dissect cat or rabbit and note the following: striated muscle, smooth muscle, tendons, aponeuroses, origins and insertions of muscles, fascia, and nerve attachment to muscles.

2. Study slides of smooth striated and cardiac muscle. Note distinguishing characteristics.

3. Study the abdominal wall muscles (Figs. 164–166) and note the direction of the fibers in the three layers. Why does the surgeon in opening the abdomen follow the line of the fibers of the external oblique in the skin incision? Would he cut the fibers of the internal oblique? What method

* McKenzie, R. Tait: Reclaiming the Maimed, The Macmillan Co., New York, 1918, pp. 10–36. Fox, R. F.: Physical Remedies, Wm. Wood & Co., New York, 1917, pp. 135–166.

of entering the abdomen would be best in order to preserve the strength of the abdominal wall?

4. The tone of muscles is maintained by exercise. Lie relaxed, supine, and see what muscle groups can be contracted without producing movement in joints and without bringing into play other muscle groups. Try to contract the abdominal muscles, the thigh, leg, back, neck, and arm muscles.

5. Using a hand dynamometer,* make the greatest possible contraction of the forearm muscles. Repeat ten times at ten-second intervals. What happens?

6. After a rest of fifteen minutes, with massage of the forearm muscles, repeat Experiment 5. Account for the difference between the first contraction in 6 and the last one in 5.

7. Torticollis, "wryneck," is a condition due to congenital defect or spasm of the sternomastoid, either alone or associated with the trapezius. If the head is turned to the right, which sternomastoid is involved?

8. The arch of the foot is maintained in normal condition by fascia, ligaments, and muscles. If this support is relaxed, the arch flattens. This not infrequently occurs in adult life. Before birth, or less frequently after, the opposite may develop, in which contraction of these structures produces a condition of club-foot. This may take one of several forms (Fig. 191):

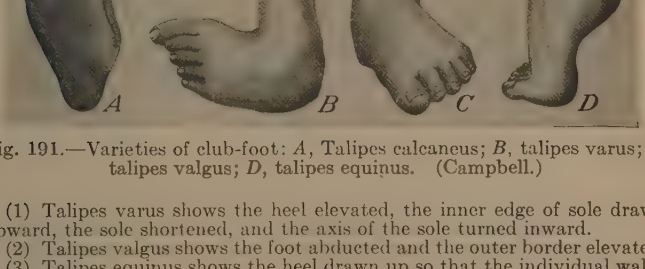

Fig. 191.—Varieties of club-foot: *A*, Talipes calcaneus; *B*, talipes varus; *C*, talipes valgus; *D*, talipes equinus. (Campbell.)

(1) Talipes varus shows the heel elevated, the inner edge of sole drawn upward, the sole shortened, and the axis of the sole turned inward.

(2) Talipes valgus shows the foot abducted and the outer border elevated.

(3) Talipes equinus shows the heel drawn up so that the individual walks on his toes.

(4) Talipes calcaneus shows the forward part of the foot drawn upward so that the individual walks on his heels. Imitate these conditions as accurately as possible.

9. On the anterior aspect of the thigh is a landmark of importance to surgeons because of the vessels and nerves in the area. This is Scarpa's triangle. It is bounded as follows: The base is formed by Poupart's ligament, the mesial boundary by the adductor longus, and the lateral boundary by the sartorius muscle. From the middle of its base to the apex pass the femoral vessels and branches of the lumbar plexus of nerves. Locate Scarpa's triangle by outlining its boundaries with a skin pencil.

10. A famous point in abdominal surgery is known as McBurney's point. It is located half-way on a line drawn from the umbilicus to the anterior

* The hand dynamometer can be secured from The Narragansett Machine Co., Providence, R. I.

superior spine, and represents the point of greatest tenderness in appendicitis. Locate this landmark with a skin pencil.

11. Study famous figures, *e. g.*, "The Discobolus," "Venus of Milo," and note the trunk muscles. What would you infer regarding the development of the trunk muscles in "The Winged Victory"?

QUESTIONS

1. Define origin and insertion as applied to muscles. Give an illustration.
2. What is the difference between a tendon and a ligament?
3. Why does moderate exercise remove the waste material from the tissue spaces?
4. Give illustrations of tonic, static, concentric, and eccentric muscular contraction.
5. What form of contraction is most favorable for the flow of blood?
6. In twisting the trunk to the left, what abdominal muscles are used?
7. The rectus abdominis is marked by fibrous intersections. What phylogenetic suggestion does this give of the character of the trunk muscles in primitive forms?
8. What are the distinguishing characteristics in muscular strength between men and women, children and adults?
9. What muscles are important in maintaining the arch of the foot?
10. What method of walking will develop and strengthen the muscles of the foot?

REFERENCES FOR FURTHER STUDY

1. Tyler, J. M.: Growth and Education, Houghton, Mifflin Co., Boston, 1907, Chaps. I–IV.

2. Goldmark, J.: Fatigue and Efficiency, Russell Sage Foundation, 1917. Lee, F. S.: Human Machine in the Factory, Harvey Lectures, Harvey Society of New York, 1920. Thorndike, E. L.: Mental Fatigue, Psychological Review, vol. vii, No. 6, 1900.

3. Transactions Fourth International Congress on School Hygiene, vol. v, pp. 10, 23, 37. Journal American Medical Association: April 10, 1915, p. 1208; May 15, 1915, p. 1663; July 3, 1915, p. 26; March 18, 1916, p. 893; July 7, 1917, p. 16; December 14, 1918, p. 1980; January 17, 1920, p. 151; July 24, 1920, p. 237.

4. Hastings, W. H.: Manual for Physical Measurements, Y. M. C. A. Training School, Springfield, Mass., 1902.

5. Hall, G. S.: Adolescence, D. Appleton & Co., New York, 1911, pp. 129–236.

6. Holt, L. E.: Diseases of Infancy and Childhood, D. Appleton & Co., New York, 1911, pp. 15–31.

7. For an interesting and helpful exposition of muscular action from an evolutionary viewpoint, see Mackenzie, W. C.: The Action of Muscles, Hoeber, New York, 1921.

CHAPTER VIII

THE NERVOUS SYSTEM—THE CORD

I. The Evolution of the Nervous System.
II. The Development of the Nervous System.
III. The Arrangement of the Neurons in the Nervous System.
IV. The Divisions of the Nervous System.
V. The Function of the Nervous System.
VI. The Spinal Cord:
    The Membranes of the Cord.
VII. The Spinal Nerves:
    1. Structure of the Spinal Nerves.
    2. Plexuses of the Spinal Nerves.
    3. Terminations of the Spinal Nerves.
VIII. Structure of the Cord:
    1. Tracts of the Cord.
    2. Degeneration of the Tracts.
IX. The Nerve Impulse.
X. Type Reactions in the Nervous System:
    1. Connections of the First Level.
    2. Connections of the Second Level.
    3. Connections of the Third Level.
    4. The Action of Anesthetics.
XI. Education of the Reflexes.
XII. Reflexes of the Cord:
    Tabulation of Common Reflexes.

The Evolution of the Nervous System.—The fundamental units of the nervous system consist of a sensory and motor neuron (see Fig. 13). In simple forms of animal life the neuron is the unit of structure in precisely the same way that it is the unit in that most complex of all nervous structures—the nervous system of man. Such mechanism enables the organism to *receive* impulses from the world of its environment and *to send* impulses to its effect or mechanism, *e. g.*, muscles and glands, in responding to stimuli received. Whether in the simpler animals, such as hydra, or in man, an incoming and an outgoing neuron are essential. Such type of nervous system is adequate in simple organisms, but with complex organisms co-ordination becomes tremendously important. Hence, it is found that in the segmented animal, where there is great need for co-ordination between segments, the meeting-place of the neurons forms a central mass for

each segment. The central masses of nerve tissue are bound together, giving unity and continuity, and come to be the center for all nervous activity (Fig. 192). These central masses are the beginning of the spinal cord, and the forepart, becoming increasingly differentiated, develops into the brain.

Fig. 192.—A human fetus three months old, dissected from the dorsal surface to expose the brain and spinal cord. Natural size. (From Kölliker.)

As the evolution of animal life proceeded the brain portion of the nervous system increased rapidly (Fig. 193) until in man cerebral activity took a dominant place in functions of the nervous system. Hence, a principal difference between lower animals and man is the profound development of the brain in the latter. This great growth of the brain in man has not destroyed the activities of the other central masses that composed the cord. Such neuron connections providing for reflex activities are still important and necessary to life, but they are dominated by the psychic activities of the brain. These psychic activities constitute a manifestation of intelligence,[1] which is generally considered peculiar to man.

The Development of the Nervous System.—The different parts of the nervous system develop harmoniously with the other organs of the body. It should be recalled that the ectoderm gives rise to the central core of nerve tissue (page 41) by a process of infolding of two ridges that appear at an early date in the embryo. The fore portion increases rapidly and in the early weeks the brain shows pronounced development (Fig. 99). With the closure of the neural tube there occurs a proliferation of the cells to form the cord. The growth of organs and extremities takes neural elements along with the other tissues as they develop. This process is so complete that every organ of the body is supplied with nerves, and so thorough is the distribution throughout the body that only a few structures are without nerves. Figure 194 shows a diagram of an embryo of thirty-one days. Notice in the illustration the large brain at this stage with the attached cranial nerves, and the spinal cord and spinal nerves. The

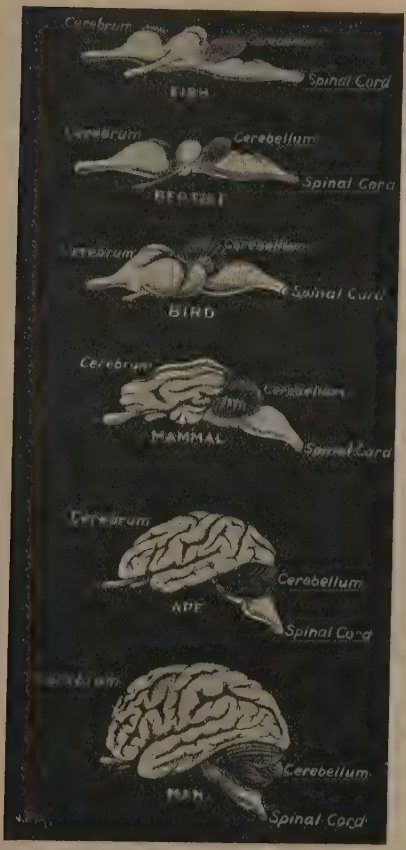

Fig. 193.—This drawing shows the evolution of the brain from fish to man. The cerebrum, the seat of intelligence, increases in proportion to the other parts. In mammals it becomes more and more convoluted. The brain, which lies on one plane in fishes, becomes gradually curved on itself. In birds it is more curved than the drawing shows (Thompson).

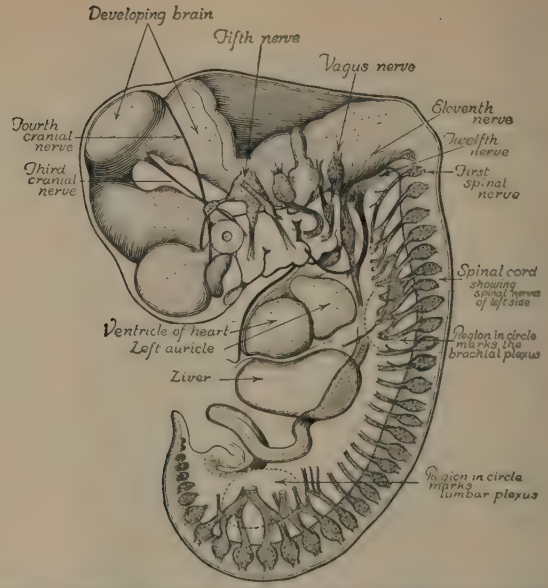

Fig. 194.—Diagram of early embryo to show developing nervous system at thirty-one days. Note cranial and spinal nerves coming off from brain and cord. (Marshall.)

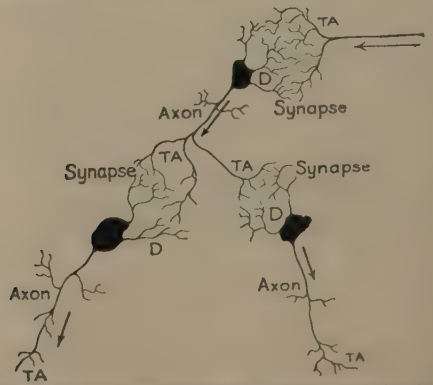

Fig. 195.—Diagram of three synapses. Nerve impulse is indicated by arrows, showing that the direction of passage is from terminal arborization (TA) of axon of one neuron to dentrites (D) of another neuron.

heart and liver are conspicuous for their size; the early coils of the alimentary canal are also shown.

The Arrangement of the Neurons in the Nervous System.—The neurons* of the nervous system are its functional units. They vary in shape and size, but are alike in having a *cell body*, one long branching process called an *axon*, and many other filaments called *dendrites*. The cell bodies of the efferent neurons lie in the gray matter of the cord and brain—gray because of the presence

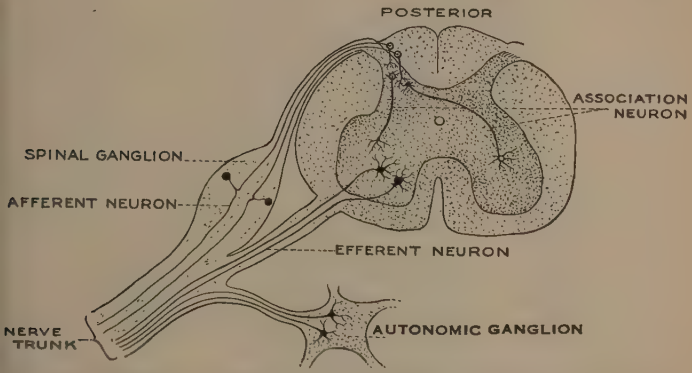

Fig. 196.—Diagram to show the composition of a peripheral nerve-trunk, synapses in the cord, and the arrangement of neurons.

of the cell bodies of nerve-cells in contrast to the white matter which contains only the processes. The cell bodies of afferent neurons lie in ganglia outside the cord for the spinal nerves and within the brain for the cranial nerves. These two units are connected in cord and brain by an association neuron. The junction place of connecting neurons is called a *synapse* (Figs. 195 and 196). A synapse, then, is the meeting place of the endings of the axon of one neuron with the dendrites of another. It is a place where neurons function with other neurons. The character of the endings of neurons has been described on page 86.

* Neurons carrying impulses from the brain or cord to the periphery are called *efferent*. These are outgoing impulses and may be motor or secretory. Neurons carrying impulses from sense receptors in skin, organs, and special receiving apparatus, *e. g.*, the eye, to the brain or cord are called *afferent*. These are incoming impulses and are always sensory. Neurons that serve to connect efferent and afferent units are called *association* neurons.

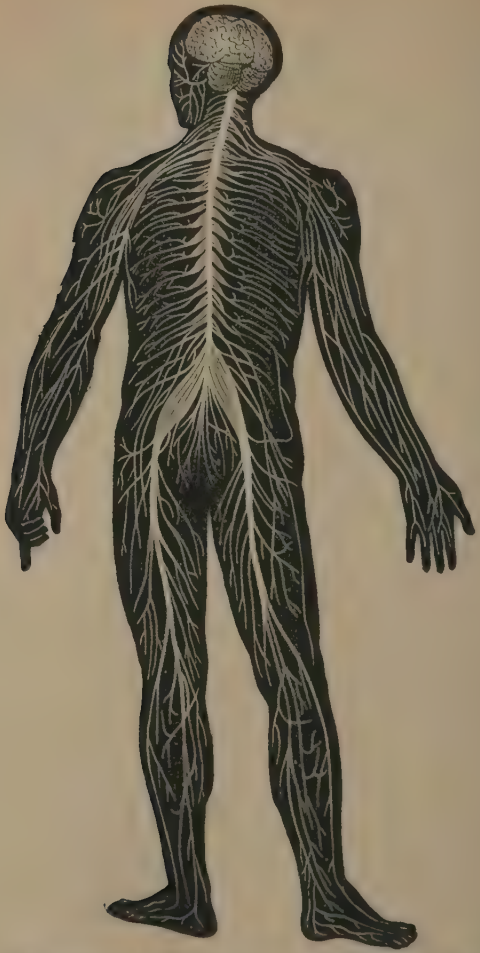

Fig. 197.—The general arrangement of the cerebrospinal nervous system (viewed from behind), showing the brain, the spinal cord, and the chief nerves that branch from it. No portion of the autonomic nervous system is shown in this diagram. (From Williams, Healthful Living, published by The Macmillan Company.)

The Divisions of the Nervous System.—The nervous system has two main divisions—the cerebrospinal and the autonomic.* The former (Fig. 197) includes the brain with all its ganglia and nerves, and the spinal cord with its ganglia and nerves; the latter

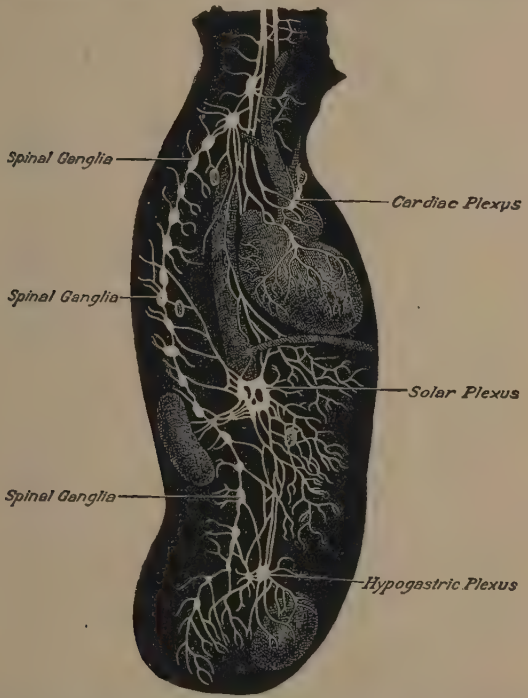

Fig. 198.—Diagram of trunk showing one of the two rows of autonomic ganglia near the spinal column and the plexuses. The ganglia are quite variable in size. No portion of the cerebrospinal nervous system is shown in this illustration. (From Williams, Healthful Living, published by The Macmillan Company.)

Figs. 198 and 238) includes the ganglia along the vertebral column, the mesenteric ganglia, and the ganglionic masses in the walls of the viscera. Similar structures are found in the head

*Langley has suggested the use of the term "autonomic" for what has been known formerly as the sympathetic nervous system. This usage is extending and is adopted in this book.

associated with visceral structures, *e. g.*, salivary glands (see pag 400).

The Function of the Nervous System.—Study of the evolutio of the nervous system suggests at once its functional place in th human body.[2] The vast connections of this system with all part of the body indicate the possible channels through which in formation is received on the state of the environment, and on th condition of the different organs engaged in carrying on th processes of life. Fashioned together as one structure, intimatel connected and related in all its parts, the brain and spinal cor serve admirably the function of directing, co-ordinating, an controlling the activities of the cells of the body. The nerves o the system are merely the pathways by which messages ar brought to the central station, and directions are sent out to th outlying agents that will put into effect the orders received. Thi provision for co-ordinated harmonious action prophesied in th segmented worm finds in man its greatest development. Thus the flow of the blood, the secretion of the digestive juice the movements of muscles, the removal of waste products, th thought processes of the cerebrum, and the responses of th emotions are all under the supervision of this structure the nervous system. The autonomic system is in direct control o the metabolic activities of the body, is closely allied with th endocrine organs, and is identified with the emotions. Th cerebrospinal nervous system is concerned with voluntar movement and with all the activities of consciousness. The mai divisions of the cerebrospinal nervous system are the peripher nerves (spinal and cranial), the brain, and the spinal cor

The Spinal Cord.—Within the neural canal of the vertebr column is the spinal cord, composed of thirty-one segments nerve tissue presenting a pair each of spinal nerves (Fig. 199 In man there are no constricting divisions marking the differen segments, all being fused into one long structure. Below, th cord terminates in a pointed ending, the *conus*, at the level of th disk between the first and second lumbar vertebræ. Above, it i continuous with the medulla oblongata of the brain, this transi tion occurring at the level of the foramen magnum. The cord i surrounded by fluid, the *spinal fluid*, and is covered by mem branes attached to processes of the vertebræ.

The *membranes of the cord* (Fig. 200) are three in number the *dura mater*, the *pia mater*, and the *arachnoid*. The dura is

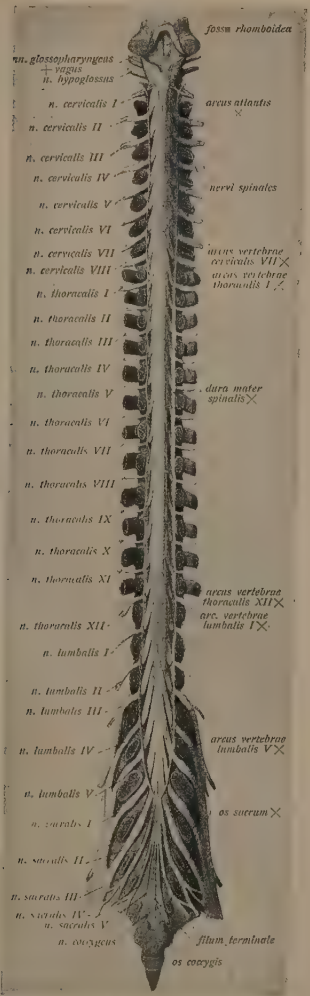

Fig. 199.—The spinal cord exposed in the spinal canal by the removal of the vertebral arches and of the dura mater (Sobotta and McMurrich).

strong, fibrous, vascular covering loosely attached to the periosteum of the canal in various places. The pia is much more delicate in structure than the dura and closely invests the cord. Between the two is the arachnoid, which is attached by fibrous bands to the dura. The three membranes are continuous with similar coverings of the brain.

Between the arachnoid and dura in the cord is the *subdural space*, which contains a small amount of lymph-like fluid. This

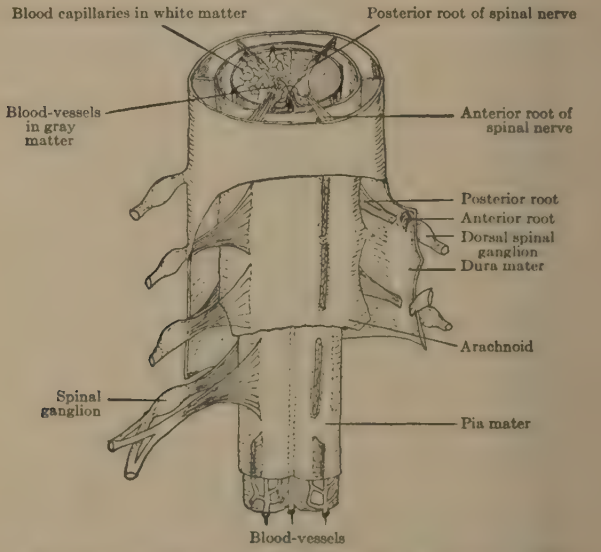

Fig. 200. Portion of spinal cord and membranes dissected (Hill).

connects with the lymph vessels of the spinal nerves. Between the arachnoid and pia is the *subarachnoid space*, which contains the *spinal fluid*. This space is continuous with a similar one in the skull, and hence, also, with the *cerebral fluid*. Commonly, in referring to this fluid, its location is indicated by the term *cerebro-spinal fluid*. The central canal of the cord and the cavities of the brain, also, contain a fluid. These cavities and this fluid within the cord and brain are in direct communication with the space and

luid outside the cord and brain by means of small openings in he pia mater that forms part of the roof of the fourth ventricle.

The Spinal Nerves. The thirty-one pairs of spinal nerves re named from segments that give them origin. Thus, there re eight cervical, twelve thoracic, five lumbar, five sacral, and ne coccygeal. On emergence from the cord the spinal nerves ass out of the canal through the intervertebral foramina with the xception of the first cervical and the coccygeal. The former asses out through the opening between occipital bone and atlas;

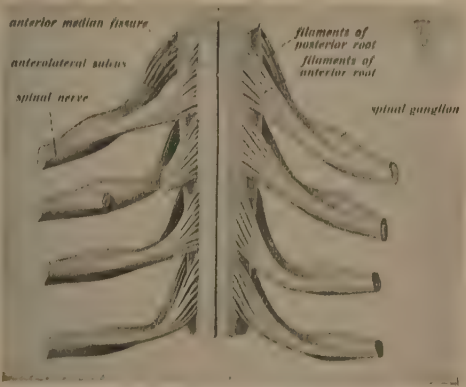

ig. 201. An anterior view of the spinal cord with the efferent roots of the nerves (Sobotta and McMurrich).

he latter emerges through the aperture at the tip of the coccyx.

Structure of the Spinal Nerves. The two attachments of the pinal nerves to the cord are called *roots* (Fig. 201), and are known s the *anterior* and the *posterior root*. The posterior root shows a welling called the dorsal ganglion, or the ganglion of the dorsal oot. A ganglion is always a group of nerve-cells. Microscopic xamination of the cord shows the following: the anterior root is ade up of axons from cell bodies that lie in the anterior gray natter of the cord; the posterior root contains the axons and endrites of cell bodies which lie in the posterior root ganglion. unctionally, the posterior root contains afferent neurons carrying messages from the peripliery to the cord; the anterior root con-

tains efferent axons carrying outgoing impulses to muscles and glands (Fig. 202). Hence the posterior root is often called sensory, and the anterior one motor and secretory.

Soon after emergence from the cord the anterior and posterior roots join to form the *trunk* of the spinal nerve.

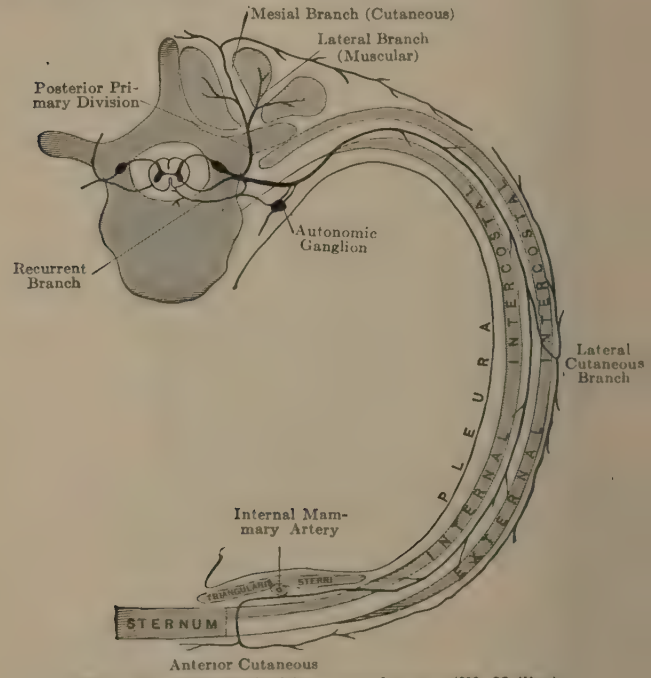

Fig. 202.—Plan of a typical intercostal nerve (W. Keiller).

A nerve trunk will be composed of efferent axons of motor or secretory cells situated in the anterior gray of the cord, of afferent dendrites of sensory neurons whose cell bodies lie in the posterior ganglion, and of efferent axons of neurons in autonomic ganglia. These fibers (axons and dendritic processes) are grouped in bundles called *funiculi*. These vary in size and number. Each funiculus is invested with a sheath of connective tissue called *perineurium*, and together with blood-vessels are

bound by a looser connective tissue, the *epineurium*, to form the nerve trunk (Fig. 203).

Plexuses of the Spinal Nerves.—After the junction of the anterior and posterior roots the spinal nerve may be considered as begun. Soon after this union there is a division into *anterior* and *posterior divisions* (Fig. 202). The posterior division is small. It sweeps backward to supply the posterior aspect of the trunk.

Fig. 203.—Part of a cross-section through a nerve trunk. The small circles represent the cross-sections of medullated nerve-fibers; the axis-cylinders show as points in their centers. (Böhm, Davidoff, and Huber, Histology.)

The anterior division is the main portion of the spinal nerve. Connection is soon given to the ganglia of the autonomic system destined to supply the visceral organs of the splanchnic area. The remaining portion of the anterior division passes to the walls of the chest and abdomen and to the extremities. In supplying the neck, arms, legs, anal and genital regions the spinal nerve

trunks are grouped, and the term *plexus* is given to these aggregations, hence the terms *cervical plexus, brachial plexus* (Fig. 204), *lumbar plexus, sacral plexus,* and *pudendal plexus.* After passing for some distance in the plexus the spinal nerve breaks up into

Fig. 204.—Plan of the brachial plexus: *A*, Fifth cervical; *B*, sixth cervical; *C*, seventh cervical; *D*, eighth cervical; *E*, first dorsal; *F*, postthoracic; *G*, internal anterior thoracic; *H*, external anterior thoracic; *I*, middle subscapular; *J*, lower subscapular; *K*, levator anguli scapulæ; *L*, suprascapular; *M*, upper subscapular; *N*, circumflex; *O*, musculocutaneous; *P*, median; *Q*, musculospiral; *R*, ulnar; *S*, internal cutaneous; *T*, lesser internal cutaneous. (Campbell.)

individual nerves receiving distinctive names, usually relative to the part supplied.

Terminations of the Spinal Nerves.—The endings of the spinal nerves are designed especially to receive from and to deliver to the body cells impulses going to or from the cord.* These

* Certain spinal nerves distributed to the trunk bear a relation to the organs of the abdomen due to the innervation of abdominal viscera as well as the skin and muscles of the abdominal wall by the sixth to the twelfth thoracic and the first lumbar segments of the cord. Hence, pain impulses from diseased viscera are referred to certain areas of the trunk surface.

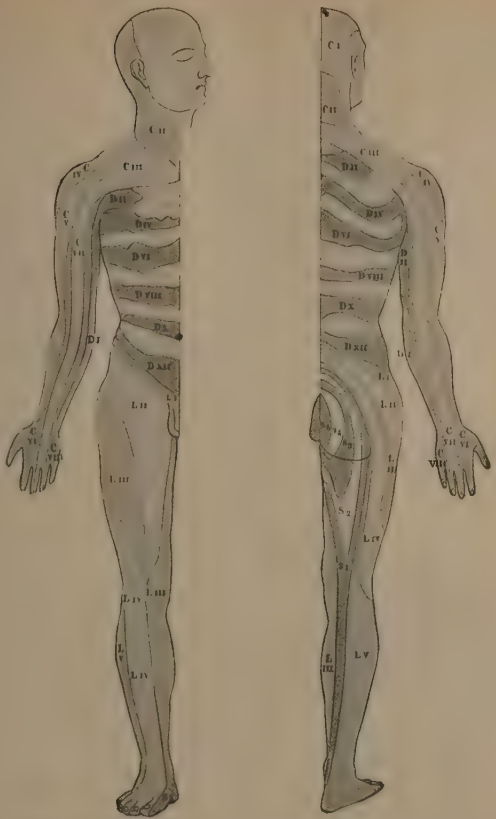

Fig. 205.—The segments of the cord are numbered *C* I to VIII, *D* I to XII, *L* I to V, *S* I to V, and these numbers are placed on the region of the skin supplied by the sensory nerves of the corresponding segment (Starr).

These areas have been indicated by Head as follows:

1. The sixth, seventh, eighth, and ninth thoracic segments with the stomach.
2. The ninth, tenth, eleventh, and twelfth thoracic segments with the intestinal tract.
3. The seventh, eighth, ninth, and tenth thoracic segments with the liver and gall-bladder.
4. The tenth, eleventh, and twelfth thoracic, and the first lumbar segment with the kidney and ureter.
5. The second, third, and fourth sacral with the rectum.

endings are highly specialized and are known as end organs. The end organs of the afferent nerves are called *receptors;* the end organs of the efferent nerves, *effectors*. The receptors are located



Fig. 206.—End-bulb of Krause from conjunctiva of man; methylene-blue stain (Dogiel, Arch. f. mik. Anat., vol. xxxvii).

chiefly in the skin (Fig. 205) muscles, tendons, joints, and mucous membranes. They are the specialized dendritic processes (Figs. 206, 207) of neurons whose cell bodies lie in the posterior

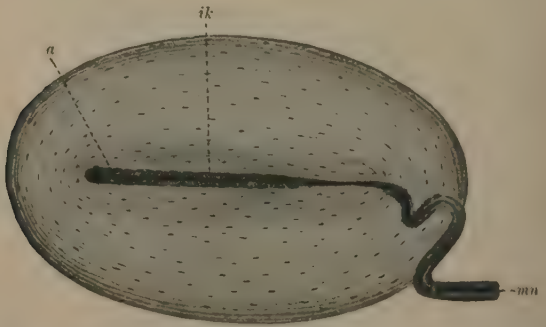

Fig. 207.—Vater-Pacinian corpuscle from the mesentery of a cat; × 45. The figure shows a general view of the corpuscle: *a*, Axis-cylinder in the core; *ik*, core; *mn*, medullated nerve-fibers entering the core. (Sobotta and Huber, Atlas and Epitome of Human Histology.)

root ganglion. The effectors (Fig. 208) are the specialized endings of the axons whose cell bodies lie in the anterior gray of the spinal cord.

Structure of the Cord.—The paired spinal nerves emerging from the lateral aspects of the cord suggest its developmental history, and the minute internal structure more clearly explains

how the cord affords numerous centers for the nerves of the different segments (Figs. 209–212). The cut surface of a transverse section shows a bilaterally symmetric structure nearly divided by a median fissure in front and behind (Fig. 209), the *anterior median fissure* and the *posterior median fissure*. A darker, gray appearing central mass stands out from the prevailing white tissue dening the *gray* and *white matter* of the cord. The gray is made up largely of the cell bodies of efferent neurons indicating their central location; the white is composed entirely of fibers showing its function as a connecting mechanism between

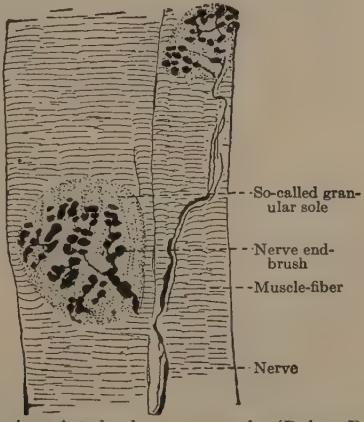

Fig. 208.—Motor endings in striated voluntary muscles (Böhm, Davidoff, and Huber).

the successive segments. This gray matter is seen to be closely connected with the nerves that emerge from the cord and serves a definite function in relation to these nerves. On each side of the median fissure the gray matter shows an *anterior horn*, *a central mass*, and a *posterior horn*. The anterior horn contains the cell bodies of the axons represented in the nerves that form the anterior root. The fibers of the posterior root enter the dorsal ganglion and then proceed into the cord to make connections near the posterior horn. The central gray contains neurons that serve as association units connecting posterior and anterior horns and the opposite halves of the gray. Where the axons of the central gray pass to the opposite side they form the *anterior*

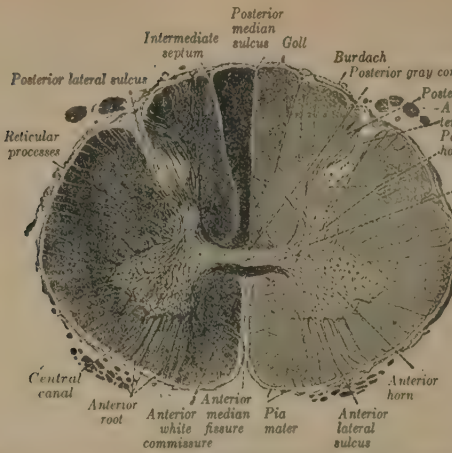

Fig. 209.—A cross-section through the cervical enlargement. (Magnified 8 times.) (Sobotta and McMurrich.)

Fig. 210.—A cross-section of the lower thoracic cord. (Magnified 8 times.) (Sobotta and McMurrich.)

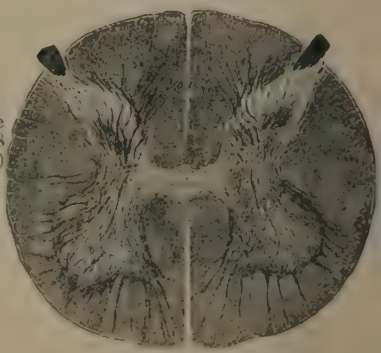

Fig. 211.—A cross-section of the lumbar enlargement. (Magnified 8 times.) (Sobotta and McMurrich.)

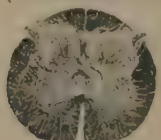

Fig. 212.—A cross-section through the lowermost portion of the lumbar cord. (Magnified 8 times.) (Sobotta and McMurrich.)

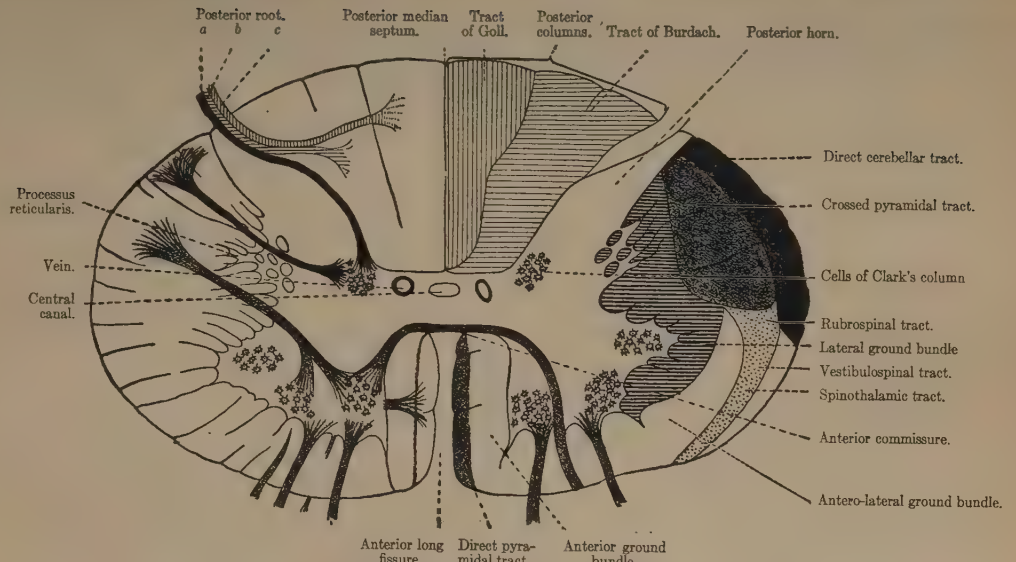

Fig. 213.—Schematic cross-section of the spinal cord tract. *a*, *b*, and *c*, Bundles of the posterior nerve-root (arranged after Ziehen from von Bardeleben and Haeckel).

commissure in front of the *central canal* and the *posterior commissure* behind it.

The proportion of white and gray matter vary in different regions of the cord. In the cervical and lumbar regions the gray is greatly increased, making the *cervical* and *lumbar enlargements*. These enlargements are due to the greater number of cell bodies necessary to supply nerves for the arms and legs. The white matter is composed of fibers coming from the periphery to the cord and brain, or from the brain and upper structures to the lower segments. It follows that each fiber in the white matter must be the axon of some nerve-cell. The cell bodies of these axons are situated in the brain, in ganglia on the posterior roots, or in the gray matter of the cord.

Tracts of the Cord.—The white matter of the cord is composed of axons of nerve-cells. These fibers are grouped in columns called tracts, and exhibit a functional as well as an anatomic unity. Some start from the cells in the posterior root ganglia, some from the brain, and others begin from different segments of the spinal gray. They may be classified according to the direction of the impulse into ascending and descending tracts. The following includes the main pathways (Fig. 213):

Ascending Tracts:

1. Posterior column tracts (Goll and Burdach). These tracts are made up of the axons of cell bodies in the posterior root ganglia. The fibers nearest the posterior horn have recently entered the cord. The ones near the posterior fissure have come into the cord at a lower level. All of these fibers end in the *nucleus cuneatus* and *nucleus gracilis* in the medulla, where the impulse relays by a synaptic connection with the second neuron of this great sensory pathway to the brain. This tract conveys kinesthetic impulses relating to voluntary muscle sense and discriminating touch. The neuron connections are shown in Fig. 214.

2. Direct cerebellar tracts lie in the lateral part of the white matter. Its fibers arise in the cells of Clark's column (Fig. 213). This tract is made up, then, of second neurons, since Clark's column receives the terminal arborizations of axons from the posterior root ganglia. The tracts continue up-

ward to the cerebellum, conveying impulses of reflex muscular tone and unconscious co-ordination.

3. Spinothalamic tracts lie in the anterior lateral part of the white matter. They pass to the thalamus and are relayed to the brain, carrying impulses of pain, temperature, and pressure (touch). They also convey impulses of muscle sense.

Ascending Tracts:

4. Other tracts located in the lateral and anterior ground bundles run from one cord segment to another serving as connecting pathways for different levels.

1. Pyramidal tracts come down in the lateral and anterior columns from the brain cortex to the anterior horn of the spinal gray where the fibers end at different levels around cell bodies of the efferent neurons to form the anterior root of the spinal nerves. Two pathways are used. The *crossed pyramidal* fibers make up the largest number. These cross from one side to the other in the medulla (Fig. 215), forming the *pyramids*, or *motor decussation*. The *uncrossed pyramidal* fibers pass down near the anterior fissure and later pass to the other side in the anterior commissure, when the synapse is to be made. These tracts explain why injury to the cell bodies in the cortex cause paralysis on the opposite side of the body. They carry motor impulses from the cerebrum.

Descending Tracts:

2. The rubrospinal tracts pass from the red nucleus in the thalamus via the white matter anterior to the crossed pyramidal tracts. They end around cells in the posterior part of the anterior horn. The red nucleus connects with the cerebrum, and hence this tract is considered an accessory to the main motor pathways.

3. Vestibulospinal tracts are scattered fibers in the antero-lateral part of the white matter. They pass from the nucleus of the eighth nerve in the medulla and end in the anterior gray. They convey impulses relating to equilibrium and the

adjustment of muscular action to the stimuli of the semicircular canals.

Descending Tracts:

4. Other tracts located in the lateral and anterior ground bundles run from one segment of the cord to another, serving as connecting pathways for different levels.

The relation of the sensory and motor tracts to each other is given by the complete neuron connections from the skin to the brain and from the brain to the muscles. This is well illustrated in Fig. 214. Starting with neuron (1), it is to be traced upward

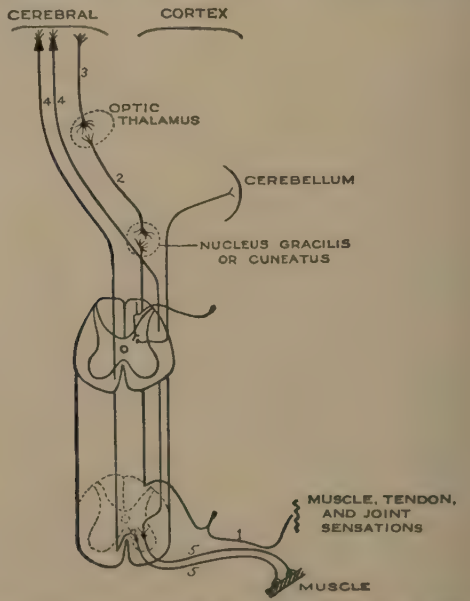

Fig. 214.—Diagram of neuron connections in afferent and efferent main pathway.

in the posteromedian and posterolateral columns to the nucleus gracilis or cuneatus. A second neuron (2) carries on the message from the first, making a crossing to the opposite side and relaying by a third neuron (3) again before reaching the cerebral cortex.

ıe motor route is indicated by neuron (4), which starts from the rebral cortex and passes down to the medulla without relay, ıere it crosses to the opposite, or it may continue on the direct thway and cross later in the anterior commissure. Ultimately makes a synaptic connection with a neuron in the anterior ay (5).

Degeneration of the Tracts.—When a portion of a cell is sepated from the part containing the nucleus the portion so sepa-

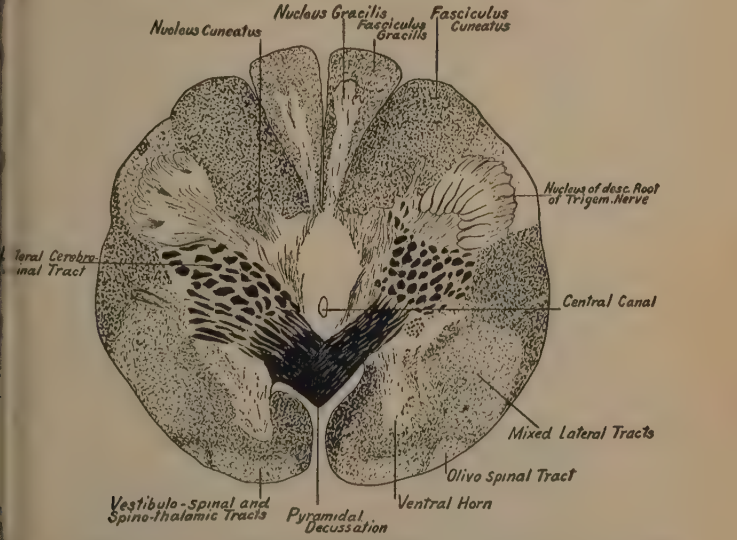

g. 215.—Section of the oblongata at the level of the motor or pyramidal decussation (Radasch).

ted dies. This holds true for nerve-cells as it does for other lls of the body. The axons represent portions of the cells; ıe cell body contains the nucleus. If from any cause the axon severed, the distal part undergoes degeneration (Fig. 216). egeneration takes place by growth of new fibers outward from ıe proximal portion into the old sheath.[3] Injury to the columns Goll and Burdach will show in degeneration of the tracts above ıe injury; injury of the pyramidal tracts will show degeneration the tracts below the injury.[4] Study a section of the cord

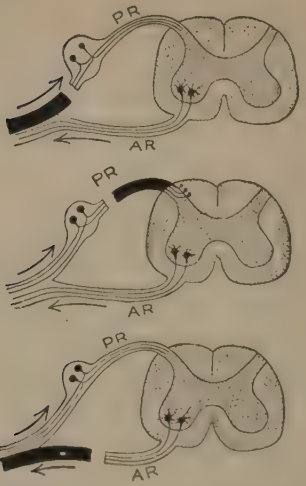

Fig. 216.—Diagram to show (black) the death of the fiber that is sever from the cell body. Arrows indicate direction of nerve impulse.

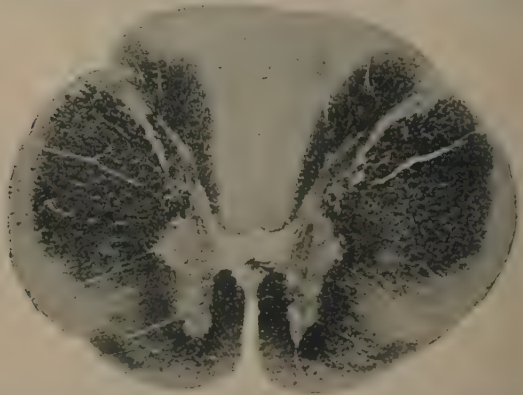

Fig. 217.—Ascending degeneration at the first dorsal segment after tra verse lesion of the fifth dorsal segment. The ascending degeneration affe all of the posterior columns excepting the root zone of the column of B dach. Also the direct cerebellar columns and columns of Gowers, and ma fibers in the anterolateral columns. A few degenerated fibers are se around the margin of the anterior median column (from Starr, Organic a Functional Nervous Diseases).

Fig. 217) and explain why the degeneration area does not involve all of the posterior columns.

The Nerve Impulse.—Nerve-cells by elaborate specialization develop a high degree of irritability and conductivity. The nerve impulse is a wave of irritability conducted along the nerve. It is received by the dendritic terminals, is elaborated by the cell body, and sent on its way over the axon. The exact nature of the wave is not known. In some respects it resembles an

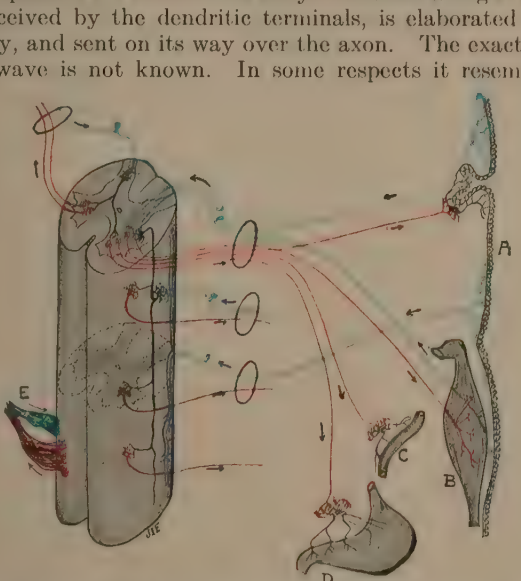

Fig. 218.—Diagram of the structures involved in a reflex action: *A*, receptive surface; *B*, skeletal muscle; *C*, blood-vessel and autonomic ganglion; *D*, a viscus and autonomic ganglion; *E*, spinal nerve attached to spinal cord. Red indicates efferent, and blue, afferent impulses. (Radasch.)

electric current, but its passage is very much slower.* Experiments have determined that a nerve cell body will give off carbon dioxid when stimulated, thus showing that metabolic processes are involved in the activity of the nerve impulse. There is physiologic evidence, therefore, that nerve-cells fatigue, and this bears out the layman's observation on this point.

* The nerve impulse in warm-blooded animals passes at a speed varying between 100 and 125 m. per second. It is interesting to note in this connection that light travels at about 186,000 miles per second and sound 1100 feet per second.

Type Reactions in the Nervous System.—In the foregoing th nature of the nerve impulse and synapse, the arrangement o neurons, and the structure of the cord have been set forth Important physiological functions have been indicated. Som

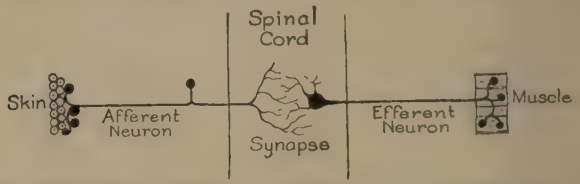

Fig. 219.—Mechanism involved in a reflex act, or a reaction of the firs level (after Gates).

facts regarding the organization of connections in the cord an brain remain to be described. These connections may b grouped in three levels.

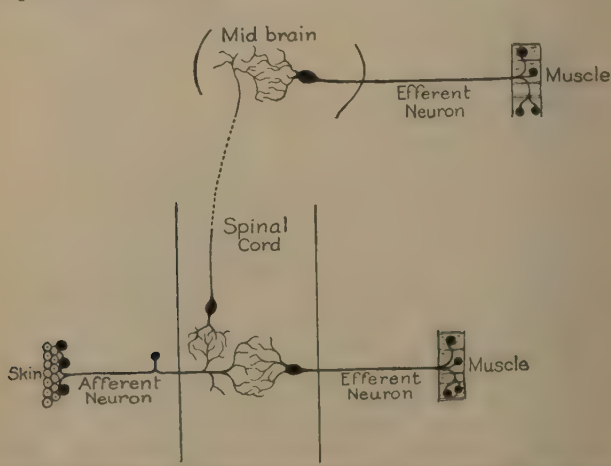

Fig. 220.—Mechanism involved in reaction of the second level added t that involved in first level (after Gates).

Connections of the First Level.—The simplest type of respons depends upon a receptor, afferent neuron, synapse, efferen neuron, and effector (muscle or gland). If one touches a ho object there is a contraction of the muscles of the part to remov

he part from the unpleasant situation. The circuit is commonly nown as a *reflex arc,* or *reaction of the first level* (Fig. 219). There re numerous illustrations of this reaction of the first level. n this circuit an impulse starting at the receptor travels over he dendrites to the cell body, from which point it is sent on to he terminals of the afferent neuron. These filaments are in elation* with the dendrites of an efferent neuron which in some ay receives an excitation from the afferent unit at the synapse. he efferent neuron then sets a wave going over its axon, and the timulation of the muscle cells in this case is the result. It is a ignificant fact that the nerve impulse is not reversible. It can nly pass from the terminal arborization of the axon to the endrites of another cell.

Connections of the Second Level.—The impulse coming in over he afferent route may engage only the efferent connections of he same level (Fig. 219). If the stimulus is strong enough to ause pain, there may be extension of the connection to the mid- rain. Thus a burn of the skin may excite not only withdrawal f the part but also cause the individual to cry out, to contract acial muscles, even to jump and to dance about, and to show ncreased heart action and respiration. These responses are xamples of *reactions of the second level* which are located in the anglia of the midbrain (Fig. 220).

Connections of the Third Level.—The higher centers of the rain are involved in connections of the third level. To the ituation in the preceding instance the individual may not only ithdraw the part, not only jump and cry out, but he may now pply treatment to the burn or take action to prevent a similar njury. Thus, in such response, reasoning functions are exercised nd the *reaction of the third level* is apparent (Fig. 221).

The Action of Anesthetics.—The anesthetics—ether, chloro- orm, and alcohol—act to block the passage of afferent impulses o the efferent pathways. This blocking probably occurs at the rst synapse in the cord. The exact nature of this "blocking" is ot known. Some theories propose a retraction of the filaments n the synapse; others state the change to be a chemical one.

* Just how the second neuron receives its stimulus from the first is not learly known. It is generally held today that there is physical contact etween the filaments of the two sets. There is not continuity, but the pproximation is believed to be close (Ladd and Woodworth, Elements of hysiological Psychology, p. 112, and Burton-Opitz, Text-book of Physiol- gy, p. 110).

In effect it results in decreasing the conductivity of the synapse The effect of cocain is local on the receptors, and prevents t stimulus from passing along the afferent neuron.

Education of the Reflexes.—The general reflex character numerous bodily reflexes has been noted. They represent co control and cord activity. The development of the cerebru

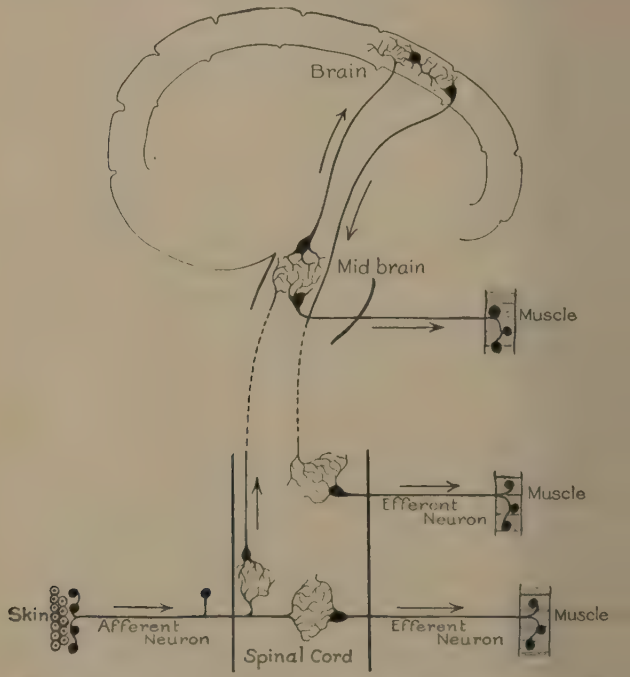

Fig. 221.—Mechanism involved in reaction of third level added to th involved in first and second levels (after Gates).

however, makes possible a modification of cord response a hence a modification of the reflex by act of will. In man, education and training, the simple reflexes of micturitio defecation, etc., are modified by messages from the cerebru

* Ladd and Woodworth, Elements of Physiological Psychology, Char Scribner's Sons, New York, 1911, pp. 284-293.

dicating the appropriateness of time and place. Children can e trained at an early age so that micturition and defecation will ecome habituated under certain conditions. Regularity in ving the appropriate situation will tend to evoke the typical sponse. Assisted by proper conditions of feeding, the bladder nd bowel may not be unduly distended at inappropriate times nd hence ready to act at the proper time. After proper train-g these reflexes are under control of the cerebrum which may xercise complete domination, although the reflex may at times e strong enough to overcome cerebral inhibition, causing oiding or evacuation in spite of the desire not to so act. In stances of disease of the nervous system, as in locomotor axia or paresis, the cerebral inhibitory impulses may be unable reach the cord or the sensory impulses reach the brain, so that oiding and evacuation occur under the simple reflex conditions hat exist among the lower animals.

Reflexes of the Cord.—The spinal cord contains the synapses the neurons of the reflex circuit or reactions of the first level. n some of the lower animals, particularly amphibians and eptiles, certain cord segments control the reflexes of parts of the ody related to the cord segmentally. This condition persists in an, and hence a vast number of reflexes take place involving nly the afferent neuron, association neuron of the cord, and ferent neuron. Consciousness of the act may be present due the continuation of the afferent impulse to the brain and nvolvement of the third level.

Reflexes of the cord are related not only to muscular move-ents. The autonomic system, particularly in the thoracic and acral segments, shows a series of reflexes involved in the action f the digestive, respiratory, circulatory, excretory, and geni-o-urinary tracts (Fig. 218). Anatomically and physiologically here is close association between the emptying and conserving unctions of the autonomic ganglia and the spinal cord centers. n organ within the abdomen may give such afferent impulses hat they flow over into the cord, resulting in reponses in the uscles of the trunk. Thus, in an inflammation of the appendix, here is frequently an increased tonicity of the abdominal muscles ver the right inguinal region giving the sign of "rigidity." Common examples of reflexes relating to internal organs are icturition, defecation, coughing, and the flow of digestive uices. It must not be supposed that reflexes are confined to the

cord. Many common examples are found in the activities of the cranial nerves. Thus sneezing, closure of eyelids, dilation, and constriction of the pupil are examples of reflexes of the cranial nerves.

TABULATION OF COMMON REFLEXES

	How elicited.	Response.	When present.
Abdominal reflex:	Rapidly drawing blunt end of rod-like instrument across abdomen.	Contraction of abdominal muscles.	Variable in infants under one month. Present after that date usually
Achilles' reflex:	Foot is placed in flexion and tendo Achillis tapped.	Extension of the ankle.	Often absent in the newborn. Only 34 present out of 100 newborn infants examined.
Anal or gluteal reflex:	Stimulating the skin covering the buttocks.	Contraction of the sphincter and gluteal muscles.	Present at birth, but only for the sphincter
Ankle reflex:	Quick flexion of the foot.	Extension of the foot.	Absent in healthy newborn infants. Found often with parental alcoholism.
Cremaster reflex:	Gently rubbing the inner aspect of thigh.	Retraction of the testicle.	Present in infants. Gundobin reported it present in 244 out of 252 infants under one month
Jaw reflex:	Tapping the lower jaw, mouth half-open.	Closure of the jaws.	Absent at birth.
Palmar reflex:	Placing finger or small rod in hand.	Closure of hand.	Present at birth, but disappears in later life.
Patellar reflex:	Tapping the quadriceps tendon of the knee crossed over other knee.	Extension of the knee.	Present at birth, but the center exhausts easily. After a few responses the reflex disappears.
Pharyngeal reflex:	Touching the posterior pharyngeal wall.	Contraction of pharyngeal muscles. Gagging.	Present early.
Plantar reflex (Babinski):	Tactile stimulation of the sole.	Flexion of the toes. Extension of the large toe is the Babinski phenomenon.	Babinski sign present at birth, and even up to nine months, especially in premature infants. Replaced in health by the normal response.

PRACTICAL EXERCISES

1. A congenital condition of deficiency in the vertebræ gives rise to an exposure of the spinal cord. The condition is called *spina bifida*.[5] Usually there is protrusion of the cord or its coverings (Fig. 222), so that a tumor is present in the middle line of the back. It is most common in the lumbosacral region. What coverings would such a tumor have?

2. The spinal cord in the adult usually ends below the level of the disk between the first and second lumbar vertebræ. Spinal puncture for the withdrawal of serum or the giving of medication is made at the level of the

Fig. 222.—Spina bifida (Campbell).

disk between the third and fourth or fourth and fifth lumbar vertebræ. Locate these points.

3. Test out the various reflexes of the cord.

QUESTIONS

1. Describe the spinal cord. What simple type of nervous system does it correspond with in structure? Does its function indicate a similar relationship?

2. What phylogenetic character do the thirty-one paired spinal nerves suggest?

3. What site is selected for spinal puncture? Why?

4. Why is the central gray larger in the cervical and lumbar regions than it is in the thoracic?

5. In ascending tracts of the cord, where are the cell bodies of the neurons involved? Where are the cell bodies of the fibers forming the descending tracts? Describe the main tracts.

6. What is a ganglion? Where is the dorsal ganglion?

7. What is the brachial plexus?

8. What are receptors? Effectors? Where are the cell bodies of receptors situated in the hand? In the foot? Where are the cell bodies of effectors situated in the triceps muscle? In the rectus abdominis? In the gluteus maximus?

9. What is a nerve impulse?

10. Study Fig. 217 and tell why all the fibers in the columns of Goll and Burdach are not degenerated.

11. Can an idiot be trained easily to control the reflexes? Explain your answer.

12. What is the reaction time? What is a reflex act? Describe reactions in the three levels and give illustrations of each.

REFERENCES FOR FURTHER STUDY

1. (*a*) Psychologic:

Pintner and Paterson: A Scale of Performance Tests, D. Appleton & Co., 1917. A series of tests for measuring general intelligence independent of language ability, especially valuable for use with the foreign born, illiterate, speech defectives, and the deaf.

Terman, L.: The Measurement of Intelligence, Houghton, Mifflin Co., 1916. An explanation of and a complete guide for the use of the Stanford Revision of the Binet-Simon Scale, the most widely used individual general intelligence test for school children.

(*b*) Educational:

McCall, W. A.: How to Measure in Education, The Macmillan Co., N. Y., 1922. Complete presentation of educational tests.

2. Williams, J. F.: Personal Hygiene Applied, W. B. Saunders Co., Philadelphia, Pa., 1928, pp. 323–351.

3. Stookey, B.: Surgical and Mechanical Treatment of Peripheral Nerves, W. B. Saunders Co., Philadelphia, 1921.

4. Burton-Opitz, R.: Text-book of Physiology, W. B. Saunders Co., Philadelphia, Pa., 1920, pp. 117–124.

5. Adami, J. G.: Principles of Pathology, Lea & Febiger, Philadelphia, Pa., 1908, pp. 246, 247.

CHAPTER IX

THE NERVOUS SYSTEM—THE BRAIN

I. A Compound Type of Nerve Action.
II. The Brain:
  1. Weight of the Brain.
  2. Growth of the Brain.
III. General Characteristics:
  The meninges.
IV. Divisions of the Brain:
  1. The Medulla Oblongata—Function of the Medulla.
  2. The Pons Varolii.
  3. The Cerebellum—Function of the Cerebellum.
  4. The Cerebrum.
  5. The Ventricles.
V. Tracts of the Brain:
  1. The Association Tracts.
  2. The Commissural Tracts.
  3. The Projection Tracts.
VI. The Brain Areas:
  Motor, Sensory, Visual, Auditory,
  Smell and Taste, Speech and Writing.
VII. Brain Activity in Children.
VIII. The Cranial Nerves.
IX. Nerve-centers.

A Compound Type of Nerve Action.—In animals with a spinal cord composed of different segments there arises at once a possibility of an afferent impulse coming to one segment being relayed to higher or lower units in the series causing action in some other part of the body. This is the type that so frequently occurs in the human body. An irritation on the leg will cause the hand to be moved to relieve the leg from the annoyance. Reflexes may occur involving different segments (Fig. 218). Under this condition there is the necessity for co-ordination of the different segments looking to unified and harmonious action of the entire body. Hence the development of the head ganglion as the directing and controlling unit of the entire system is the natural result. In animals with a brain this head ganglion manifests such control; in man the human brain has developed this quality to a high degree.

The Brain.—This in man is an elaborate development of the head end of the neural tube. Its expansions, convolutions, and centers are simply differentiated portions of the same kind of tissue that makes up the spinal cord in man and that forms the brain of other animals. In animals which have the power of association the forepart of the brain undergoes pronounced enlargement; in types such as fishes in which there is little association of the impressions received from the environment, the forepart of the brain remains small (Fig. 193). Fundamentally then the brain must be viewed as an organ for receiving impulses from the outside world of the environment, for association and elaboration of the impulses so received, and for reacting to them in a fashion that meets with the approval of the higher directing centers* of the brain. It also manifests control over the spinal cord, the older and more fundamental part of the nervous system. The brain is informed of the state of the environment by the receptors of the cranial nerves. These are very highly developed in relation to the organs of special sense, situated mainly in the head. It is also informed by the impulses that come into the cord and relayed to the brain. From all these sources the brain on the basis of past experiences guides and directs the actions of the individual.

Weight of the Brain.—The human brain is heavier than the brain of any other animal except the elephant and the whale. There have been many observations of the weight of the human brain of the two sexes. Handmann's figures† follow:

BRAIN WEIGHT IN GRAMS

Age.	Male.	Female.
4– 6 years	1215	1194
7–14 years	1376	1229
15–49 years	1372	1249
50–84 years	1332	1196

The relative brain weight in terms of the ratio between each centimeter of height and the brain mass is 8.3 in the male and 7.9 in the female, a slight advantage to the former. The brain reaches its full growth by the eighteenth year. There is no increase in weight after the twentieth year.

* These centers are largely trained by education.

† Quoted by Minot, C. S.: The Problem of Age, Growth, and Death, G. P. Putnam's Sons, New York, 1908.

Growth of the Brain.—For the first nine years the brain grows rapidly, but after that period it is considered by Vierordt as having reached approximately its full weight. The cells constituting the cerebral cortex and other parts of the central nervous system

Fig. 223.—To show the developing human cortex (Vignal), × 40 diameters: *A*, Fetus of twenty-eight weeks; *B*, fetus of thirty-two weeks; *C*, child at birth; *D*, man at maturity, *I–V*, layers of the cortex according to the enumeration of Meynert.

are formed before birth. During growth the increase in weight is probably due to development of cells, already present in actual form or as granules. Figure 223 shows the developing human cortex in the fetus, child, and mature adult. Figures of brain weight compiled by Vierordt show an increase up to nine years, after which there is a fairly constant weight:

Age.	Males.		Females.	
	Number of cases.	Brain, amount in grams.	Brain, amount in grams.	Number of cases.
Birth	36	381	384	38
1 year	17	945	872	11
2 years	27	1025	961	28
3 "	19	1108	1041	23
4 "	19	1330	1139	13
5 "	16	1263	1221	19
6 "	10	1359	1265	10
7 "	14	1348	1296	8
8 "	4	1377	1150	9
9 "	3	1425	1243	1
10 "	8	1408	1284	4
11 "	7	1360	1238	1
12 "	5	1416	1245	2
13 "	8	1487	1256	3
14 "	12	1289	1345	5
15 "	3	1490	1238	8
16 "	7	1435	1273	15
17 "	15	1409	1237	18
18 "	18	1421	1325	21
19 "	21	1397	1234	15
20 "	14	1445	1228	33
21 "	29	1412	1320	31
22 "	26	1348	1283	16
23 "	22	1397	1287	26
24 "	30	1424	1249	33
25 "	25	1224	1224	33

On the other hand, West, in the measurement of the heads of Worcester (Mass.) school children, found a steady growth in the length and breadth diameters from five to twenty-one years. Part of this growth is scalp and bone, but the figures given by West* agree more with the psychologic tests and practical observation of brain function than do those of Vierordt. The point, however, is not yet determined.

* Donaldson, H. H.: The Growth of the Brain. Charles Scribner's Sons, New York, 1912, p. 111.

General Characteristics.—When the brain is removed from the cranium (Fig. 224) it is observed to be in direct connection with the spinal cord. The upper end of the cord after passing through the foramen magnum becomes differentiated into the medulla oblongata. The main stem of the cord continues upward, marked by a quadrilateral shaped mass, the pons varolii, that

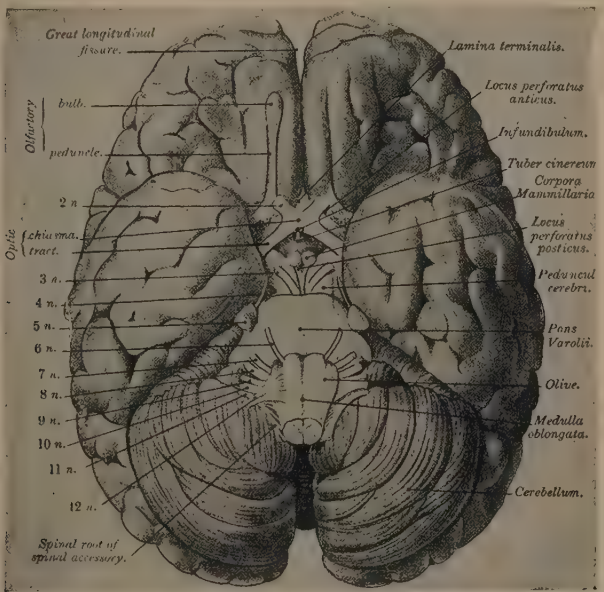

Fig. 224.—Base of the brain. Note the infundibulum above. The pituitary body is attached to this. (Whitaker, Anatomy of the Brain and Spinal Cord.)

rides across the main stem of the brain as a pack saddle. On either side, the edges of the pons are seen to disappear beneath the folds of the cerebellum that lies behind. A diagrammatic drawing of the relations of the cord, cerebellum, pons, and cerebrum (Fig. 225) shows that these structures are related primarily through the tracts that pass from one part to another. In short, the connection pathways are the significant features. Other interesting structures appear on a view of the under surface

(Fig. 224). The exits of the cranial nerves can be clearly seen, the pituitary body is observed just beneath the crossing of the optic nerves, and right in front are the two olfactory tracts and bulbs thrusting forward like the antennæ of some insect. The convolutions of the cerebrum and the limiting sulci are clearly evident on all sides.

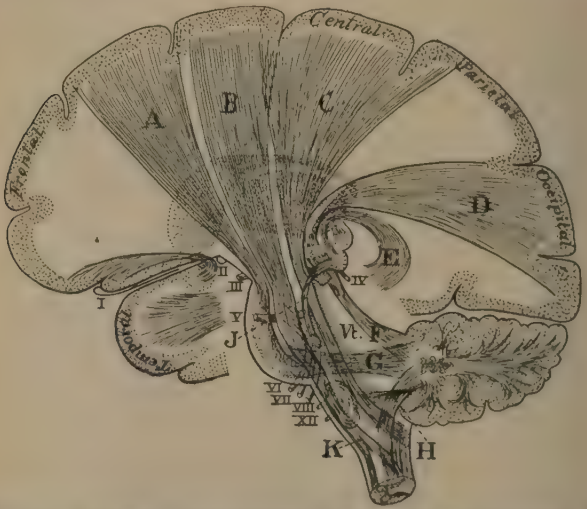

Fig. 225.—Schema of the projection fibers of the cerebrum and of the peduncles of the cerebellum; lateral view of the internal capsule: *A*, Tract from the frontal lobes to the pons nuclei, and so to the cerebellum; *B*, the motor (pyramidal) tract; *C*, the sensory (lemniscus) tract; *D*, the visual tract; *E*, the auditory tract; *F*, the fibers of the superior peduncle of the cerebellum; *G*, fibers of the middle peduncle uniting with *A* in the pons; *H*, fibers of the inferior peduncle of the cerebellum; *J*, fibers between the auditory nucleus and the inferior colliculus; *K*, motor (pyramidal) decussation in the bulb; *Vt*, fourth ventricle. The numerals refer to the cranial nerves. (After Starr.)

The Meninges.—The membranes of the brain, called the *meninges*, are a direct continuation of the coverings of the cord. The dura mater is a thick fibrous structure lining the inside of the cranium. It is in close contact with the periosteum of the cavity,* and sends flaps of its own structure downward between

* By some anatomists the periosteum and dura mater are considered as one structure.

the divisions of the brain to form supports for the cerebrum and cerebellum. One such partition lies between the two halves of the cerebrum (Fig. 112) and is called the *falx cerebri;* another, the *tentorium cerebelli*, rides as a tent over the cerebellum, giving support to the heavy lobes of the cerebrum above. At the superior margin of the falx cerebri and the lateral margins of the tentorium cerebelli the dura mater splits where it attaches to bone to form a channel for the venous blood. These are called sinuses.

The pia mater invests the brain substance holding a network of blood-vessels that supplies the brain tissue. Between the pia and dura is the arachnoid, that secretes the cerebral fluid serving

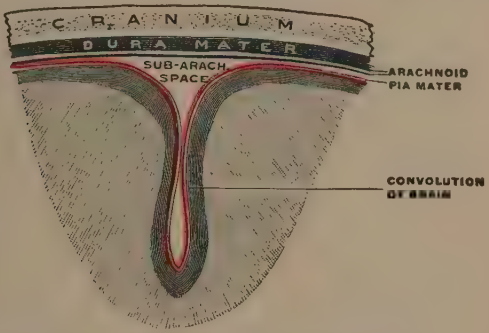

Fig. 226.—The three membranes of the brain (schematic) (Poirier and Charpy).

to lubricate all parts in the subarachnoid space. The relation of the three membranes are indicated in Fig. 226.

Divisions of the Brain.—The brain comprises four chief parts—the *medulla oblongata*, the *pons varolii*, the *cerebellum*, and the *cerebrum*.

The Medulla Oblongata.—As the spinal cord passes through the foramen magnum it swells out at the beginning of the decussation of the pyramidal tracts. From this point to the lower border of the pons is the medulla (Fig. 227). The central canal of the spinal cord is expanded in the medulla to form the fourth ventricle (see page 263). The nuclei or centers of several cranial nerves lie in the gray matter of the medulla immediately underneath the floor of the fourth ventricle. Essentially the medulla is distinguished by:

1. The relay nuclei of the sensory tracts to the brain: the nucleus gracilis and nucleus cuneatus (Fig. 228).
2. The nuclei of certain cranial nerves.
3. The decussation of the sensory and motor tracts (Fig. 229).

Fig. 227.—Median section of the brain (Spear).

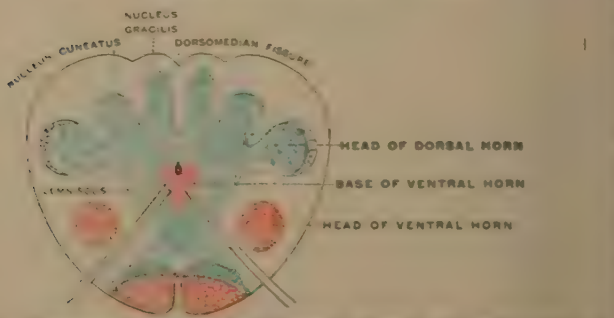

Fig. 228.—Transverse section of the oblongata showing the relay nuclei of afferent pathways and the crossing of the fillets (Testut).

4. Centers of control for certain bodily functions, *e. g.*, respiratory center, vasomotor center, cardiac center.

Function of the Medulla: The medulla serves as an organ of conduction for the main sensory and motor tracts between cord

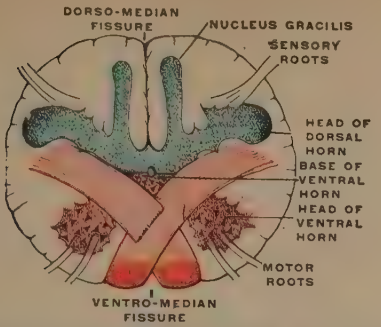

Fig. 229.—Transverse section of the oblongata at the decussation of the pyramids (Testut, after Duval).

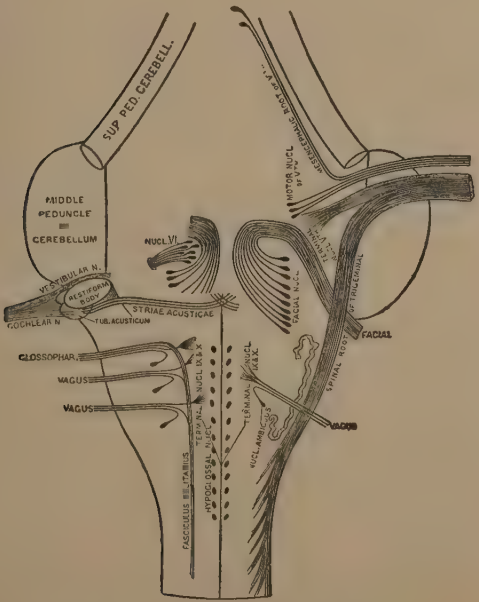

Fig. 230.—Diagram showing the brain connections of the vagus, glossopharyngeal, auditory, facial, abducens, and trigeminal nerves (after Obersteiner).

and brain. The location of the nuclei of cranial nerves in the medulla makes it the site of many reflex acts related to these nerves (Fig. 230). Thus, the reflexes involved in vomiting, sneezing, coughing, mastication, deglutition, and closure of the eyelids come through the cranial nuclei of this region. In addition to this simple reflex type of control there are groups of nerve-cells having an automatic control over certain bodily functions. These groups are called *centers*. The cardiac center regulates the rate of the heart-beat, the respiratory center controls the activity of the respiratory organs, and the vasomotor center determines the caliber of the blood-vessels. These centers are automatic and respond to changes in the blood coming to the centers, and to afferent impulses from the organs concerned. The respiratory center is peculiarly susceptible to the carbon dioxid proportion in the blood.

The Pons Varolii.—It is composed mostly of fibers passing between the other three parts of the brain. Its chief portion is formed by the fibers connecting the two halves of the cerebellum, known as the middle peduncle.

The Cerebellum.—This lies below the cerebrum in the posterior region of the skull cavity. It consists, like the cerebrum, of two halves, known as the *hemispheres*, and a central portion, the *vermis* (Figs. 224, 227). Internally the cerebellum shows itself to be made up mainly of fiber tracts from the cord and brain and two main tracts that unite the two halves through the middle peduncles of the pons. The superior peduncles carrying tracts come down from the cerebrum; the two inferior peduncles, also composed of tracts, pass to the medulla. The gray matter of the cerebellum exhibits characteristic cells, however, the cells of Purkinje (Fig. 231).

Function of the Cerebellum: The cerebellum is concerned ordinarily in the co-ordination of muscular movements and especially the movements of locomotion. The power to co-ordinate the movements of the body with force and harmonious balance resides in the cerebellum. The power of equilibrium is in part involved in the co-ordinate action of the muscles, but other structures share with the cerebellum this function, *e. g.*, the semicircular canals in the internal ear, the retinæ of the eyes, the receptors in the skin, and the nerve endings in muscle and ligaments around joints.

The ability that one has to tell where parts of the body are in space with the eyes closed is due to a sensation conveyed from the receptors in the muscles under contraction. This sense is the *muscle sense,* and it plays an important part in the phenomenon of equilibrium. Muscle sense is co-ordinated in the cerebellum, but any disturbance of the tracts in the cord that conveys the impulses to the cerebellum results in a loss of this function. Hence, in locomotor ataxia, in which there occurs degeneration of the posterior columns of the cord, there is an impairment of

Fig. 231.—A Purkinje cell of the cerebellar cortex. Golgi method: *a,* Axon; *b,* collateral; *c, d,* ramifications of dendrons. (Cajal.)

the powers of muscle sense. An individual suffering from this disease is very dependent upon the accessory factors in maintaining equilibrium, particularly the eye. One of the tests used to determine the power of this function consists in having the individual stand with the eyes closed and the feet close together. The normal person can stand without difficulty; the victim of locomotor ataxia will sway and at times fall if not protected.

The Cerebrum.—The cerebrum is the most conspicuous portion of the brain* and in man reflects the extent of his development toward intelligence. The outermost part of the cerebrum is called the *cortex*. It consists of gray matter folded many times, making numerous convolutions and fissures (Figs. 226 and 227). The cerebrum presents two *hemispheres*, separated from each other by a deep sulcus, the *great longitudinal fissure*. At the bottom of this cleft is white matter composed of fibers crossing between the two hemispheres. This crossing is called the *corpus callosum*.

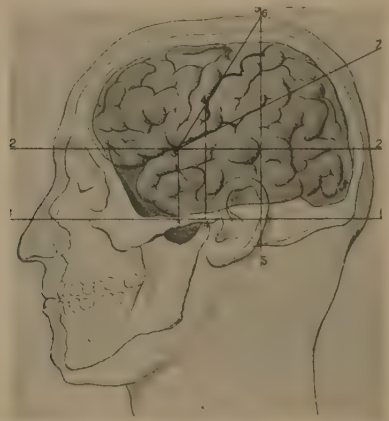

Fig. 232.—Relation of the brain to the skull: 1, 1, Reid's base-line; 2, 2, superior horizontal line; 3, 3, anterior vertical line passing from middle of zygomatic arch perpendicular to base-line; 4, 4, middle vertical line passing through pre-auricular fossa; 5, 5, posterior perpendicular line passing through the posterior border of the mastoid process; 3, 6, line of fissure of Rolando; 3, 7, line of fissure of Sylvius. (Campbell, modified after Krönlein.)

Some of the fissures that mark the cortex are well defined and of such conspicuous character that they serve as landmarks to locate the different areas. The two chief fissures are the *fissure of Rolando* and the *fissure of Sylvius*. The position of these fissures as projected upon the skull is given in Fig. 232. A continuation of the Sylvian line to the great longitudinal fissure

* An important part of the brain is that portion of the stem underneath the cerebrum. This is the *thalamus* with other accessory centers or ganglia which comprise relay nuclei as well as passageway for tracts to and from the cerebrum.

locates the parieto-occipital fissure, which, with the Sylvian and Rolando, divide the cortex into five lobes (Fig. 233). It should be remembered that the cerebrum is bilateral; there are, then, a total of ten lobes. These are: the *frontal*, *parietal*, *occipital*, *temporal*, and *island of Reil*. The first four are clearly shown in Fig. 233, but the island of Reil is not visible in this view of the cortex because it is hidden at the base of the brain in the fissure of Sylvius.

The Ventricles.—The central canal of the cord (Fig. 215) is a small lumen that exists throughout the length of the cord. Since the brain is only an elaboration of the head end of the masses composing the cord it would be expected that this canal would be present in the brain. Such is the case, with some

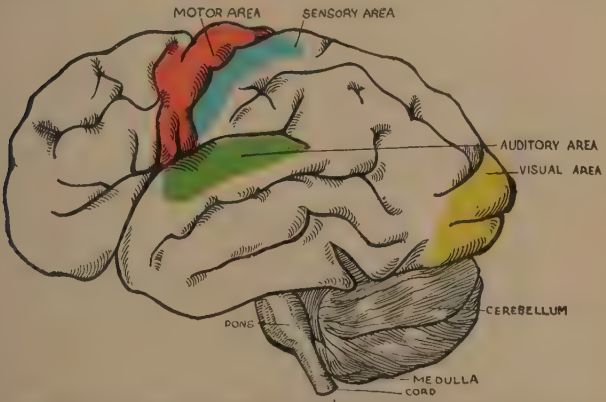

Fig. 233.—Cerebral localization, external surface (Burton-Opitz).

modifications. While the central canal is quite uniform in size, its continuation in the brain is marked by expansions and constrictions that accord with the development of this organ. The expansions in the brain are called *ventricles*.

There are four ventricles, although a fifth is at times erroneously named. The continuation of the central canal through the medulla shows a swing posteriorly where it spreads out in a quadrilateral space, the *fourth ventricle*. This lies in front of the cerebellum. From the fourth ventricle the canal is continued by a narrow passageway, the *aqueduct of Sylvius*. This structure

opens out into the *third ventricle*. The third ventricle (Fig. 227) is a small vertical slit between the two halves of the brain. As a remnant of the cerebral canal it connects below with the aqueduct and laterally with the two lateral ventricles. The first and second ventricles are the *lateral ventricles* contained within the cerebral hemispheres. These connect with the third by small apertures, the *foramina of Monro*.

The cerebrospinal fluid of the central canal and ventricles communicates with the cerebrospinal fluid in the subarachnoid space on the outer side of brain and cord. This connection is made by three small openings: the *foramen of Magendie* and the *foramina of Luschka*. These open from the fourth ventricle and provide a means for adjustment of pressure due to the secretion of this fluid in the canal and ventricles.

Tracts of the Brain.—The gray matter of the cortex is composed of cells that are pyramidal in shape (Fig. 234). From these cells fibers pass in three main systems to other areas of the same hemisphere, to the other hemisphere to the cerebellum, and to the columns of the spinal cord. These three divisions constitute three main systems within the brain:

1. The association tracts.
2. The commissural tracts.
3. The projection tracts.

The Association Tracts.—Careful dissection shows that each convolution is joined to the two adjacent convolutions by fibers that pass around the separating fissures (Fig. 235). It also has been demonstrated that bundles pass from each convolution to the convolutions beyond, so that each convolution has a possible connection with every other one. The function of these association tracts is held to be the association of concrete memories, acts, and purposes. These fibers are regarded as the physical basis of thought.

The Commissural Tracts.—The fibers in this system run in the *corpus callosum* between the two hemispheres (Fig. 227). Their function is to harmonize the action of the two halves of the brain. Hence simultaneous movements of the opposite extremities can be made if these tracts are unimpaired. For right-handed persons a movement that is made with the left hand becomes easy when associated with the right hand at the same time. Thus, writing the name with the left hand alone becomes easier when the right hand is associated in the same act and both hands perform simultaneously.

The Projection Tracts.—This system of fibers joins the cortex and parts lying below, such as the cord, the thalamus, the cere-

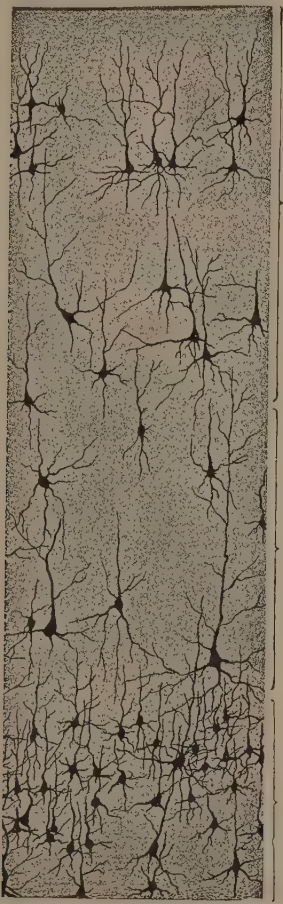

Fig. 234.—Portions of vertical section of human cerebral cortex, treated by the Golgi method. The figure shows the arrangement of the different cells of the cerebral cortex (Sobotta and Huber, Atlas of Human Histology).

bellum, and other ganglia (basal ganglia) in the brain stem. It

is through these tracts that the external world is *projected* upon the brain and impulses from the cortex are conducted to the outlying parts. The function of all the projection tracts has not been made out, but their anatomy is quite clear (Fig. 225). The following are well defined:

1. A tract from the frontal lobe to the pons.
2. A tract from the central convolutions to the pons and cord.
3. A tract from the posterior columns of the cord to the parietal lobes of the cortex.
4. A tract from the thalamus to the occipital lobes of the cortex.

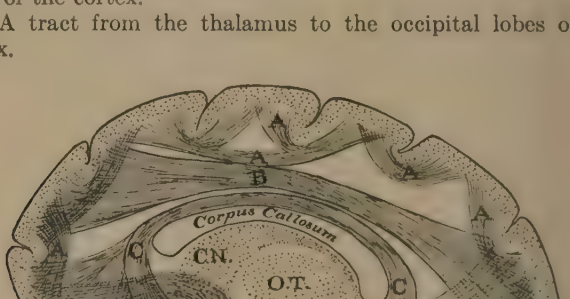

Fig. 235.—Lateral view of a human hemisphere, showing the bundles of association fibers: *A*, *A*, Between adjacent convolutions; *B*, between frontal and occipital areas; *C*, between frontal and temporal areas; *D*, between frontal and temporal areas; *E*, between occipital and temporal areas; *C*, *N*, caudate nucleus; *O*, *T*, thalamus. (After Starr.)

5. A tract from the thalamus to the temporal lobes of the cortex.
6. The tracts of the superior, middle, and inferior peduncles to the cerebellum.

The Brain Areas.—The teaching of Goll regarding the brain led to claims of relationship between the bony configuration of the skull and mental faculties. Phrenology claimed the power of detecting the special qualities of the brain by the shape, contour, and protuberances of the skull. Such claims today are not highly regarded by scientific persons. The varying size of the sinuses of the skull, the abnormalities of bone growth

ttendant upon disturbance of the internal secretions, the nalformations consequent to rickets throw out at once any laims for brain function that is based upon cranial architecture.

The rejection of the above view led to the theory that the ntire brain functioned in every mental state. This view, however, was soon discarded. Broca's discovery of a center for notor speech was soon followed by other observations that lescribed special brain areas for special functions, but of course vithout any correspondence with formations of the skull. This iew of localized brain areas and corresponding functions has prevailed until recently.

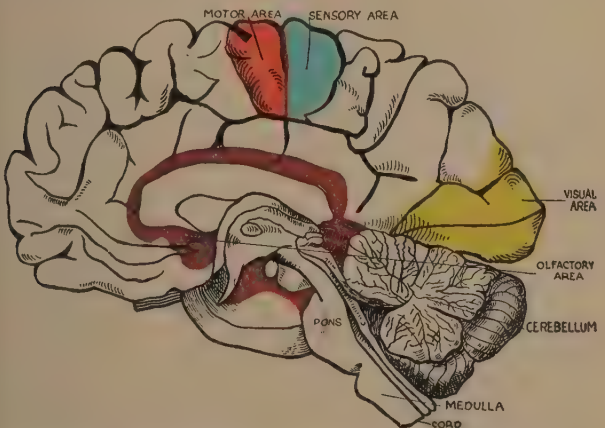

Fig. 236.—Cerebral localization, mesial surface (Burton-Opitz).

Serious doubts have been raised by Franz,* Lashley,† and others about present views of cerebral localization but since even Lashley's ideas of the brain as "dynamic function of cerebral tissue" remains quite vague and since both experimental and clinical data exhibit a criticism of cerebral localization without as yet presenting an explanation of certain brain functions it seems desirable to retain for the present the traditional view. The student should remember, however, that the follow-

* Franz, G. I.: "Cerebral Mental Relations," The Psychological Review. March, 1921, Vol. 28, No. 2, p. 81.

† Lashley, K. S.: "Studies of Cerebral Function in Learning," Journal of Comparative Neurology, August, 1926, Vol. 41, No. 1.

ing description of brain areas is not fully accepted, that later it may be entirely rejected. The areas usually described are:

1. The motor area.
2. The sensory area.
3. The visual area.
4. The auditory area.
5. The area of the sensations of smell and taste.
6. The speech and writing areas.

The Motor Area.—This area is situated in the anterior central convolution in front of the fissure of Rolando in each hemisphere (Figs. 233, 236). The area of the left side controls movements of the right side of the body and vice versa, but since the right hand is more often used and better trained in right-handed persons, the left area is usually larger and better developed. Beginning at the great longitudinal fissure and passing downward to the fissure of Sylvius the motor area may be divided into three parts. The upper portion controls the movements of the lower extremity and trunk, the middle third governs the movements of the upper extremity, and the lower part innervates the muscles of the face. The motor centers govern motor acts rather than special muscles.

The Sensory Area.—The sensory area is situated behind the motor area. It occupies the posterior central convolution and part of the parietal area (Figs. 233, 236). It is divided into areas similar to those located in the motor area. Thus, the legs and trunk are near the great longitudinal fissure, the arms in the middle portion, and the face at the tip near the fissure of Sylvius. To this area come the fibers from below in the great sensory tract conveying impulses from the sense receptors.

The Visual Area.- The sense of sight has its center in the visual area of the brain, located in the occipital lobes (Figs. 233, 236). Each occipital lobe receives impulses from one-half of the retina of both eyes. The eye serves as a receptor and the optic nerve is the first neuron of the tract that runs to the thalamus (Fig. 394), from which point it swings out and back in the optic radiation to the occipital lobes. Destruction of the one occipital lobe would cause a half-blindedness in each eye, known as hemianopsia or hemianopia. The sight-memory area is on the left side, and destruction of the left lobe results in loss of the power to recall things seen, and even reading power may be lost by such a lesion.

The Auditory Area.—The sound waves that come into the ear and stimulate the nerve endings of the auditory nerve are ultimately conveyed to the temporal lobes of the brain which is the auditory area. The upper portion of the temporal lobe (Fig. 233) controls the interpretation of the sound waves; the middle and lower lobes are involved in the memory concepts of sounds.

The Area of the Sensations of Smell and Taste.—The olfactory nerve from the nose and the glossopharyngeal nerve from the tongue convey to the temporal lobes on their under and inner surface the impulses that are interpreted in the smell and taste areas (Fig. 236). The distribution of the receptors in the nose and mouth are so great that injury of the cerebral areas do not often involve loss of the power of taste and smell.

The Speech and Writing Areas.—The faculty of speech is very complex. It represents one of the latest acquisitions of the animal world. In addition to rather complex mechanisms in the brain, the effector mechanism of the larynx, lips, and tongue presents a marvelous arrangement for the production of a great variety of sounds.

In the brain the complete mechanism of speech production based upon the theory of brain areas can be analyzed into four components that are all closely related, and are limited to the left hemisphere in right-handed persons and to the right hemisphere in left-handed persons.

1. There is the motor speech area located in the posterior part of the third frontal convolution (Fig. 237), often called Broca's convolution.* Here are co-ordinated the movements concerned in speech production. Injury of this area results in a loss of the the power of talking. Left-handed children who are trained to write with the right hand frequently develop defects of speech, especially stammering. The centers for speech and writing are closely associated. Left-handed children can frequently be cured of stammering by permitting them to use the left hand.

2. Speech involves more than the muscular movements of the speech mechanism. A child born deaf learns with the greatest difficulty to talk, if he ever learns at all. Hence, it is found that certain parts of the temporal cortex are concerned in speech, and are, therefore, known as the *auditory-speech areas.* If an injury

* Apparently this convolution is a late acquisition in animal life, and to be found only in man. Sherrington (The Integrative Action of the Nervous System, p. 290) reports his inability to find it in anthropoid apes.

occurs in the auditory-speech area in the middle temporal convolution of the left side (Fig. 237) the understanding of language and the power of recollecting the names of objects are lost. Speech is also closely associated with the power of sight.

3. The visual-speech area is in the occipital and lower parietal lobes of the left side (Fig. 237). Its function is to store up memories of printed words. Destruction of this area results in a loss of the power to understand the written language, and hence an inability to read.

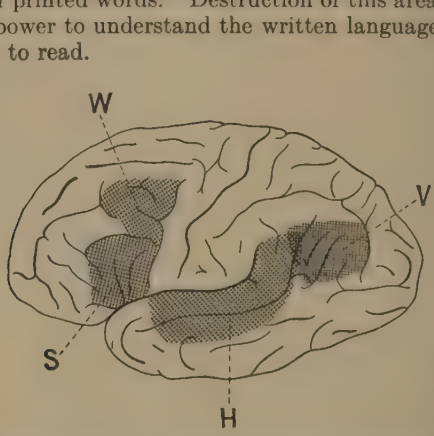

Fig. 237.—Lateral view of a human hemisphere; cortical area *V*, damage to which produces "mind-blindness" (word-blindness); cortical area *H*, damage to which produces "mind-deafness" (word-deafness); cortical area *S*, damage to which causes the loss of audible speech; cortical area *W*, damage to which abolishes the power of writing. (Donaldson.)

4. The power of writing is closely related to the power of speech. Loss of speech usually results in loss or impairment of the power of writing. Its exact location has not been determined, but considerable evidence locates it quite close to Broca's convolution (Fig. 237).

The loss of speech is called aphasia,[2] but such condition may be made up of the loss of the power to remember the sound of the word, the appearance of the word as printed, the muscular movements needed to write the word, or the co-ordinations necessary to pronounce it. These memory pictures are essential for the proper association of the image of the word used in speech.

The above description of speech areas and aphasia is the traditional explanation. Clinical cases cited by Franz and

xperimental work by Lashley do not fit into this explanation. 'he above should be considered as tentative for the present.

Brain Activity in Children.—During the early months the nfant makes a great many small spontaneous movements of the mbs, and especially the digits. At three months movements ccur with regard to sense stimulation, and the small spontaneous novements are replaced gradually by responses to environmental timuli.

Muscular control, associated as it is with cerebellar activity, s lacking in the early years,[3] although after the age of five there s improvement. Hancock* studied muscular control in young hildren and concludes as follows:

1. Fine and completed movements are made with difficulty.
2. Efforts to keep quiet produced strong symptoms of nervous rritation.
3. Movement is inhibited only in part, and awkward swayings nd twitchings result.
4. Children in normal healthy growth show a lack of co-ordination and control paralleled only by ataxic. choreic, and paralytic atients.

Hall† states that girls are steadier than boys before puberty, he left hand less than the right, and the ring finger less than he others. Holt reports that the normal child shows co-ordinate ction of the eyes at three months and recognizes objects at ix months of age. Its speech centers develop later, so that he an say single words, as "mama," at one year and short sentences t the end of the second year.

The Cranial Nerves.—By considering the brain as an amplification of the kind of tissue that produced the spinal cord, and y viewing its complex parts as only a differentiation and specialization of the structures seen in the cord, a comparison of the ranial nerves with the spinal ones will be made clear. The spinal erves were made up of two roots, motor and secretory or efferent, nd sensory or afferent. In similar fashion the twelve pairs of ranial nerves enter and leave the brain stem. The cranial nerves f efferent function leave the brain from nuclei similar in character to the cells in the anterior horn of the gray matter of the ord. The cranial nerves of afferent function come into the

* Hancock: A Study of Motor Ability, Ped. Sem., vol. iii, 1894.
† Hall, G. S.: Adolescence, vol. i., D. Appleton & Co., New York, 1904, . 145.

brain, ending in nuclei that are similar to the posterior root ganglion. Some of the cranial nerves are, therefore, efferent, others are afferent, and others resemble even more the spinal nerves in that they are composed of both afferent and efferent neurons. They have two sets of names: one based on the order of their exit from the brain (Fig. 224), the other on their function.

The table* shown on page 273 indicates their names, origin, function, and distribution.

Nerve-centers.—The nuclei of the cranial nerves offer a good illustration of the principle under which the nervous system works. Impulses over an afferent nerve are conveyed to the brain and after connections are made the proper response is initiated. For example, light waves may stimulate the optic nerve endings, the retinæ, and in the passage of the impulse to the occipital lobes of the brain, certain connections are made on the inward route with tracts connecting with the nucleus of the third cranial nerve. If the impulse is of a certain quality that means too much light, the center of the third nerve sends impulses over its tract to the sphincter of the iris and the pupil is constricted. This type of reflex circuit illustrates the way centers act, controlling and modifying the effector mechanism in accordance with the experiences of the nerve-cells constituting the center.

The brain as the highest center and the most powerful mass of gray matter in the system exerts a controlling and directing force over the other centers of the brain and cord. While the spinal cord and basal ganglia have certain powers, the brain is able to inhibit their functions to a certain extent, to take them over at times, and even to mold them to its own purpose. While this power of the cerebrum is not all inclusive, control of cerebral activities may result in a very large inhibition or acceleration of the centers. Usually volitional act cannot change the heart-rate through inhibition of the accelerator nerves or stimulation of the vagus,† and yet cerebral activity of a certain kind can start the flow of gastric juice;‡ it can regulate the speed and number of the

* Medical students have used for many years the following mnemonic in which the first letter in each word represents in order the cranial nerves: "On Old Olympus' Tiny Tops A Finn and German Picked Some Hops."

† Emotional states may accelerate the rate. Instances are on record of individuals possessed of the power to accelerate the heart voluntarily. Taylor, N. B.: Voluntary Acceleration of the Heart, Amer. Jour. Physiol., August, 1922.

‡ Psychic stimulation, *e. g.*, thought of appetizing food.

Nerve. Number.	Nerve. Name.	Origin.	Function.	Distribution.
I	Olfactory:	Olfactory bulb at base of brain.	Sense of smell.	Mucous membrane of the upper third of nasal passage.
II	Optic:	Occipital lobes of the brain.	Sense of sight.	Retina of the eye.
III	Oculomotor:	Center of brain emerging in front.	Motor to eye muscles.	To the muscles of the eye except the external rectus and superior oblique.
IV	Trochlear (pathetic):	Center of brain emerging in front of pons.	Motor to eye muscle.	To the superior oblique.
V	Trigeminal:	From a long tract in medulla and brain stem above emerging at side of pons.	Sensory and motor. The sensory root has a large ganglion, the gasserian ganglion, from which come off three divisions: ophthalmic, maxillary, and mandibular.	Sensory to forehead, scalp, upper eyelid, side of nose, lacrimal gland, teeth of maxilla and mandible, motor to muscles of mastication and part of tongue.
VI	Abducent:	From the floor of the fourth ventricle.	Motor to eye muscle.	To the external rectus.
VII	Facial:	From the floor of the fourth ventricle.	Motor to face muscles.	To all the muscles of expression, to some of the muscles of mastication, and to some neck muscles.
VIII	Auditory:	From the temporal lobes of the opposite side, emerging between the pons and medulla.	Sense of hearing and equilibrium.	To the organ of Corti in the inner ear, and to the semicircular canals.
IX	Glossopharyngeal:	From medulla, emerging between pons and medulla.	Sensory to mucous membrane of mouth, and motor to pharyngeal muscles.	To the posterior third of tongue, giving sense of taste. Sensory to mucous membrane of tonsils, fauces, and pharynx. Motor to muscles of the pharynx.
X	Pneumogastric, better known as vagus.	From the floor of the fourth ventricle.	Sensory and motor to vocal organs and lungs, and motor to pharynx, esophagus, stomach, and heart. Inhibits the action of the heart.	To the larynx, vocal cords, and laryngeal muscles, lungs, esophagus, stomach, and heart.
XI	Spinal accessory:	From the medulla and spinal cord.	Motor to palate, neck muscles, and the trapezius.	To the palate muscles, trapezius, and muscles of the neck.
XII	Hypoglossal:	From the medulla.	Motor to tongue.	To the muscles of the tongue.

contractions of the muscles of mastication; it can close the eyelids and dilate the nostrils of the nose. Perhaps it is most fortunate for man that cerebral activity is not more widely extended over the metabolic functions of the body than it is. Planning more than might be wise, *homo sapiens*, would surely attempt too much.

However much cerebral control gains ascendency over the lower centers of the nervous system, the scope and character of the autonomic system will probably remain as it is for the next million years.[4]

PRACTICAL EXERCISES

1. Abnormalities in development of the brain and its parts may occur. The following are most often seen:
   (*a*) The brain may be abnormally small—*microcephalus*.
   (*b*) The head may be abnormally large due to retention of cerebrospinal fluid in the brain ventricles or in the subarachnoid space. This is called *hydrocephalus*.
   (*c*) Defective ossification of the skull may result in a condition similar to spina bifida. The protrusion of brain substance through the openings gives a *meningocele* if only meninges are involved, an *encephalocele* if part of the brain is in the protrusion.

What are the normal ranges for head size? When is a skull microcephalic? Megacephalic?

2. Tumors of the brain may exist either as growths or from hemorrhage. By exerting pressure on the cerebral cortex they interfere with the action of nerve-cells. Thus, tumor in the motor area on the left side causes paralysis on the right side of the body. What parts would be paralyzed if the tumor were near the longitudinal fissure on the left side of the brain, in the motor area?

3. Stand with the feet close together and parallel, shut the eyes. Can you stand perfectly still, without swaying? Equilibrium is maintained by sensations from the muscles, ligaments, and joints. A person with defect in the sensory tracts (as in locomotor ataxia) cannot stand without the aid of the eyes.

4. Close the eyes and place the index-finger of the left hand on the tip of the nose. Explain how one is able to perform this co-ordination.

5. Cross the second finger over the index-finger and roll a shot between ulnar side of the second and radial side of the index-finger. Explain the result.

6. With a free-arm motion write your name with the left hand. Write your name with left and right hands simultaneously. Compare both left-hand specimens. Which is better? Why?

QUESTIONS

1. Why should the head ganglion rather than the tail ganglion have developed control over the cord?
2. How are the brain sinuses formed? Near what important structure is the lateral sinus?
3. What is the respiratory center? What controls it?
4. What is equilibrium? How is it maintained?
5. Describe the three main systems of tracts within the brain.
6. What is aphasia? Explain the mechanism of speech production.
7. How does muscular control in a child differ from that in an adult?
8. What is the motor area of the cortex?
9. Trace an impulse from skin to brain and out to muscle.
10. What are cranial nerves? How do they resemble the spinal nerves?

11. Describe the brain ventricles. How do they connect with the space outside of brain and cord?
12. What is hydrocephalus?

REFERENCES FOR FURTHER STUDY

1. Donaldson, H. H.: The Growth of the Brain, Charles Scribners Sons, New York, 1912, Chaps. IV, XII.
2. Starr, M. A.: Nervous Diseases, Organic and Functional, Lea & Febiger, Philadelphia, 1909, pp. 133–138.
3. Guthrie, L. G.: Functional Nervous Disorders in Childhood, Oxford Medical Publications, London, 1909.
4. Williams, J. F.: Personal Hygiene Applied, W. B. Saunders Company, Philadelphia, 1928, pp. 326–333.

CHAPTER X

THE NERVOUS SYSTEM—THE AUTONOMIC

I. The Nature of the Autonomic Nervous System.
II. General Plan:
    1. The Cranial Autonomic.
    2. The Thoracicolumbar Autonomic.
    3. The Sacral Autonomic.
III. Functions of the Autonomic System.
    1. Referred Pain.
IV. Plexuses and Outlying Ganglia.
V. Summary.

The Nature of the Autonomic Nervous System.—When one is hungry the mere sight of food causes a flow not only of saliva but also of gastric juice. This goes on without conscious direction and is illustrative of one of the activities of the autonomic nervous system. It has long been known that certain nerves and ganglia presided over the functions of the thoracic and abdominal viscera. These nerve structures were known as the sympathetic nervous system. Later, other nerve structures performing functions of like character were discovered in the brain and the name "parasympathetic" was added. Langley proposed the term "autonomic" to embrace all these nerves and ganglia, situated outside the cord and engaged in regulating the activities of the glands and smooth muscle of the viscera.

Additional study has determined a close relation between emotional states and activity of the autonomic system.[1] This relation may show diverse effects—*e. g.*, some emotions are favorable and others disturbing to normal action of the abdominal viscera.

General Plan.—While separate and distinct in its anatomy and physiology, the autonomic system is an integral part of the nervous mechanism of the body and closely related with the cerebrospinal system. It comprises a chain of ganglia running from the brain to the coccyx, with connecting fibers to the cord and neurons that reach out to various outlying parts. The ganglia are the prominent portions, and particularly the ones situated on

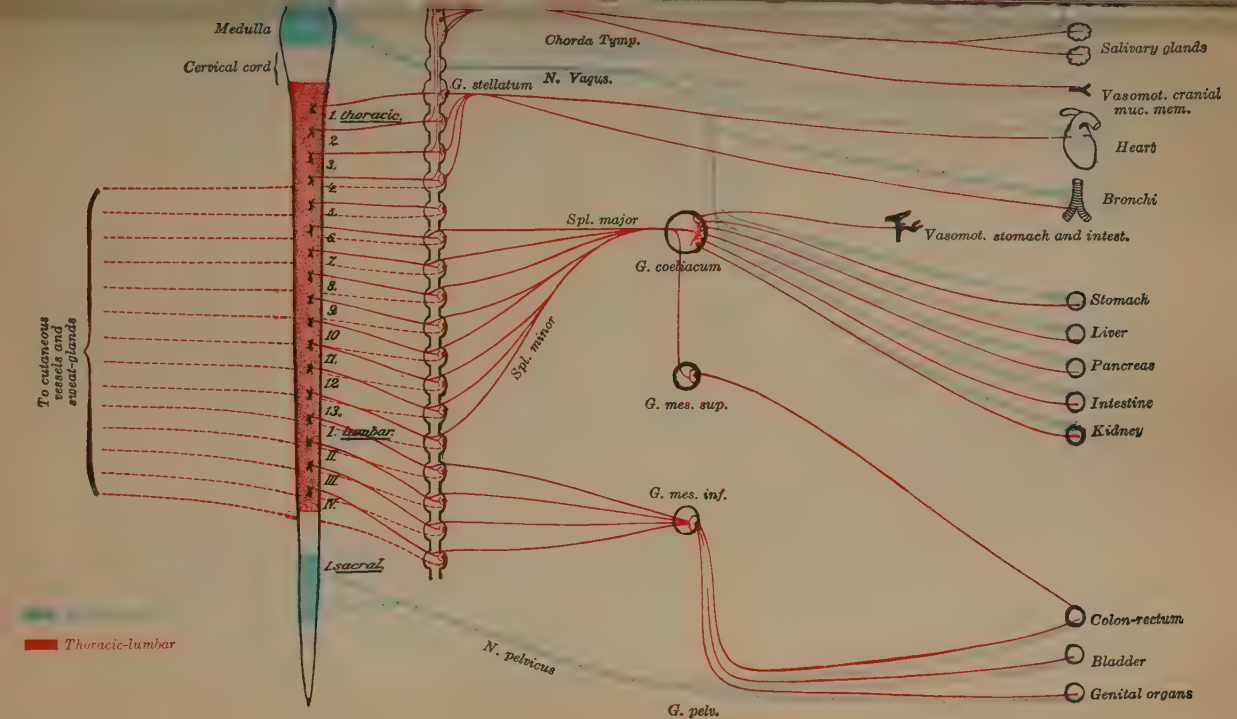

Fig. 238.—Diagram of the autonomic nervous system. The blue lines represent the neurones of the cranio-sacral division; the

each side of the vertebral column. Grouped according to their location they may be divided into three divisions—cranial, thoracicolumbar, and sacral.

The *cranial autonomic* is composed of ganglia in the brain. They connect with the eye, salivary glands, heart, bronchi, stomach, intestines, liver, pancreas, spleen, and kidney (Fig. 238).

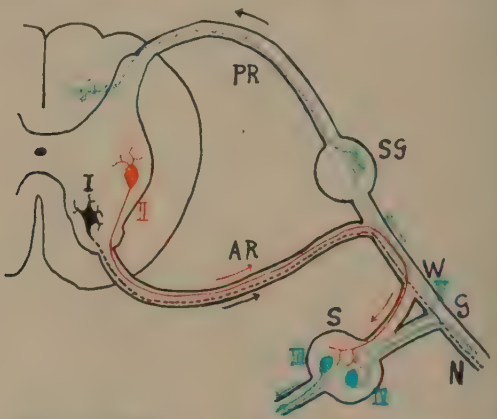

Fig. 239.—Diagrammatic representation of the connection between the cerebrospinal and autonomic systems: *AR* and *PR*, Anterior and posterior roots of the spinal cord; *SG*, spinal ganglion; *N*, spinal nerve; *W*, white ramus; *G*, gray ramus; *S*, autonomic ganglion; *I*, ordinary motor neuron, the axon of which pursues a straight course to peripheral effector; *II*, motor neuron, the axon of which enters autonomic ganglion through the white ramus; *III*, secondary neuron carrying the impulses from *II* to other parts of autonomic system; *IV*, secondary neuron, carrying impulses from autonomic system through the gray ramus to the peripheral effector in the domain of the cerebrospinal system; *V*, neuron carrying afferent impulses from autonomic system into cerebrospinal system by way of spinal ganglion and posterior root. Only one autonomic ganglion (*S*) is shown here. It should be remembered that a chain of ganglia extend on each side for the length of the vertebral column (Fig. 238), connecting with others in the brain and pelvis and with outlying plexuses. (Burton-Opitz.)

The *thoracicolumbar autonomic* is the part formerly called the sympathetic. The neurons from the ganglia of this portion are widely distributed. They go to the eye, heart, skin arterioles, abdominal viscera and vessels, muscles of hairs, and genito-urinary tracts.

The *sacral autonomic* is distributed to the colon, bladder, and external genitals.

The ganglia of these three divisions make connections centrally with the spinal cord or brain and peripherally with the parts to be supplied. The fibers from the cord to the ganglia are called preganglionic; and those from the ganglia to viscera are known as postganglionic. The manner of connection with the cord is shown in Fig. 239. It will be noted that from the autonomic ganglia neurons may convey impulses to other parts of the autonomic system, and to regions supplied by the efferent nerves of the cord. Moreover, afferent impulses from autonomic areas also come into the cord.

Functions of the Autonomic System.—The cranial autonomic is concerned in the psychic secretion of gastric juice, contraction of the pupil, slowing of the heart, and probably other functions. The sacral division causes contraction of the rectum, colon, and bladder. Its supply to the external genitals has also been determined. The thoracicolumbar division has a wide distribution, particularly to the digestive tract. It is concerned with the metabolic activities of these parts.

One important phase of the functional activity of the divisions of the autonomic is the antagonistic action shown by the midpart to each end part. Thus, the cranial division contracts the pupil, the thoracic dilates it; the cranial slows the heart, the thoracic accelerates it; the sacral contracts the lower colon and rectum, the thoracic relaxes them; the sacral relaxes the sphincter of the bladder, the thoracic contracts it. This "reciprocal innervation"[2] is of pronounced service to the body, and yet through emotional excitement profound disturbance may result due to antagonistic effects produced over the cranial or sacral divisions.

Referred Pain.—Pain impulses from nerves of the cerebrospinal nervous system are interpreted by the brain as coming from the area supplied by the nerve. Thus, impulses from nerves that have been irritated by burns of the index finger of the left hand, for example, are interpreted by the brain as coming from the index finger of the left hand. Viscera are supplied by autonomic fibers but pain impulses from viscera not due to contraction are not felt in these parts but in the body surface overlying the part. The explanation of this fact is that, in general experience, the sensations coming in at a certain segment of the cord are due to irritations of the surface of the body innervated by cerebrospinal nerves from these segments. Thus, when pain impulses reach the cord over the autonomic (Fig. 240), they are referred to that

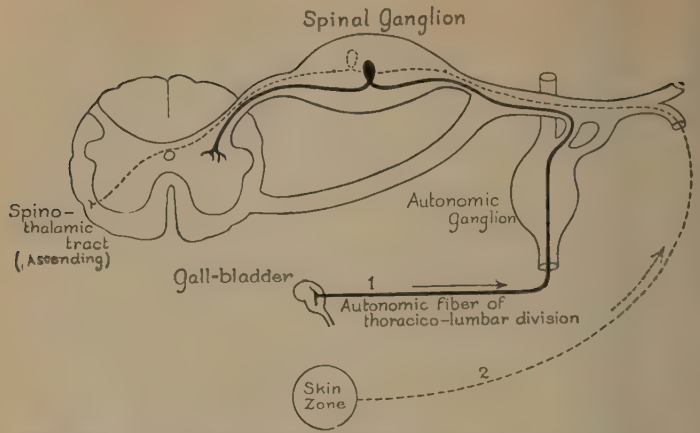

Fig. 240.—Pain impulse from gall-bladder travels over autonomic fiber (1) to cord. Brain interprets impulses at this segment as coming from afferent nerve cerebrospinal system (2), and hence refers pain to skin zone supplied by 2. Synaptic connection between 1 and 2 may exist, but its location is not known.

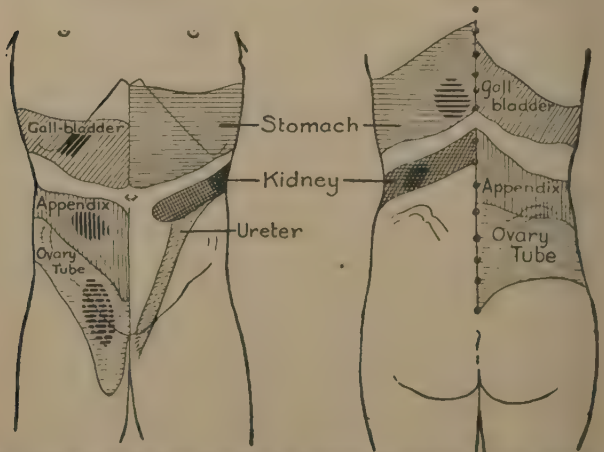

Fig. 241.—Location and outline of areas of increased sensitiveness and, in shaded areas, pain points for some of the abdominal viscera (after Elsberg and Neuhof).

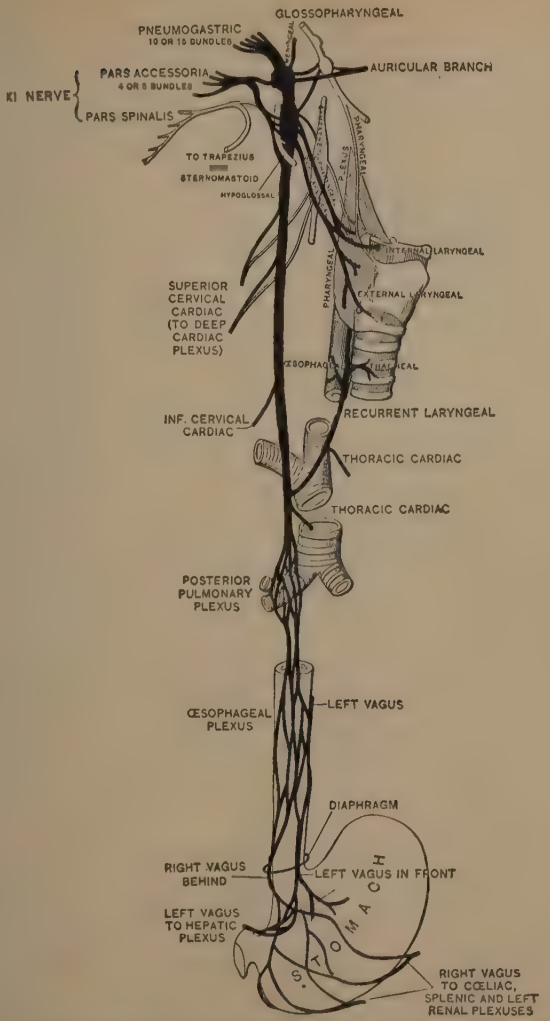

Fig. 242.—Distribution of right pneumogastric nerve showing branches given to cardiac, solar, and other plexuses (W. Keiller).

particular area of the surface of the body supplied afferently by the segment concerned. Thus, hyperesthesia of the skin or distinct pain may be a referred sensation and indicate disturbance of deeper parts. Figure 241 indicates areas in which disturbance of certain viscera carried to the cord by the autonomic is interpreted by the brain as coming from the surface and, hence, is referred pain.

Plexuses and Outlying Ganglia.—Situated on various organs, blood-vessels, and in the wall of the digestive tract are masses of nerve tissue that serve as relay centers for the impulses coming from the main divisions of the autonomic. The smaller centers are called ganglia and are composed chiefly of cell bodies; the larger masses are called plexuses and are made up largely of fibers. These stations serve to increase the number of pathways available because the efferent fibers from these centers frequently present a fan-like arrangement with many more connections than would be possible for the fibers entering the plexus.

Prominent plexuses are the *cardiac*, *solar*, *aortic*, and *hypogastric* (Fig. 242). Each one of the above has numerous subdivisions or branches, so that the entire visceral organization of the body is well supplied with autonomic fibers.

Summary.—The autonomic nervous system is to be viewed not as separate and distinct from the cerebrospinal, but closely related to the latter. Its neurons frequently pass with the central neurons in the same nerve, although there are also separate autonomic nerves. The ganglia and plexuses are nerve centers or stations for relaying impulses. Functionally[3] this system is concerned with the activities of most glands, cardiac muscle, nearly all smooth muscle, some pigment cells, and is intimately related with emotional states and the activities of endocrine organs.

PRACTICAL EXERCISES

1. Have a subject face the light and close the eyes. On opening the eyes note the constriction of the pupils. Face the dark and note the dilation of the pupils.
2. When hungry, think of savory food and note the increase in salivary secretion.
3. Note the increased heart rate when one is placed in situations having emotional factors, *e. g.*, being called upon to make a speech, an exciting moment in a drama, the reading of a letter bearing unusually good news, the meeting of a dear friend after long separation, etc.

QUESTIONS

1. Locate the ganglia of the autonomic nervous system
2. What is a ganglion? A plexus?
3. Describe the functions of the three divisions of the autonomic.

REFERENCES FOR FURTHER STUDY

1. Cannon, W. B.: Bodily Changes in Hunger, Fear, and Rage, D. Appleton Co., New York, 1915.
2. Sherrington, C. S.: The Integrative Action of the Nervous System, Yale University Press, 1906.
3. Langley, J. N.: The Autonomic Nervous System, Part 1, W. Heffer & Sons, Ltd., Cambridge, England, 1921. Brown, W. L.: The Sympathetic Nervous System in Disease, Oxford Medical Publications, 1919.

CHAPTER XI

THE CIRCULATORY SYSTEM

I. Development of the Circulatory System.
II. General Arrangement of the Circulatory System.
III. The Blood and Lymph.
IV. The Lymphatic System:
1. Lymph.
2. Lymphatic Vessels.
3. The Main Lymphatic Channels.
4. Lymph-nodes.
5. Distribution of the Lymph-nodes:
The Lymph-nodes of the Neck.
The Lymph-nodes of the Upper Extremity.
The Lymph-nodes of the Lower Extremity.
The Lymph-nodes of the Trunk Cavities.
V. Composition of the Blood:
1. The Blood-cells.
2. The Plasma.
VI. Characteristics of Child's Blood.
VII. The Heart:
1. The Pericardium.
2. The Shape and Size of the Heart.
3. Projection of the Heart on the Chest Wall.
4. Component Parts of the Heart.
5. The Heart Muscle.
6. The Lining of the Heart.
7. The Auricles.
8. The Ventricles.
9. The Valves of the Heart.
10. The Arteries and Veins of the Heart.
11. Nerves of the Heart.
VIII. How the Heart Works:
What Makes the Heart Contract?
IX. Sounds of the Heart.
X. Valvular Lesions of the Heart.
XI. Electrocardiography.

Development of the Circulatory System.—In simple one-celled organisms sources of food are in immediate contact with the limiting membrane of the cell (Fig. 4); in complex animals composed of many cells only the surface cells are exposed to the environment directly. In complex organisms, then, there is need for some kind of transport that will carry to the deeper cells the nutrients essential to life. The same situation exists regarding

the removal of waste; the ameba can give its waste directly into the medium surrounding the cell; man must have a system especially organized to remove from the deeper cells the waste products of the tissues.

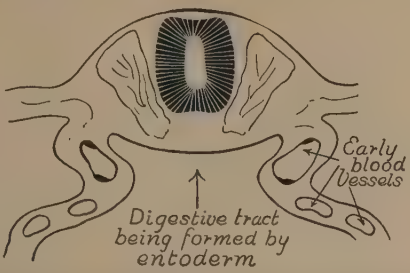

Fig. 243.—Small vessels in the visceral mesoderm.

The earliest stages of vessel formation have never been observed in man since the vessels are already established in the youngest embryos studied. Young embryos show vessels in the mesoderm; a cross section at an early stage reveals them as small circular openings (Fig. 243). Two conspicuous tubes near the margin of the developing digestive tube come together, fuse, and become the primitive heart (Fig. 244). Thus, from

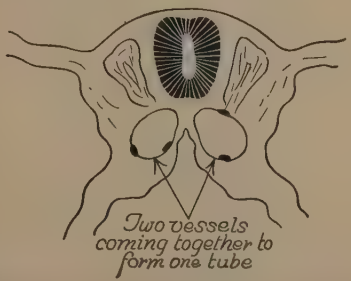

Fig. 244.—The heart aorta and other vessels are formed by the fusion of two vessels.

two tubes one is produced which later receives many vessels at one end and gives off at the other two vessels which formed it. A diagram of this is indicated in Fig. 245. The two vessels left by the union of their posterior portions are known as the *ventral*

aortæ. They continue forward to the head end of the embryo where they give off a number of arching branches which reach the dorsum of the embryo by passing in the arches of the early

Fig. 245.—One tube is produced from two.

gill-clefts (Fig. 246). As they swing from the ventral to the posterior segments they gradually converge and ultimately form

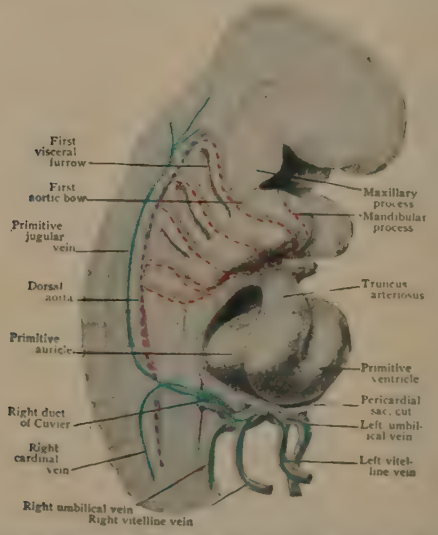

Fig. 246.—Reconstruction of upper part of human embryo of third week (3.2 mm.) showing relation of heart and blood-vessels; × 50 (drawn from His' model).

one vessel, the *dorsal aorta*, the forerunner of the main artery of the individual, the *aorta*. This situation may be diagrammed as shown in Fig. 247. Some of the branches of the gill arches

remain as parts of the upper divisions of the aorta; others disappear.

The heart itself as a tube soon alters its shape. An S-shaped twist is acquired (Fig. 248). From this stage by extensions

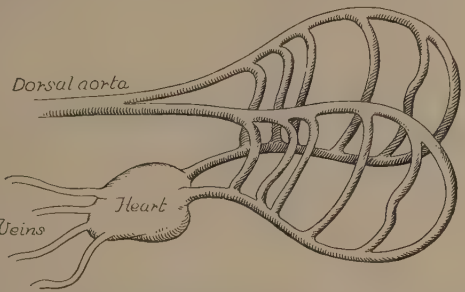

Fig. 247.—Two ventral aortæ give branches that contribute to vessels of the head. One of the branches makes the main arch of the aorta.

and further twisting of parts of the tube aided by certain internal changes, the four chambers of the developed heart are produced (Fig. 248). Before fusion of layers is complete the organ shows externally the developing auricles and ventricles. Internally a septum grows to divide the two auricles by a wall of tissue

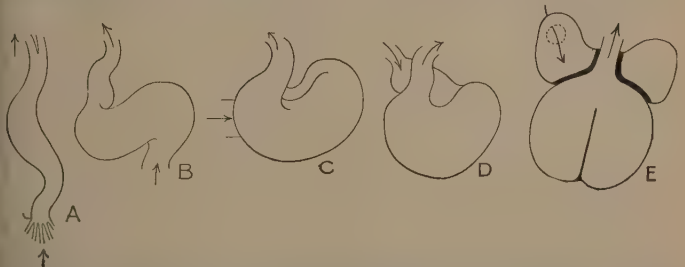

Fig. 248.—Diagram of stages in the development of the heart. A, Simple tube. B, S-formation. C, further twisting and enlargements. D, expansions to form ventricles and auricles. E, auricles and ventricles well defined. Arrows indicate direction of flow.

leaving an aperture that persists between them during the entire intrauterine life. Likewise in the ventricles a partition appears and at the same time horizontal plates develop to separate auricles from ventricles leaving apertures guarded by valves.

During the first month cells are noted within the vessels. These at first are nucleated. They later become the non-nucleated red corpuscles. During the second month white cells appear but their origin is shrouded in obscurity. The fluid portion, or blood plasma comes probably from mesodermic cells; later it is supplied by fluid from the placenta and after birth by food and drink.

The origin of lymphatics is not clear but when developed they present an accessory pathway for fluid from cell spaces to the vascular system. While the exact anatomical and physiological nature of these various parts will be described later it may be said now that the net result of this development is a movable or circulating tissue, the blood and lymph, the heart serving as a pump, and a system of vessels, or tubes, in which the blood and lymph are carried. This organization may be diagramed as follows:

- Circulatory system
  - Blood and lymph
  - Heart
  - Vessels
    - Blood-vessels
      - Arteries
      - Capillaries
      - Veins
    - Lymphatic vessels

General Arrangement of the Circulatory System.—The circulation of blood resembles in many respects the water-supply system of a city. Analogous parts are the heart and the force-pumps, the blood-vessels and the water-mains, the blood and the water circulated. The heart is similar to a pump; both have valves and both increase the pressure on their contained fluids, and hence cause them to flow.

Leading off from the heart are two large vessels, *arteries*, which distribute blood to two separate areas. One, the *pulmonary artery*, divides into numerous small vessels supplying the lungs; the other, the *aorta*, gives off many branches over a long course, furnishing a circulation to the entire body, except the lungs. The former is called the *pulmonary circulation*, the latter the *systemic circulation*. From the parts supplied by the pulmonary artery and aorta the blood is returned to the heart by a system of vessels, called *veins*. In the course of the systemic circulation is a special division beginning in the smaller veins of the digestive tract and ending in the liver. This is the *portal circulation*. The smallest divisions of the arteries and veins are known as *capillaries;* those

of the arterial tree are called arterial capillaries, and those of the venous branches, venous capillaries. This general arrangement is shown in Fig. 249.

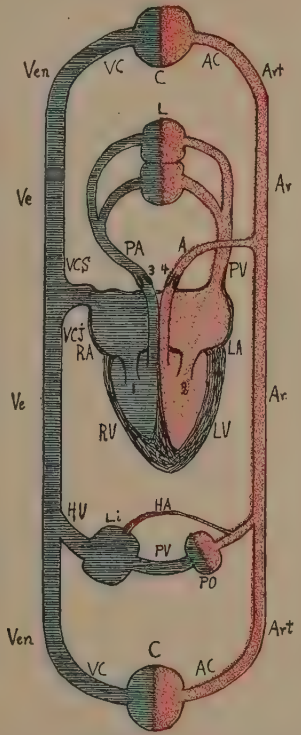

Fig. 249.—Schema of the circulation: *A*, Aorta; *Ar*, arteries; *Art*, arterioles; *AC*, arterial capillaries; *C*, capillaries; *VC*, venous capillaries; *Ven*, venules; *Ve*, veins; *VCS*, vena cava superior; *VCJ*, vena cava inferior; *RA*, right auricle; *RV*, right ventricle; *LA*, left auricle; *LV*, left ventricle; 1, tricuspid valve; 2, mitral valve; 3, pulmonary semilunar valve; 4, aortic semilunar valve; *PA*, pulmonary artery; *L*, lungs; *PV*, pulmonary veins; *PO*, portal organs; *PV*, portal vein; *HA*, hepatic artery; *Li*, liver; *HV*, hepatic vein. (Burton-Opitz.)

The Blood and Lymph.—The cells of the tissues of the body are supplied by a continuous flow of blood via the many vascular channels. In the blood are dissolved the salts, gases, and

nutrients necessary to life. In the smaller divisions of the vascular system some of the fluid passes out of the vessels. Later it returns to the circulation by means of the lymph vessels. Thus, the blood sent out by the heart is the source of the lymph.

The fluid remaining in the vascular channels reaches the heart via the veins. The part that passes from the capillaries to mix with the intercellular fluid surrounding the body cells returns via the lymphatic vessels to pour itself into large veins in the neck

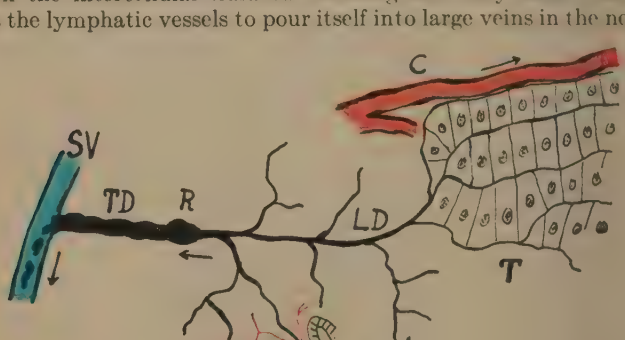

Fig. 250.—Scheme of the circulatory system of the lymph: *C*, Blood capillaries; *T*, tissue cells; *LD*, lymphatics; *L*, lacteals; *V*, villi of intestine; *Li*, liver; *R*, receptacle; *T.D*, thoracic duct; *S.V*, subclavian vein. (Burton-Opitz.)

just before these veins reach the heart. Without a provision for the return of this material to the circulation the tissues would soon be overloaded with lymph, a condition that develops at times due to obstruction of the lymphatic vessels.

This interposition of the lymph between body cells and blood is a great advantage. It serves to bring every cell of the body into functional relationship with the blood, and facilitates, therefore, the exchange of materials between blood and body cells.

The Lymphatic System.—The beginnings of the lymphatic system are in the spaces between the body cells. From these spaces the lymph is gathered into minute channels that ultimately lead it back to the circulation (Fig. 250).

Lymph.—Every cell in the body is surrounded by a fluid called *lymph*, composed of water with dissolved substances. From

lymph the cells obtain food and into lymph they discharge their waste material. The lymph is derived from blood, and returns ultimately to the blood. Its origin from the blood-vascular system is due to several factors; the very thin walls of the terminal divisions of the blood tubes allowing some of the liquid portion of the blood to pass out of the blood-vascular system into the spaces between the cells, certain physiochemical activities, the nature of which is not fully known, osmosis, and diffusion.*

Due to factors in part known and unknown fluid may accumulate in the tissue spaces producing *edema*. When excess fluid collects in the pleural cavity it is called an *effusion*.

Lymphatic Vessels.—The smallest lymphatic vessels are formed by adjoining cells whose limiting membranes mark the intercellular spaces and the beginnings of the lymphatics (Fig. 250). Definite tubules with very thin delicate walls composed of flat, plate-like cells lead from these channels between the cells. Larger vessels are marked by a certain amount of connective tissue, strengthening the walls and increasing their size. The largest lymph vessels, called *ducts*, attain a diameter of several millimeters. The smaller lymphatic vessels contain valves which only open in one direction. The site of the valves is marked by a constriction in the vessel, thus giving a peculiar ribbed appearance (Fig. 253).

The lymphatic vessels are distributed widely throughout the body. The skin, muscles, bones, and organs are supplied liberally. The pleural, pericardial, peritoneal, and synovial cavities belong to this system and drain into the lymphatics through small openings in the lining membrane.

The Main Lymphatic Channels.—The lymph from the lower extremities, the abdomen, the left side of the chest, the lower half of the right side of the chest, and the left arm is gathered by the smaller lymphatics into one main duct, called the *thoracic duct*. The right arm and upper right side of the chest are drained by the *right lymphatic duct*. The right and left sides of the head are drained respectively by the *right* and *left cervical lymphatics* (Fig. 251).

The thoracic duct is distinctly the largest and most prominent. In man it is 38 to 45 cm. (15–18 inches) in length, extending from the second lumbar vertebra to the root of the neck. It com-

* According to the views of Starling the osmotic pressure of the blood protein draws back into the vessels some of the fluid that has escaped. See Starling: Human Physiology, p. 1069.

mences in the abdomen in a pronounced swelling (the receptaculum chyli), and lies to the left and behind the aorta. Extending upward, it gradually swings to the left side to empty into the blood-vascular system at the junction of the left jugular and left subclavian veins (Fig. 252).



Fig. 251.—The distribution of the lymphatics. *A*, The domain of the thoracic duct (unshaded portion); *B*, right lymph duct; *C*, left cervical duct; *D*, right cervical duct. (Burton-Opitz.)

The right lymphatic duct and right cervical duct empty into the right subclavian.

Lymph-nodes.—At frequent intervals and particularly near joints the lymphatics are interrupted by solid, glandular bodies, called *lymph-nodes*. They vary in size normally and may, when irritated by the poisons of a disease process, become much

enlarged.* These nodes are covered by a layer of connective tissue called a capsule. From this capsule numerous bands of

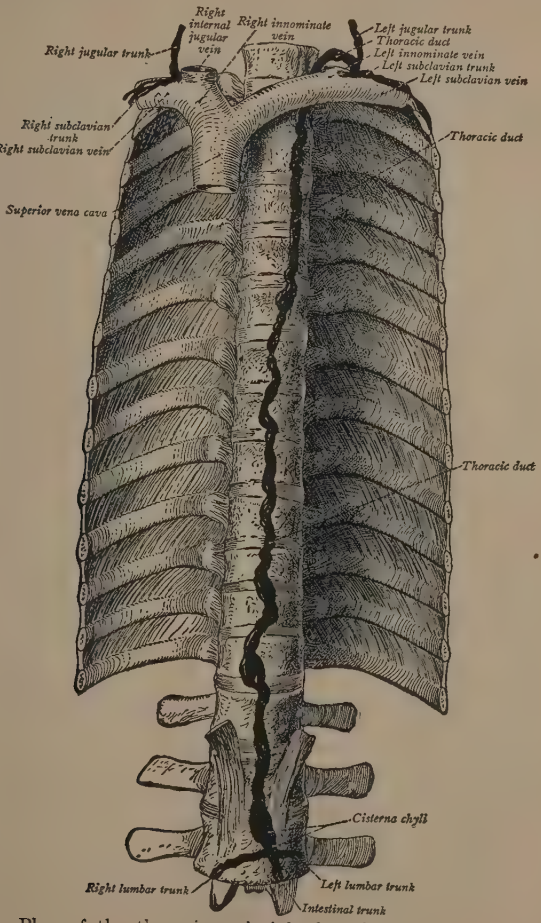

Fig. 252.—Plan of the thoracic and right lymphatic ducts (Sobotta and McMurrich).

tissue dip into the gland, forming partitions. Between these

* Adenitis is an inflammatory enlargement of the lymph-nodes.

partitions there is the substance of the gland, made up of small ameboid cells, known as *lymph corpuscles, lymphoid cells,* or *lymphocytes.* These may give rise to certain cells found in the blood-stream.

These nodes are marked by the incoming (afferent) and outgoing (efferent) lymphatics (Fig. 253). The incoming ones are more numerous and smaller; the outgoing vessels are formed by a coalescence of numerous finer tubules.

Fig. 253.—A lymph-node with its afferent and efferent vessels (Testut).

In the infant and child the lymphatic nodes are very large, but with advancing age the size decreases until in old age many of the nodes apparently disappear.

Distribution of the Lymph-nodes.—The lymph-nodes, serving as central receiving stations toward which many lymphatics converge, are distributed along the course of the lymphatic vessels. In certain areas they are more numerous. Some are superficial, lying just under the skin. Others are deep. The prominent ones are:

The Lymph-nodes of the Neck (Fig. 254). These comprise, in the main, a row of glands just under the ramus of the jaw. They

drain the floor of the mouth and anterior part of the temple. Another group is distributed along the sternomastoid muscle. These drain the back of the tongue, the pharynx, nasal fossæ, roof of the mouth, and face. Somewhat posteriorly is a smaller group draining the scalp. Roughly these glands can be divided

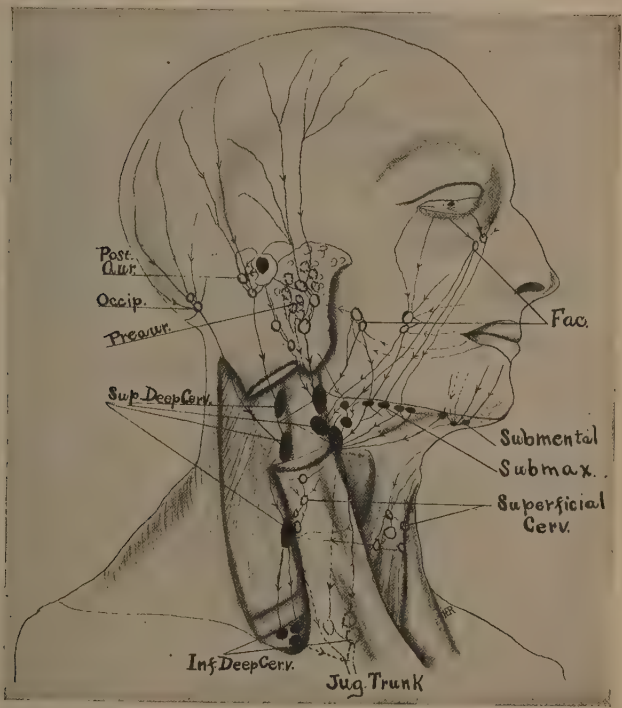

Fig. 254.—Lymph-nodes and lymphatic drainage of the head and neck. Superficial nodes indicated as circles, deep nodes in solid black (Radasch).

into an anterior, middle, and posterior group. The anterior group is frequently enlarged in inflammatory conditions of the gums of the lower jaw and infection of the teeth; the middle group responds to tonsillar infection and is often the site of a tubercular process (tubercular adenitis); and the posterior group shows enlargement following infection of the scalp, as in pediculosis and other parasitic conditions.

The Lymph-nodes of the Upper Extremity: These comprise the nodes shown in Fig. 255. There is a small group in the hollow of the elbow-joint, a larger group in the axilla, and a still larger group under the pectoral muscles. The first drains the hand and

Fig. 255. Lymph-nodes and lymphatic drainage of the upper extremity, mammary gland, and thoracic wall: *R.L.D*, Right lymphatic duct. (Radasch.)

forearm, the last drains the mammary gland, skin, and muscles of the chest; the middle group receives branches from the other two. Infection of the hand may be marked by enlargement and tenderness of the axillary glands, and if pronounced the course of the lymphatics themselves may be outlined by red lines indicating an inflammation of the walls of the lymphatic vessels.

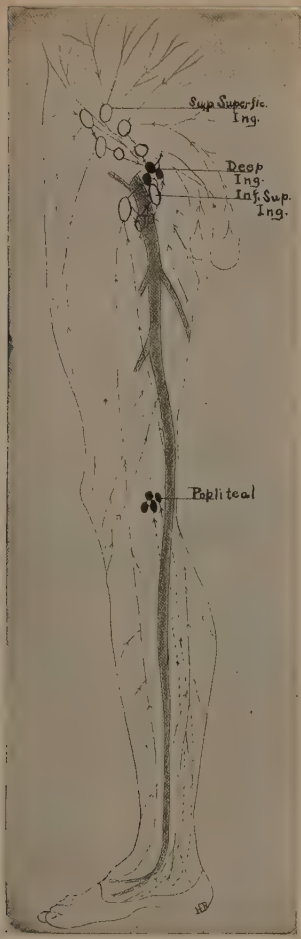

Fig. 256.—Lymph-nodes and lymphatic drainage of the lower extremity (Radasch).

The Lymph-nodes of the Lower Extremity: The nodes of this region are massed in the groin, or inguinal region, marked by the fold or depression between abdominal wall and thigh. These

glands drain the lower extremity and the lower part of the abdominal wall (Fig. 256).

The Lymph-nodes of the Trunk Cavities: These comprise a group of glands in the pelvis, another aggregation at the beginning of the thoracic duct, and a third group in the thoracic cavity.

Fig. 257.—Tracheobronchial lymph-nodes (Radasch).

The different organs have important groups definitely placed. The lymphatics of the lungs drain into nodes grouped around the root of the lungs (Fig. 257); the stomach and intestines drain their lymph supply into nodes placed in the mesentery of these organs.

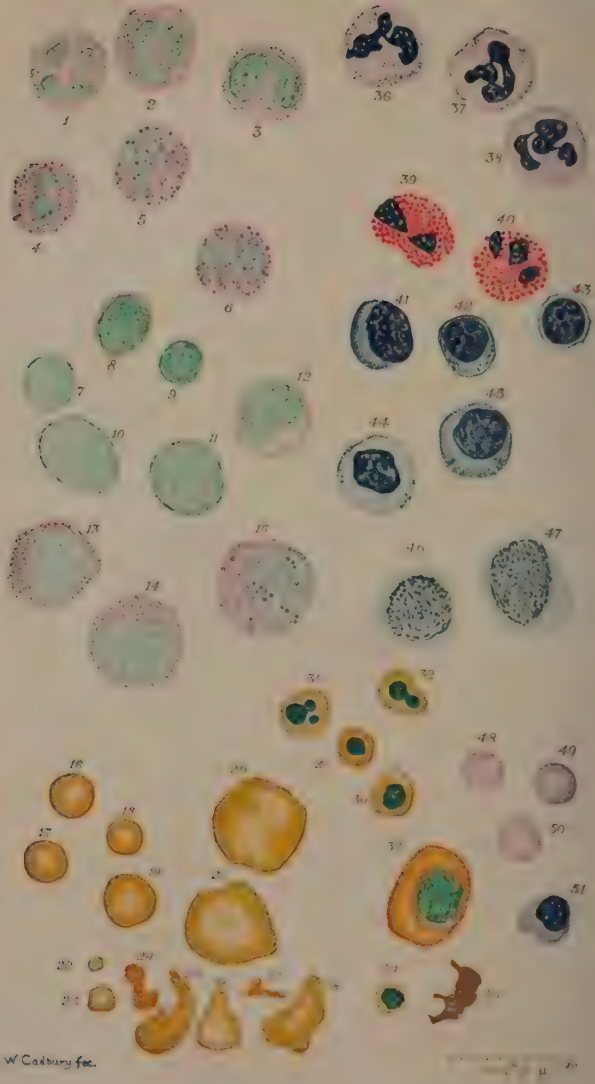

Fig. 258.—For description, see facing page.

Composition of the Blood.—The blood is a bright red fluid. In the arteries it has a scarlet cast and in the veins a crimson hue; it is viscous and slightly heavier than water; its specific gravity is about 1.055. It consists of a watery portion, the *plasma*, and various solids, the *cells* (Fig. 258). The following tabulation of the composition of the blood has been given elsewhere:*

- Blood
  - Cells
    - Red blood-cells
    - White blood-cells
      - Leukocytes
      - Lymphocytes
    - Platelets
  - Plasma
    - Water
    - Gases
      - Oxygen
      - Carbon dioxide
      - Nitrogen
    - Food-stuffs
      - Carbohydrates—glucose
      - Fat—fatty acids
      - Protein
        - Serum albumin
        - Serum globulin
        - Fibrinogen
    - Salts
      - Chlorids
      - Carbonates
      - Sulphates
      - Phosphates
      - Silicates

      of

      - Calcium
      - Sodium
      - Magnesium
      - Potassium
      - Iron
    - Protective substances
      - Opsonins
      - Agglutinins
      - Bacteriolysins
    - Autacoids—internal secretions from ductless glands.
    - Waste substances

urea	hypoxanthin
uric acid	guanin
creatin	adenin
xanthin	carnin

The Blood-cells.—The red corpuscles, or erythrocytes, number about 5,000,000 per cubic millimeter in men and about 4,500,000

* Williams, J. F.: Personal Hygiene Applied, W. B. Saunders Co., Philadelphia, 1928.

Fig. 258.—Various forms of blood-corpuscles—leukocytes and erythrocytes. Figures 1 to 35, inclusive, stained with Ehrlich's triple mixture; Figure 36 to 51, inclusive, stained with eosin and toluidin-blue, as recommended by Harris; 1, 2, 3, polymorphonuclear neutrophils; 4, 5, 6, eosinophils; 8, small lymphocyte; 12, large lymphocyte; 7, 9, small lymphocytes (from the blood in lymphatic leukemia, showing atypical staining reaction); 10, 11, large lymphocytes (also showing atypical staining); 13, 14, myelocytes (with neutrophilic granules); 15, myelocyte (with eosinophilic granules); 16, 17, erythrocytes; 18, 19, erythrocytes showing normal variation in size; 20, 21, macrocytes; 22, 23, microcytes; 24, 25, 26, 27, 28, poikilocytes; 29, 30, normoblasts; 31, 32, red blood-cells, showing irregularly shaped nuclei; 33, megaloblast; 34, microblast; 35, erythrocyte, showing degenerative changes as demonstrated by the polychromatophilic reaction; 36, 37, 38, polymorphonuclear leukocytes; 39, 40, eosinophils; 41, 42, 43, small lymphocytes; 44, 45, large lymphocytes; 46, 47, myelocytes; 48, 49, 50, erythrocytes; 51, normoblast. (Salinger and Kalteyer.)

per cubic millimeter in women. These cells, while extremely important, are not the most conspicuous elements in the blood (Fig. 258). They appear as flat, circular, disk-like bodies, with a central depression where the nucleus has been. In the bone-marrow the red cells are nucleated and are called erythroblasts. During life there is a constant destruction and replacement of the red corpuscles. They wear out apparently from the work they do in the circulating blood and are destroyed in the liver. The marrow of the bones is constantly replacing the supply destroyed.

Fig. 259.—Migration of leukocytes (Burton-Opitz).

The striking characteristic of the red cell is its content of *hemoglobin*. This substance, hemoglobin, is an iron-protein compound that has the property of uniting with oxygen. The hemoglobin of the red cells secures oxygen as the blood passes through the lungs. When combined with oxygen it is called *oxyhemoglobin*, which gives a crimson color to the blood. In the tissues the oxyhemoglobin gives up part of its oxygen to the cells, and is then known as *reduced hemoglobin*. The blood now appears a crimson hue, which when seen through the skin has a purplish cast. The color distinction made between arterial and venous blood is due, then, to the relative amount of oxygen in combination with the hemoglobin of the cell.

The white corpuscles number about 6000 to 10,000 per cubic millimeter of blood. They vary considerably in number, and under certain conditions may be greatly increased or decreased. They are capable of an ameboid motion, and hence may escape from the walls of the containing vessels into the tissues (Fig. 259). This power enables them to destroy foreign particles not only in the blood-stream but also in the tissue spaces. In the latter place they carry on a relentless warfare with invading pus-producing bacteria. Injury to the body cells or infection by bacteria results in a condition known as *inflammation*.[1] This is marked by certain changes in the blood flow and in the migration of leukocytes. The stages of inflammation are as follows:

1. The first stage is a preliminary contraction of the vessels of the part with a later dilation and slowing of the blood-current. The quantity of blood in the part is greatly increased, the small vessels becoming distended.

2. In the course of an hour (as observed experimentally in the frog) the blood flow is slowed further, and the leukocytes increasing in great numbers in this area are arranged along the outer part of the blood-stream, the so-called "margination of the leukocytes."

3. Soon after the margination of the white cells there begins the passage through the walls of the blood-vessels. This is the migration of the leukocytes. Reaching the area that has been irritated, these cells engulf irritating particles (Fig. 66), or if the active agent is bacteria, they begin battle with these poisonous invaders.

4. If the cause of the inflammation is bacterial, the migrating leukocytes may completely overwhelm the invading organisms and remove the cause. In other cases, where the bacteria are specially virulent or in exceedingly large numbers, many leukocytes will be killed in the process, with disintegration and dissolution of the dead cells, forming *pus*. An examination of pus will show leukocytes in various stages, some completely broken down, others with well-formed elements and only slight changes (Fig. 260).

This process of inflammation accounts for the symptoms of the condition. Redness, swelling, heat and pain are due to the increased vascularity of the part. The redness represents the greater number of red cells present, the swelling corresponds to the greater quantity of blood and lymph present, the heat of the part represents the hotter blood* of the deeper parts, and the pain reflects the extreme pressure made upon the nerves of the part involved. Inflammation in bone is extremely painful because of the unyielding character of the tissue and the correspondingly greater pressure. The great and immediate relief from pain after incision of an abscess illustrates the influence of pressure on the part in the production of such pain.

The blood-platelets, or thrombocytes, are smaller than the red or white corpuscles. They appear as irregular protoplasmic

* The temperature of the blood is higher in the deeper structures of the body. The blood in the veins of the liver may attain a temperature of 39.7° C. (103° F.), while that in the fingers, nose, and cheeks may possess a temperature of only 36° C. (97.7° F.).[2]

bodies, extremely fragile, and at times nucleated. They play an important part in coagulation of the blood. (See page 82.)

The Plasma.—Burton-Opitz gives the water content of the blood to be 77 to 82 per cent. The gases—oxygen, carbon dioxid, and nitrogen—are dissolved in the plasma; the first is carried also in chemical combination in the red cells. The food-stuffs make



Fig. 260. Film made from peritoneal fluid in case of peritonitis set up by inoculating Bacillus coli twenty-four hours previously into the abdominal cavity of a rabbit (Beattie): *Polyn.*, Polynuclear leukocytes, many containing bacilli; *l.m.*, large mononuclear cells, many acting as phagocytes for polynuclear cells, red corpuscles, etc.

up a large portion of the dissolved solids. This is fully described in Chapters XIV and XV. The mineral salts are numerous, but sodium chlorid is most abundant. The autacoids will be described in Chapter XVIII and the waste substances in Chapter XVI. Of the tabulation given on page 299, there remains the protective substances.

Immunity: Animal bodies possess the power of protecting themselves against various poisonous substances, notably bac-

erial toxins. This power of protection is spoken of as *resist-nce* and the condition developed by the power as *immunity.*[3] t is a well-known fact that some persons and certain races are mmune to certain diseases. Such immunity is natural and *nherited.* Also, it is known that immunity may be *acquired* either ccidentally by having the disease or experimentally by inocu-ation. Although some diseases may be experienced more than nce, it is usual for smallpox, typhoid fever, scarlet fever, diph-heria, and others to give immunity.

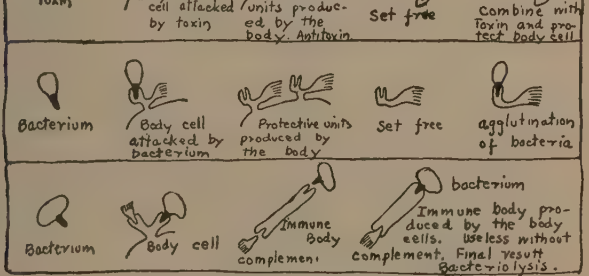

Fig. 261.—There are three types or orders in the development of protec-ion according to Ehrlich's hypothesis. In I toxin joining chemically with body cells stimulates the formation of antitoxin. The antitoxic units set free join with the toxins and render them harmless. Explanation of the procedure in diphtheria. In II bacteria attacking the cells stimulates the formation of immune substances which contain an enzyme which acts to coagulate or agglutinate bacteria. Explanation of the agglutination phenomena in typhoid fever. In III bacteria attacking the cells stimulates the formation of immune substances which require the presence of a sub-stance free in the blood known as complement. When complement is present and joins with the immune substance the bacterium is destroyed. Phenomenon known as bacteriolysis. The same phenomenon is utilized in the hemolysis of red blood-cells by the use of a foreign protein (after Aschoff).

Recent developments in the study of these protective reactions have enlarged for man the use of this mechanism, so that today in numerous cases it is possible to artificially produce resistance to a specific disease by introducing into the blood the immune sub-stances derived from another animal that has been immunized, and by stimulating the body to produce protective substances

through the introduction of various forms of bacterial cultures. The former is known as *passive acquired immunity* and the latter as *active acquired immunity*. Examples of passive acquired immu-

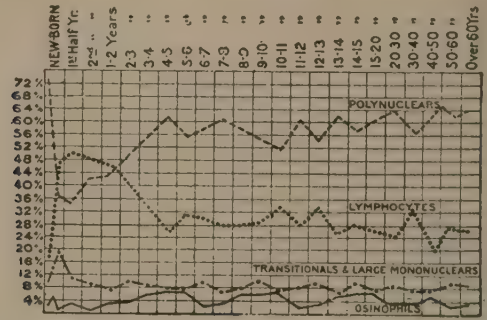

Fig. 262.—Chart showing the percentages of the various leukocytes from birth to old age (Hutchison's Lectures on Diseases of Children, Edward Arnold).

nity are the inoculations for diphtheria, tetanus, and Type I pneumonia. Examples of active acquired immunity are vaccinations for smallpox, and typhoid fever.

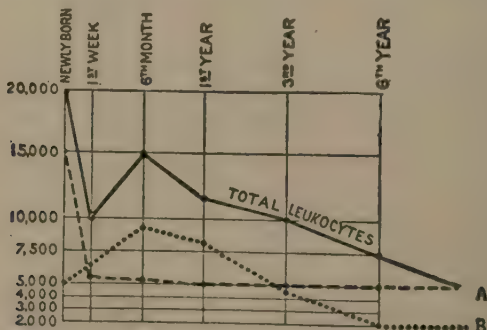

Fig. 263.—Chart showing the leukocyte counts from birth to six years (Hutchison's Lectures on Diseases of Children, Edward Arnold).

The exact nature of the immunity phenomena is not known. Ehrlich's side-chain theory is favorably looked upon, but not universally accepted (Fig. 261). It is agreed that the process is a physiochemical one acting either to build up cellular resistance in

some way or to neutralize the poisonous toxins of the disease concerned.

Anaphylaxis: Immunity is a resistance, either inherited or acquired, to toxins. Anaphylaxis as a phenomenon of the blood

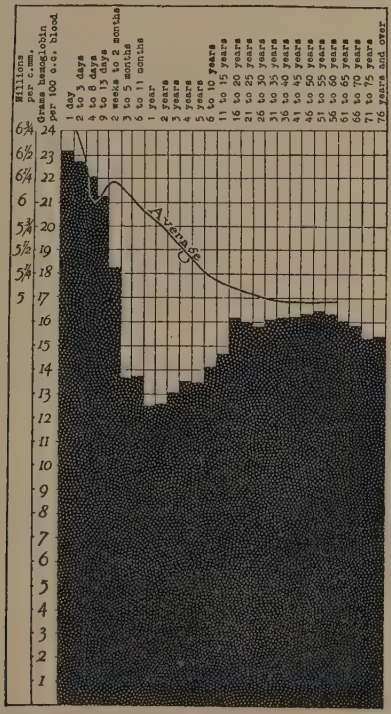

Fig. 264.—The solid block line indicates grams of hemoglobin per 100 c.c. of blood in persons ranging in age from one day to over seventy-six years. The curved line shows the average erythrocyte count at different ages to show the relationship between the number of erythrocytes and their hemoglobin content (from Archives of Internal Medicine, October, 1922).

is an increased susceptibility to certain proteins as a result of previous injections of even small amounts of the particular protein into the blood.[4] Thus, anaphylaxis has been observed after the administration of diphtheria antitoxin. The exact

nature is not known, but as a reaction in the use of immune sera it is perfectly definite in certain individuals.

Characteristics of Child's Blood.—The blood of a child has higher specific gravity than the blood of an adult, except at birth, when it is the same. This holds true up to the age of fourteen years. The boy's blood is usually heavier than the girl's due a greater proportion of hemoglobin. The greater number of red cells in childhood accounts in part for the higher specific gravity. Feldman* quotes Gundobin as follows:

Age.	Number of red corpuscles per cubic millimeter.		
	Average.	Maximum.	Minimum.
0– 6 months	5,500,000	6,100,000	4,900,000
6–12 "	5,600,000	6,100,000	5,100,000
1–14 years	5,890,000	6,200,000	5,000,000
Adult	5,000,000	5,500,000	4,500,000

At birth and during childhood the leukocytes of the blood are more numerous than in the adult. Scipiades† gives the following:

1st day	19,268
2d day	14,248
3d day	10,234
4th day	9,104
5th day	8,893
6th day	9,450
7th day	10,564
8th day	11,000
9th day	10,530
10th day	9,180

Karnitzki gives the following:

1– 2 years	11,400
2– 3 years	9,450
3– 4 years	8,900
8–10 years	7,900
12–14 years	7,590

The variation in the percentages of the different leukocytes from birth to old age, in the total leukocyte count from birth

* Feldman, W. H.: Prenatal and Postnatal Child Physiology, Longmans, Green & Co., New York, 1920, pp. 411–447.

† Feldman, W. H.: Prenatal and Postnatal Child Physiology, Longmans, Green & Co., New York, 1920, p. 416.

to the sixth year, and in percentage of hemoglobin and red cells* are shown in Figs. 262–264.

The Heart.—When fully formed the heart is a hollow muscular organ attached to vessels at its upper end (Fig. 270). Its lower part rests on the diaphragm (Fig. 265). Situated in the thorax

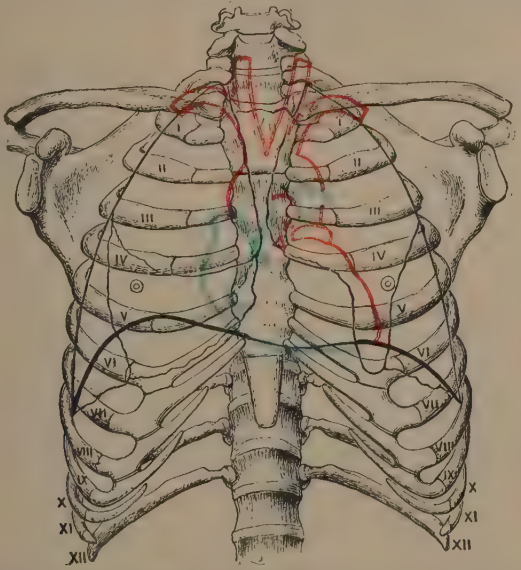

Fig. 265.—Showing location of apex beat. The position of the aortic semilunar (+) and mitral (△) valves are indicated in red and that of the pulmonary semilunar (+) and tricuspid (△) in blue. (Burton-Opitz.)

between the two lungs, it occupies an anterior position with part of its structure against the chest wall. It lies in a membranous sac, called the *pericardium.*

The pericardium is an invaginated sac (Fig. 266) that invests the heart. It gives two layers to the covering: an external fibrous portion, and an internal serous portion. The *external fibrous layer* is a strong membranous structure firmly attached, below to the

* Meyers, L. H. (Archives of Internal Medicine, October, 1922, 30, 478). reports a higher average of red cells than that given by Gundobin. In a series of 41 infants the average was 7,630,000. The decrease in number during the first year is very great, as is also the fall in hemoglobin percentage. The relation between hemoglobin and erythrocytes is shown in Fig. 263.

upper surface of the diaphragm, in front by a fibrous band to the posterior aspect of the sternum, and above by fibers over the great vessels blending closely with their outer coverings. The *internal serous layer* invests the heart and is then reflected upon itself to

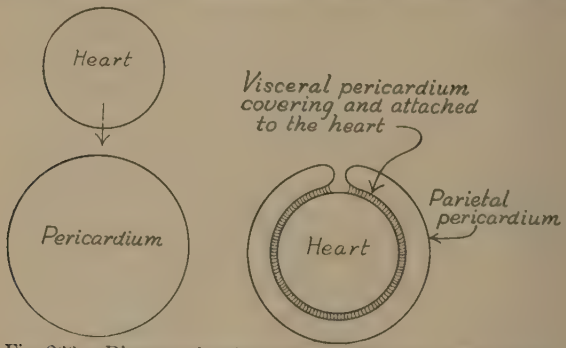

Fig. 266.—Diagram showing invagination of the pericardium.

line the inner surface of the fibrous layer. It will be seen, therefore, that the heart is surrounded by a covering of membrane (Fig. 267) which is so arranged that it forms a separate sac outside the heart (Fig. 271). This structure is simulated if one will cover the fist with a handkerchief and then, as the parts fall

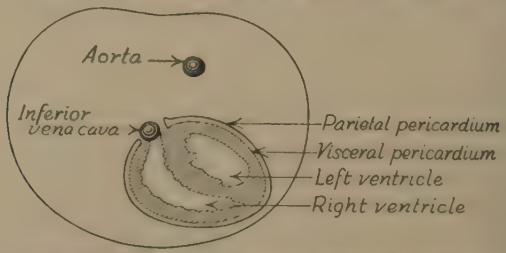

Fig. 267.—Diagram of pericardial sac in cross section.

around the wrist, turn them back (reflect) over the already covered portion. The utility of a sac within which the heart can move easily is very great. Figures 268 and 269 show the movement of the heart toward the chest wall during contraction.

Within the closed sac formed by the serous pericardium is a small amount of clear fluid, called the *pericardial fluid*. The

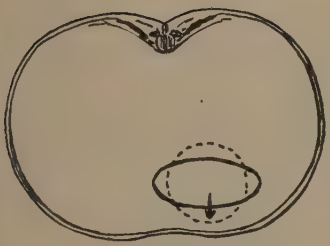

FIG. 268.

FIG. 269.

Fig. 268.—Diagram of the heart and its change in shape during contraction. This diagram should be interpreted as showing the heart in systole (dotted line) nearer the chest wall. Transverse section (Burton-Opitz.)

Fig. 269.—Vertical and anterio-posterior diagram to show how the apex of heart moves to the wall of the chest during contraction (Burton-Opitz).

smooth character of the serous surfaces and the lubricating nature of the pericardial fluid seem to minimize the friction that would result otherwise from the continued contractions of the heart.

The Shape and Size of the Heart.—The heart is somewhat conical in shape with the apex pointing downward and to the left. It varies in size with age, sex, and physical work. At birth the infant's heart in relation to the body weight is relatively heavier than the adult's, the proportions as given by Feldman being 0.89 and 0.52 per cent. respectively. The following table* of size indicates the difference due to age and sex:

* Compiled from figures by Feldman,[1] Piersol,[2] and Gray.[3] Adult figures do not indicate sex.

Age.	Length in centimeters.		Breadth in centimeters.		Thickness in centimeters.	
	Boys.	Girls.	Boys.	Girls.	Boys.	Girls.
1– 4 years[1]	5.14	5.1	6.09	5.84	2.44	2.28
5– 9 years[1]	7.04	6.0	7.44	6.54	2.89	2.55
10–15 years[1]	7.67	6.63	8.35	7.04	3.16	2.80
Adult[2]	12 to 15		9 to 11		5 to 8	
Adult[3]	12.5		8.7		6.2	

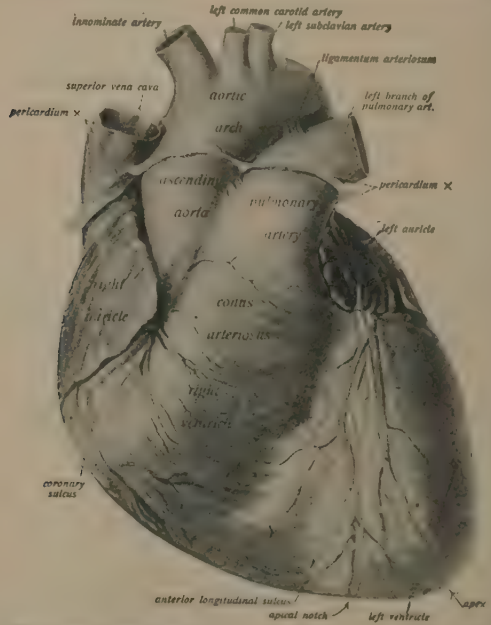

Fig. 270.—The heart seen from in front, the sternocostal surface (Sobotta and McMurrich).

Projection of the Heart on the Chest Wall.—The position of the heart in the thorax, its shape and size, are given quite clearly by carrying forward as horizontal lines the marginal outlines of the organ. Such a projection of the heart on the chest wall shows the

base directed upward, the apex downward, and the greater bulk of the heart to lie to the left of the midsternal line (Fig. 272). The apex in the adult normally lies in the fifth space, 8 to 9 cm. ($3\frac{1}{4}$–$3\frac{1}{2}$ inches) to the left of the midsternal line. In infants up to one year the apex lies outside the nipple line (actual distance varies from 5 to 7 cm. from midsternal line) and at a higher level

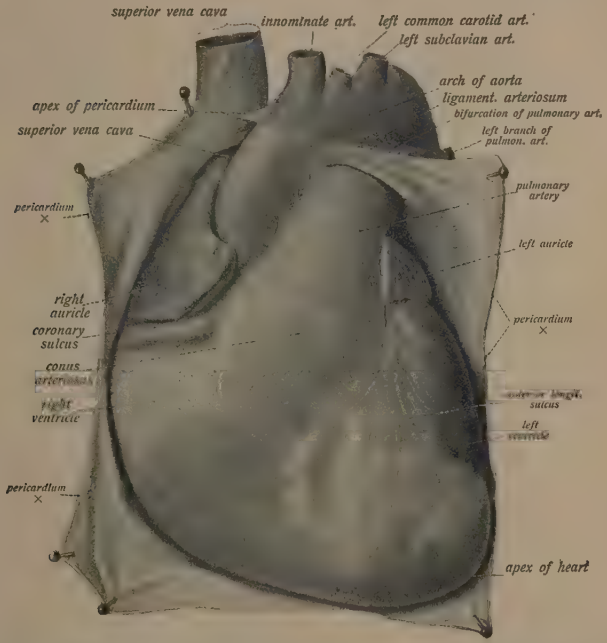

Fig. 271.—The heart enclosed in the pericardium, seen from in front. The pericardium has been opened in front (Sobotta and McMurrich).

than in adults, usually in the fourth space. With increasing age the apex tends to descend and the heart takes a more vertical position, so that at seven years the apex is at the nipple and from that age falls inside the nipple.

In the normal young adult the heart projection lines may be drawn on the chest as follows: From the second space left at a point $1\frac{3}{4}$ inches from the midsternal line draw a line convex to

the left to the apex; from the second space right at a point 1¾ inches from the midsternal line draw a line slightly convex to the right to the junction of seventh costal cartilage and sternum; and from the ending of the first line draw a line to the ending of the second. This latter gives the lower margin.

Component Parts of the Heart.—If the heart is removed from its pericardial sac and separated from the great vessels its intrinsic

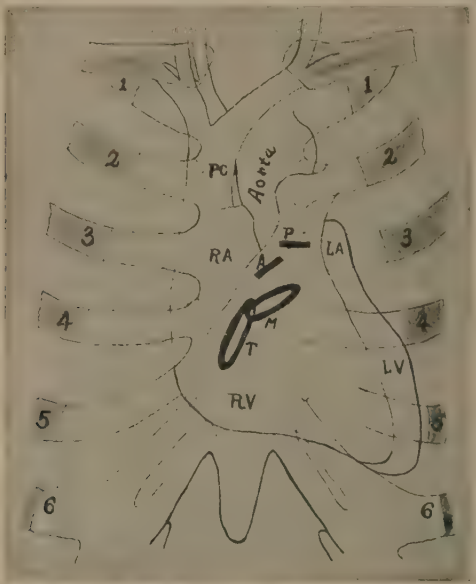

Fig. 272.—Diagram of the heart and valves in relation to the skeleton of the ventral thoracic wall: *PC*, Superior vena cava; *RA*, right auricle; *RV*, right ventricle; *LA*, left auricle; *LV*, left ventricle; *P*, pulmonary valve; *A*, aortic valve; *M*, mitral valve; *T*, tricuspid valve. (Radasch.)

structure may be studied. Although a hollow organ, its cavity is divided into four compartments. On opening the organ it will be seen to be divided by a vertical muscular partition into right and left parts. The right and left halves are further divided, yielding upper and lower chambers. The upper cavities are the auricles; the lower, the ventricles. It will be observed that there are right auricle and right ventricle, left auricle and left ventricle

(Fig. 273). The vertical partition is complete and intact (see p. 355 for variation before birth); the hortizontal contains orifices between auricles and ventricles, the *atrioventricular valves.* The valve between the right auricle and right ventricle is the *tricuspid valve*, the one between the left auricle and left ventricle is the *mitral valve.* Entering the right auricle are two large veins, the

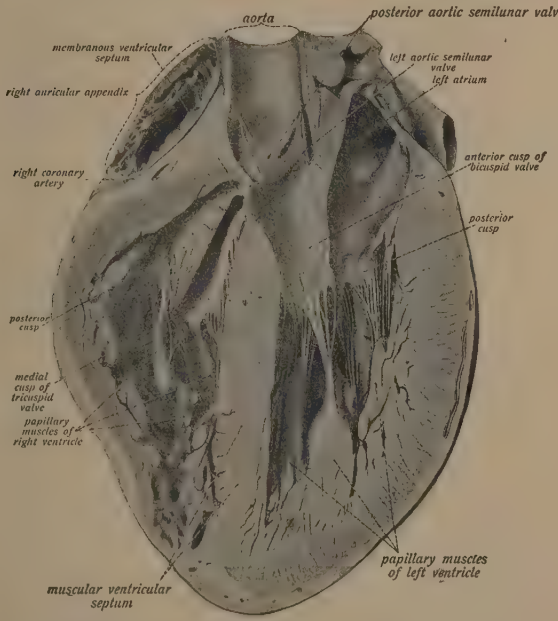

Fig. 273.—Frontal section of the heart, especially of the two ventricles. Anterior half seen from behind (Sobotta and McMurrich).

superior vena cava and the *inferior vena cava;* entering the left auricle are the four *pulmonary veins.* These entering vessels contain no valves, although the eustachian valve in the right auricle has a valvular action on the blood from the inferior vena cava. Leaving the ventricles are the *pulmonary artery* from the right and the *aorta* from the left. These orifices are guarded by valves, the *semilunars.* Diagrammed (Fig. 274) these facts would appear as follows:

- **Heart**
  - Valves
    - Atrioventricular valves — Tricuspid on right side; Mitral (bicuspid) on left side
    - Semilunar valves — Pulmonary semilunars on right side; Aortic semilunars on left side
  - Orifices
    - Entering ones — Superior vena cava, Inferior vena cava (on right side); Pulmonary veins on left side
    - Emerging ones — Pulmonary opening on right side; Aortic opening on left side
    - Between auricles and ventricles — Tricuspid on right side; Mitral (bicuspid) on left side

The Heart Muscle.—The heart is composed chiefly of muscle cells characteristic of this organ (see page 76). These cells

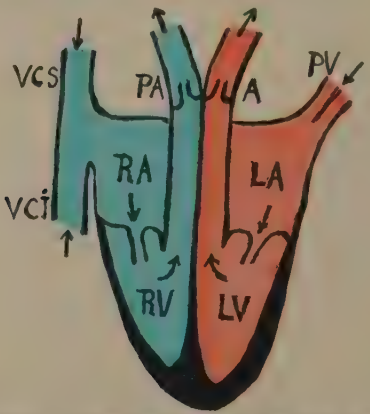

Fig. 274. Diagram to show the course of the blood through the higher type of heart: *VCS* and *VCI*, superior and inferior vena cava; *RA*, right auricle; *LA*, left auricle; *RV*, right ventricle; *LV*, left ventricle; *PA*, pulmonary artery; *PV*, pulmonary vein; *A*, aorta (Burton-Opitz).

possess the quality of automaticity in that they contract rhythmically in consequence of an as yet unknown cause. The term "myocardium" is used to refer to the muscle of the heart. In the auricles the myocardium is thin compared to the ventricles, and in the ventricles the left shows a marked superiority in thickness over the right (Fig. 273). In infants and young children the muscle-fibers are smaller and of finer structure than in adults. Within the ventricles the myocardium is formed in numerous irregular projections called *papillary* muscles, to which

are attached fibrous bands, the *chordæ tendineæ*, of the atrioventricular valves.

The Lining of the Heart.—The inner surface of the heart cavities is covered by a smooth, delicate layer of flat cells (mesothelium) to form a complete investment of all structures within the heart. This covering is called *endocardium.* It covers the muscular portions, the valves, and chordæ tendineæ. Injury of

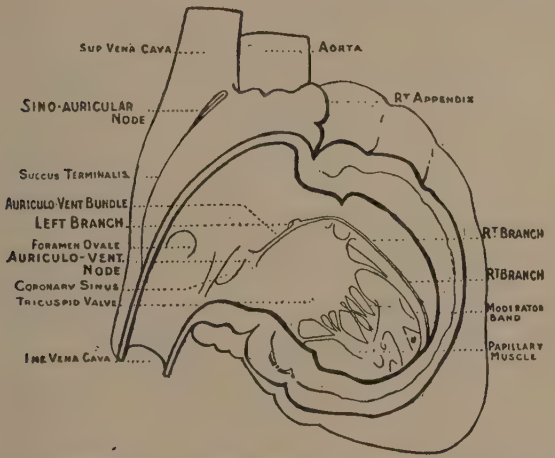

Fig. 275.—Diagram of a human heart. The walls of inferior vena cava, right auricle and right ventricle have been partially removed to expose the septa. The position of the sino-auricular node, in which the heart-beat commences, is shown, as are also the position of the auriculoventricular trunk or bundle of His. The last-named structure conveys the contraction wave from auricle to ventricle (Thomas Lewis).

the valves resulting from inflammatory processes is named, therefore, *endocarditis.*

The Auricles.—At the opening of the superior vena cava into the right auricle there is a small swelling called the *node of Tawara* or the *sino-auricular node.* This node (Fig. 275) comprises certain nervous tissue which is continued downward toward the apex of the heart, crossing in the auricular wall, and then following the interauricular and interventricular septum, to end in the papillary muscles. This band of muscular nervous tissue is called the *atrioventricular bundle* or *bundle of*

His. On the interauricular septum is a depression, the *fossa ovalis,* which corresponds to the foramen ovale of the fetus (page 357). Between the orifice of the inferior vena cava and the tricuspid valve is the *eustachian valve.* In the adult, when present, it may serve to prevent a reflex of blood into the inferior vena cava. In the fetus it is of large size and serves to direct the flow of blood into the left auricle. Numerous small openings in the walls of the auricles return blood from the heart muscle to the cavities of the heart.

The Ventricles.—The bulk of the heart is the ventricles. In infants the wall of the right ventricle is equal in size to the left, but after the first weeks the left shows a greater proportion, which in adult life is slightly more than 2:1. The papillary muscles are smaller, but more numerous on the left side than on the right.

The Valves of the Heart.—The orifices between auricles and ventricles are supplied with the atrioventricular valves, the *tricuspid* on the right and the *mitral* (*biscuspid*) on the left. The former has three cusps, the latter two. These valves are thin transparent flaps of connective tissue covered with endocardium. They are attached to the margins of the orifice between the heart chambers and their free edges are fastened to strings of fibrous tissue, the *chordæ tendineæ.* This structural arrangement permits free opening of the valves inward to the ventricles, while the chordæ tendineæ prevent the valve flap from opening into the auricles.

The openings of the pulmonary artery and aorta are guarded by the semilunar valves.* These are half-moon-shaped cusps attached to the arterial wall in such fashion that blood from the ventricles passes easily into arteries, but its flow back to the ventricles is prevented by the closure of the valves. They appear as collapsible buckets, filling and blocking the openings when the pressure of the blood in the arteries forces the flow toward the heart. The ones guarding the pulmonary orifice are called the *pulmonary semilunar valves;* the ones at the aorta, the *aortic semilunar valves.*

The Arteries and Veins of the Heart.—Just above the commencement of the aorta there are three small dilations called the *sinuses of Valsalva.* One lies anterior and two are in a posterior

* These valves might well be described with the arteries except for the custom that relates them to the heart, and the other important fact that they form important structures in auscultation of the heart.

position. These dilatations correspond with the position of the aortic semilunar valves. Just beyond the valves in the anterior sinus and in the left posterior sinus arise two arteries that supply the heart muscles. These are the right and left *coronary arteries* (Fig. 270). After distribution to the heart muscle the blood is returned by veins.

The venus return follows two main pathways: veins corresponding to the coronary arteries bring the blood into a large vessel, the *coronary sinus*, to empty into the right auricle, and numerous small veins, the *venæ thebesii*, which return the blood directly. These open chiefly into the right auricle.

Nerves of the Heart.—The heart is supplied by two sets of nerves: (1) the vagi (pneumogastrics), tenth pair of cranial nerves from the central nervous system, and (2) the accelerator nerves of the autonomic nervous system (Fig. 242). Both sets are connected with a group of nerve-cells in the medulla, the *cardiac center*. Through the center either set may be stimulated. Impulses over the vagi result in slowing of the heart; impulses over the accelerators produce an increase in the heart-rate. The vagi reach the heart by passage through the neck, lying near the main vessels. The accelerator nerves pass from the ganglia of the cord in the space between the lungs and form a plexus of nerves over the base of the heart and over the aorta. This is the *cardiac plexus* (see page 281). The sino-auricular node and the bundle of His should be considered as the intrinsic nerves of the heart (Fig. 275). Their normal functioning in setting the heart rate and conveying impulses from auricles to ventricles is essential to normal heart action.

How the Heart Works.—In contraction of the heart muscle the two auricles contract together, followed by the contraction of the two ventricles. After the contraction or *systole* of the heart there is a relaxation, or *diastole*, followed by a short period, the *rest*. During the rest period blood is flowing into the auricles and since the auricular-ventricular valves are open it flows on into the ventricles. At the beginning of auricular systole the ventricles are nearly full so that the contraction of the auricles adds little blood to the volume already in the ventricles. Hence auricular contraction is to be viewed as manifestation of the contraction wave rather than a process for filling the ventricles. The systole, diastole, and rest of the heart is called the *cardiac cycle*.

Tracing the blood in a cardiac cycle, it is found that a wave of contraction starting at the sino-auricular node traverses the walls of the auricles. This takes about one-tenth of a second. The wave so started carries on to the ventricles, which now contract. At this moment the tricuspid and mitral valves are open; the semilunars are closed. Pressure within the ventricles exerted by the contracting walls forces the closure of the tricuspid and mitral valves which are prevented by the pull of the chordæ tendineæ from opening toward the auricles. With increase in intraventricular pressure the moment arrives when the pressure in the ventricles is greater than that in the arteries. Then the semilunar valves open and the blood is forced into the aorta and pulmonary arteries. With relaxation of the ventricles and immediate fall in interventricular pressure the semilunar valves are forced to close by the backward force of the arterial pressure. During this period of ventricular systole the auricles have been in diastole, and the blood has been pouring in from the systemic and pulmonary circuits.

Normally the heart completes about 70 cycles in man and about 80 cycles in woman of adult age per minute. The rate is higher in infancy. The following gives the rate for different ages for man:

From fifth month to birth	130 to 160	beats	per	minute*
At birth	140	"	"	"
Infancy	120	"	"	"
Childhood	100	"	"	"
Youth	85	"	"	"
Adult	72	"	"	"
Old age	70	"	"	"
Extreme old age	80	"	"	"

The time relations of the cardiac cycle in the adult are as follows:

Auricular systoles, 0.1 sec. + auricular diastoles, 0.7 sec. = 0.8
Ventricular systoles, 0.3 sec. + ventricular diastoles, 0.5 sec. = 0.8
Rest period for both auricles and ventricles = 0.4 sec.

The rate of the heart-beat is determined in part by the node of Tawara. Hence, this node is called the *pace-maker*. The impetus to contract started by the node travels over the bundle of His and is the source of the wave of contraction that sweeps over the auricles to reach the ventricles. This mechanism is respon-

* This depends upon size of the fetus. Large fetuses have a slower rate. The guessing of the sex of the fetus by the slower rate is based on the fact that males are usually larger than females. Not always true!

sible, therefore, for harmony of heart action and for sequence of ventricular systole. Disturbance in this bundle causes irregularity in heart action and notably heart-block.

What Makes the Heart Contract?—The cause of the heart-beat has been a question of interest to physiologists for a long time. There is much disagreement among them. In the main, the theories proposed to explain it may be grouped under two headings: the neurogenic and the myogenic theories. The neurogenic theory maintains that the cause of the beat resides in nerve tissue in the heart connected with nerves that come to the organ. The myogenic theory holds that the cause resides in the muscle itself. Without stating the arguments here it may be said that the weight of evidence favors the latter group. The nerves are looked upon as of a regulatory nature and the heart beats because it is composed of cardiac muscle, a specialized kind of tissue having the power to contract in and of itself. This power is known as the *automaticity* of the heart.

The stimulus that starts the cardiac systoles is believed to be a chemical one, residing in the blood in the form of salts dissolved in the plasma. These salts—the chlorids of sodium, calcium, and potassium—are present in the blood and act specifically to maintain the beat. This has been shown experimentally numerous times. A solution of these salts is used for experimental perfusions of the heart. It is known as Ringer's solution and is composed as follows:

Sodium chlorid ($NaCl$)	0.9	per cent.
Calcium chlorid ($CaCl_2$)	0.026	"
Potassium chlorid (KCl)	0.03	"

Locke's solution is sometimes used. It composition follows:

Sodium chlorid ($NaCl$)	0.9	per cent.
Calcium chlorid ($CaCl_2$)	0.024	"
Potassium chlorid (KCl)	0.042	"
Sodium bicarbonate ($NaHCO_3$)	0.01–0.03	"
Dextrose ($C_6H_{12}O_6$)	0.1	"

Sounds of the Heart.—The systole and diastole of the heart give rise to characteristic sounds that are related to the contraction of the heart muscle and the closure of the heart valves. The first sound of the heart is produced by the ventricular systole, and the closure of the tricuspid and mitral valves. It is lower pitched, more intense, and longer than the second. The second comes at the beginning of ventricular diastole and is caused by

the forcible closure of the semilunar valves. These sounds may be heard by placing the ear over the apex of the heart, or listening by means of a stethoscope.

Any variation in the quality of the heart musculature or in the character of the valve action will be reflected in the heart sounds. Thus weakness of the heart muscle produces a weak first sound. Imperfect closure of valves allowing the blood to leak back into the empty chamber or defect of the valve opening impeding the flow results in abnormal sounds, called *murmurs*. The heart sound may be muffled and obscure due to an increase in the pericardial fluid, *e. g.*, in pericarditis, or to an increase in pleural fluid in certain areas, *e. g.*, pleurisy with effusion.

Valvular Lesions of the Heart.—It has been stated that imperfect closure of valves is a cause of murmurs. Such leakage is

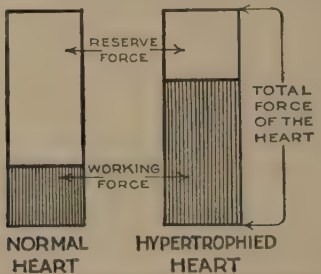

Fig. 276.—Diagram of the force of the hypertrophied and normal heart. The normal heart has more reserve force.

called *regurgitation*. This defect may exist at any one of the four valves, but occurs most frequently at the mitral. Injury to the valves usually results from an endocarditis. At times such conditions leave the valves in a certain area puckered, contracted, and ill-fitting to the orifice, over which they ostensibly act as guard. Thus the valve flaps, unable to move freely, present a hindrance to the flow of blood, resulting in a *stenosis*.

Stenosis and regurgitation are usually followed by pronounced increase in size of the musculature of the heart. This condition is called *hypertrophy*. Hypertrophy of the heart muscle may be sufficient to make up for the valvular defect. Due to greater force the blood may be forced through the narrowed orifice, or in regurgitation the greater power of the heart muscle may compensate for the leakage by sending out more forcefully and oftener

the blood that is expelled. Thus nature's way of compensation for valvular defect is through cardiac hypertrophy. This adjustment, however, uses up some of the reserve force of the heart, and hence such a heart is unable to withstand severe and prolonged exercise. The relative working force and reserve force of the heart in normal and hypertrophied conditions is indicated in Fig. 276.

When the heart is called upon to do work beyond its working-force power its reserve is called upon. If the demand exceeds its

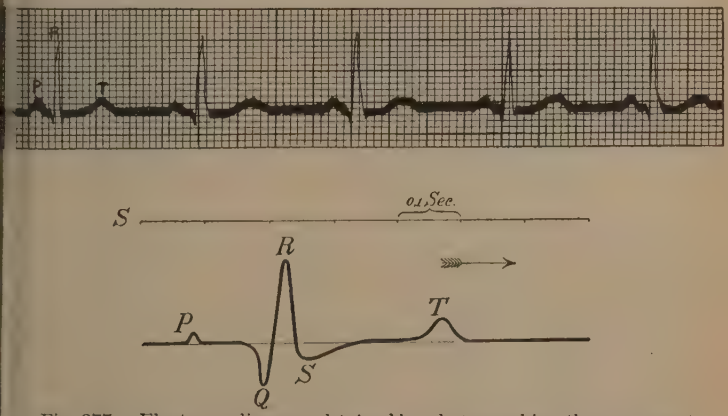

Fig. 277.—Electrocardiogram obtained by photographing the movements of the thread of a string galvanometer. The upper figure shows the photographed curve, while the lower one is a diagram constructed from the photograph to show the electrical changes occurring during a single cardiac cycle. To obtain this record the electrodes were connected with the right and left hands. Waves with the apex upward indicate that the base of the heart (or the right ventricle) is negative to the apex (or left ventricle). Waves with the apex downward have the opposite significance. Wave *P* is due to the contraction of the auricle. Waves *Q*, *R*, *S*, and *T* occur during the systole of the ventricle. The curve seems to show that the contraction in the ventricles begins first toward the apex (or in the left ventricle), since the negativity first appears toward that side (wave *Q*). (Einthoven.)

reserve power, it *dilates*, slowing down the circulation and often even stopping its function entirely. Dilatation of the heart gives a large heart with thin walls; hypertrophy gives a large organ with thick walls.

Electrocardiography.—During the cardiac cycle the heart releases electric energy which can be measured. The variations in

electric current released by the heart may be recorded by the electrocardiograph. This instrument is so sensitive that small variations in the cycle can be detected in the record of the instrument that photographs on a moving plate the magnified movements of the string on the galvanometer. These movements photographed give the electrocardiogram (Fig. 277).

PRACTICAL EXERCISES

1. With sterile gauze wash off the end of the ring or little finger wth 70 per cent. alcohol. With sterile needle prick finger and obtain a drop of blood. Make a smear on a slide by drawing another slide over the drop placed on the first slide. Stain with eosin-methylene-blue, allow to dry, and examine. Note red and white cells.

2. Dissect a beef heart with vessels attached. Examine walls of ventricles and auricles, valves, endocardium, cardiac vessels.

3. Examine children for the presence of palpable lymph-nodes. Usually some may be palpated in the posterior and middle cervical chain.

4. Secure a drop of blood as indicated in Exercise 1. Estimate the percentage of hemoglobin present by using the Tallqvist* method, or, if available, use a more accurate method.

5. Place web of foot of live frog under microscope and note the circulatory cells.

6. Pith a frog and open the thorax on the ventral surface. Note the beating heart. Distinguish systole and diastole.

7. Show slides with leukocytes ingesting bacteria. If available, show agglutination in the Widal test.

8. Take the pulse by placing the tips of the index and middle fingers of the right hand directly above the radial artery on the radial side of the wrist of a subject. Note the pulsation. What causes the pulse?

9. During adolescence the heart is frequently irregular in rate and may even show a murmur. This is due to the greater relative growth of the body, and hence relative weakness of the heart muscle for the work it has to do. Take the pulse of a child twelve or thirteen years of age and note if the pulsations are regular.

10. Anemia is a condition in which the red cells are reduced in number. Chlorosis shows reduction of hemoglobin. If the red cells are reduced in number will the total hemoglobin be reduced?

11. An infection in an extremity may be severe enough to cause extension of the inflammation to the lymph-channels, called *lymphangitis*, and to the lymph-nodes, called *lymphadenitis*. In the former, red streaks will appear on the part; in the latter, swelling, tenderness, and at times redness and heat are present. Draw with a skin pencil the location of the prominent lymph-nodes of the upper extremity.

12. Escape of blood from a vessel is hemorrhage. In such condition there are measures to assist the clotting of blood, to slow the blood current, and to maintain the circulation in vital parts in instances of sudden and profuse hemorrhage. From your knowledge of anatomy and physiology what measures would be helpful?

13. Fossier* states that the linear dimensions of the transverse diameter of the heart correspond to a line drawn from the wrist-joint (radial side) to

* Wood, F. C.: Chemical and Microscopical Diagnosis, D. Appleton & Co., New York, 1911, p. 31.

the middle joint of fourth finger. Measure your clenched fist as Fossier describes it to be done and compare with the distance of apex-beat from mid-sternal line.

QUESTIONS

1. Why is a circulatory system needed in multicellular animals?
2. What is the general plan of the circulation in man?
3. What is the origin of the lymph? Describe lymph-vessels and nodes.
4. Locate the main groupings of lymph-nodes.
5. What is the composition of the blood? Describe the red and white cells. What are their respective functions? What is immunity? How may it be acquired? What is anaphylaxis?
6. Describe the processes of inflammation.
7. What are the essential differences between child's and adult's blood?
8. Describe the heart. Where is the apex of the heart? Locate the projection of the heart valves on the chest wall.
9. Describe the cardiac cycle, the nerves of the heart, the cardiac vessels, and the heart valves.
10. Describe the heart sounds. What are murmurs? What makes the heart contract?
11. What are some commonly used blood tests? Upon what substances in the blood do their reactions depend?
12. What is an embolus? A thrombus?

REFERENCES FOR FURTHER STUDY

1. Adami, J. G.: Principles of Pathology, Lea & Febiger, Philadelphia, 1908, pp. 375–415.
2. Burton-Opitz, R.: Elementary Manual of Physiology, W. B. Saunders Co., 1928, pp. 119–130.
3. Vaughan, V. C.: Infection and Immunity, Amer. Med. Assoc., Chicago, 1915, pp. 152, 153.
4. Hiss, P. H., and Zinsser, H.: A Text-book of Bacteriology, D. Appleton & Co., New York, 1910, pp. 181–320.
5. Fossier, A. E.: Size of the Normal Heart, Jour. Amer. Med. Assoc., June, 21, 1924, pp. 2017–2020.

CHAPTER XII

THE VESSELS AND THEIR FUNCTIONS

I. Structure of Arteries and Veins.
II. Blood-supply of Arteries and Veins.
III. Nerve Supply of the Arteries.
IV. Valves of the Veins.
V. Arrangement of the Vessels.
VI. The Pulmonary Circulation:
    1. The Pulmonary Artery and Branches.
    2. The Pulmonary Capillaries.
    3. The Pulmonary Veins.
VII. The Systemic Arteries:
    1. The Aorta.
    2. The Coronary Arteries.
    3. The Innominate Artery.
    4. The Common Carotid Arteries:
        Projection of the Carotids.
        Palpation Points.
    5. The Subclavian Arteries and Branches:
        Projection of the Subclavian and Arm Vessels.
        Palpation Points.
    6. The Thoracic Aorta and Its Branches.
    7. The Abdominal Aorta and Its Branches:
        Parietal Branches.
        Visceral Branches.
    8. Terminal Divisions of the Abdominal Aorta:
        Projection of the Arteries of the Lower Extremity
        Palpation Points.
VIII. The Systemic Capillaries.
IX. The Systemic Veins:
    1. The Cardiac Veins.
    2. The Superior Vena Cava.
    3. The Inferior Vena Cava.
    4. The Portal Circuit.
X. Vasomotor Phenomena.
XI. Blood-pressure:
    Blood-pressure in Children.
XII. How Blood-pressure Is Determined.
XIII. Variations in Blood-pressure.
XIV. The Arterial Pulse:
    1. The Pulse Rate and Pulse Deficit.
    2. Auricular Fibrillation.
    3. Heart-block.
XV. Measures to Increase Blood Volume.
    1. Hypodermoclysis.
    2. Transfusion.
XVI. The Fetal Circulation.

Structure of Arteries and Veins.—The arteries of the circulatory system grow progressively smaller distally, ending ultimately in minute tubes called *capillaries* (Fig. 278). The capillaries connect the venous and arterial systems. Preceding

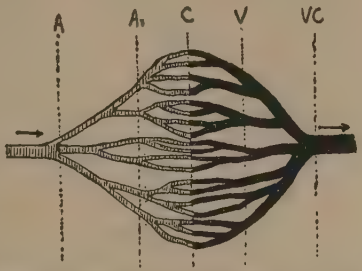

Fig. 278.—Diagram to illustrate the changes in the cross-section of the vascular system: *A*, Aorta; *Ar*, arteries; *C*, capillaries; *V*, veins; *VC*, vena cava. (Burton-Opitz.)

the capillary in the arterial tree is the *arteriole*, which has a small amount of connective tissue and a single layer of muscle cells in its wall (Fig. 279). A corresponding vessel in the veins is the *venule*. The arteries and veins, larger than the arterioles and venules, are designated by special names or are referred to generally as large or small vessels.

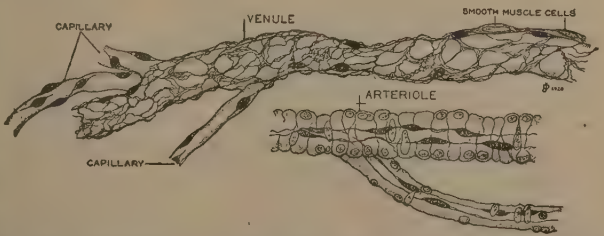

Fig. 279.—Arteriole and venule from the pia mater of the pig's brain. The arteriole has a wall of endothelium and circular smooth muscle only, there being no adventitial sheath. The smaller branch shows a thinning out of the smooth muscle as the vessel approaches the capillary and the round cell near the open end of its lumen is a lymphocyte. (D. R. Hooker.)

The capillaries have been studied more carefully in recent years and it is clearly shown now that they constrict and dilate. The contractile power is given by irregular-shaped cells, called *pericytes*, that are a part of the wall.

The structure of arteries shows three main coats: (1) an inner layer of smooth epithelial cells, called *endothelium;* (2) a middle layer of *muscle,* arranged in circular fashion,* and *elastic tissue* with some white fibrous tissue; (3) an outer layer of *white fibrous tissue,* packed closely together to form an exceedingly tough and durable coat.

The proportion of these elements of arterial structure vary with the size of the artery. In the capillaries the prominent structure is the endothelium. In the arterioles are scattered muscle cells. In the larger arteries the middle coat is prominent.

The structure of the veins shows a correspondence with the arteries. They have three coats: (1) an inner layer of endothe-

Fig. 280.—Transverse section through a small artery and vein: *A*, Artery, showing the nucleated endothelium *e*; underneath the endothelial is the wavy elastic layer; *m*, circular muscle-coat; *a*, bundles of connective-tissue fibers; *V*, vein showing similar arrangement. (Klein and Noble Smith.)

lium lines the vessels. (2) The middle layer is less well developed in the veins and shows fewer elastic tissue and muscle cells. (3) The outer layer is not so thick and is arranged more loosely. The relative proportions of corresponding arteries and veins are shown in Fig. 280.

Blood-supply of Arteries and Veins.—The middle and outer layers are supplied by vessels, called *vasa vasorum* (vessels of the vessels). These vessels penetrate as far as the inner coat.

* A few vessels show also muscle-fibers placed longitudinally.

Nerve Supply of the Arteries.—The arterioles are contractile tubes. Their muscle cells are supplied with nerve-fibers under the control of a center in the medulla, the *vasomotor* center.* The *vasomotor* nerves are of two varieties: (1) *vasoconstrictor* and (2) *vasodilator*. Both veins and arteries probably contain other nerves which carry trophic (growth) impulses to the vessels.

Valves of the Veins.—The arteries and veins have many common points in structure. Some differences have been indicated. One marked difference—the valves of the veins—remains to be described. The valves are folds of the endothelial coat arranged in pairs usually, although occasionally a single flap is found, and at times three may be present. These folds are semilunar in shape, so placed that flow toward the heart is not impeded, but flow away is prevented. Not all veins have valves. Thus, the superior vena cava, the portal veins, and others are without them. The valves are more numerous in the lower extremities, and particularly where the veins are subjected to muscular pressure (Fig. 163).

Arrangement of the Vessels.—The vessels of the circulatory system form two main groups: the pulmonary and systemic. The former provides for the pulmonary circulation, the latter for the general systemic blood-supply. The arteries leaving the heart are large vessels. They soon break up into smaller ones, and by continued division of the branches they widely distribute the blood-supply. The increase in the number of vessels from the heart outward gives an increasing cross-sectional area of the arterial tree, and thus supplies a greater blood-bed. This division follows one of three courses: (1) An artery may divide and give rise to two arteries; (2) it may give off branches and still maintain essentially its own channel; or (3) it may yield a branch which in turn serves as an axis from which three arteries arise, *e. g.*, the celiac axis. Arteries may connect with other arteries by branches that form continuous channels. Such an arrangement is called an *anastomosis*. Anastomoses are often found around joints. An important one is the cerebral circulation—the circle of Willis.

The veins are arranged in two sets usually—the *superficial* and the *deep*. While they follow in general the course of the arteries, there are numerous small venous branches without any exact

* The vasomotor and cardiac centers are well co-ordinated. Normally their functions are directed harmoniously.

designation. The smaller vessels gradually coalesce to form larger tubes, and these take up a course and position similar to the arteries.

The Pulmonary Circulation.—This is the lesser of the two systems of the body. It provides for the circulation in the lungs. The pulmonary vessels are: (1) pulmonary artery and its branches, (2) pulmonary capillaries, and (3) pulmonary veins.

The Pulmonary Artery and Branches.—The pulmonary artery conveys venous blood from the right ventricle to the lungs. About 2 inches beyond the pulmonary semilunar valves it divides into two branches, one going to the left, the other to the right (Fig. 281). Just before entering the lungs these main divisions split into two small arteries, and after entering the lungs there is marked separation into smaller branches until they merge finally into capillaries.

The *pulmonary capillaries* form a minute network of vessels. Their walls are exceedingly thin and lie in contact with the walls of the air sacs of the lungs.

The *pulmonary veins* arise out of a coalescence of the capillaries until larger vessels are formed, to unite finally in four main channels, two coming from each lung. These four veins enter the left auricle, conveying thereto oxygenated (arterial) blood to be later distributed in the systemic circulation.

The Systemic Arteries.—The pulmonary circulation is concerned chiefly in carrying venous blood to the lungs and, after oxygenation has occurred, in transporting arterial blood to the left side of the heart. The systemic circulation sends the blood received from the pulmonary circuit to all parts of the body, including the portal circuit and excepting the lungs. In performing this act the left ventricle of the heart supplies the force. The vessels of the systemic circuit are: (1) the aorta and its branches (2) the capillaries, the final subdivisions of the branches, of the aorta, and (3) the veins which arise from the capillaries and ultimately return the blood to the right side of the heart through the superior and inferior venæ cavæ or directly into the heart via the venæ thebesii.

The *aorta* comes off from the left ventricle and runs upward, backward, and to the left to form a curved tube arching over the structures entering the left lung. The vessel returns upon itself and descends along the vertebral column. It passes through an aperture of the diaphragm and enters the abdomen to divide at

the level of the fourth lumbar vertebra into the right and left common iliac arteries. The aorta is divided into the *ascending aorta*, the *arch of the aorta*, and the *descending aorta*. The latter is

Fig. 281.—Position of the heart and great vessels, viewed from in front Pieces have been cut out of the superior vena cava, aorta, and pulmonary artery; the heart has been turned downward, so that the apex looks downward (Spalteholz).

divided into *thoracic aorta* and *abdominal aorta*. The important branches of the aorta are as follows:

- **Aorta**
  - Ascending aorta—coronary arteries
  - Arch of aorta
    - Innominate
      - Right common carotid
      - Right subclavian
    - Left common carotid
    - Left subclavian
  - Descending aorta
    - Thoracic
      - Intercostal
      - Pericardial
      - Bronchial
      - Esophageal
      - Posterior mediastinal
    - Abdominal
      - Phrenic
      - Lumbar
      - Middle sacral
      - Celiac axis
      - Superior mesenteric
      - Inferior mesenteric
      - Renal
      - Suprarenal
      - Spermatic or ovarian
  - Left and right common iliac
    - Internal iliac
    - External iliac

The *coronary arteries* were described on page 317.

The *innominate artery* arises as the first division (Fig. 270) from the arch of the aorta. It passes upward, and at the level of the right sternoclavicular articulation divides into the right subclavian and right common carotid.

The Common Carotid Arteries.—The left common carotid arises as the second branch from the arch of the aorta. The right, coming from the innominate, and the left, from the aorta directly, pass upward on either side of the neck. At the upper margin of the thyroid cartilage (Adam's apple) each divides into two main divisions: the *external carotid* and the *internal carotid* (Fig. 282). The former supplies the superficial and deep structures of the face, the skull, and one branch passes inside the cranium to the dura mater. The latter artery supplies the anterior part of the brain, the eyes, and forms an anastomosis with the basilar artery, a branch of the subclavian, to form a circuit of vascular channels at the base of the brain (Fig. 283). This circuit is called the *circle of Willis.*

Projection of the Carotids: The course of the carotids is well given by a line from the front of the external auditory meatus to the base of the thyroid cartilage (Fig. 284).

Palpation Points: The pulsation of the external carotid (superficial temporal branch) may be felt immediately in front of the ear at the level of the eye. The zygomatic arch of the temporal bone serves as an excellent base over which to make

pressure for palpation. The pulsation of the common carotid may be felt at the anterior border of the sternomastoid muscle at the level of the lower margin of the thyroid cartilage.

The Subclavian Arteries and Branches.—The left comes as the third division from the arch of the aorta. The right arises from

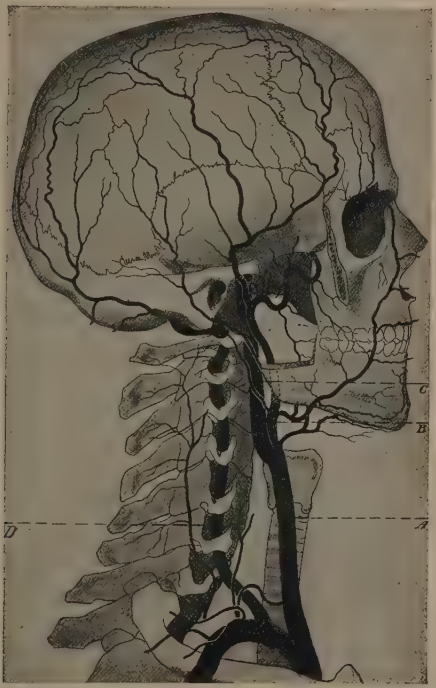

Fig. 282.—The chief arteries of the neck: *A*, Common carotid; *B*, external carotid; *C*, internal carotid; *D*, vertebral. (Deaver, modified.) (Campbell.)

the bifurcation of the innominate. These arteries are destined to supply in the main the upper extremity, chest, neck, and shoulder regions. One large branch, the *vertebral artery* (Fig. 282), after coming upward toward the base of the skull, coalesces with its fellow to form the *basilar artery* mentioned above. The subclavian gives off the *internal mammary* artery, and the *thyroid*

axis which sends important branches to the thyroid gland. Continuing its main course it passes outward toward the axilla, distributing numerous branches. According to its location this vessel receives different names. In the axilla it is called the *axillary artery;* in the arm it is known as the *brachial artery* (Fig. 285). At the bend of the elbow the brachial artery divides into the *ulnar* and *radial arteries.* These vessels course down the arm,

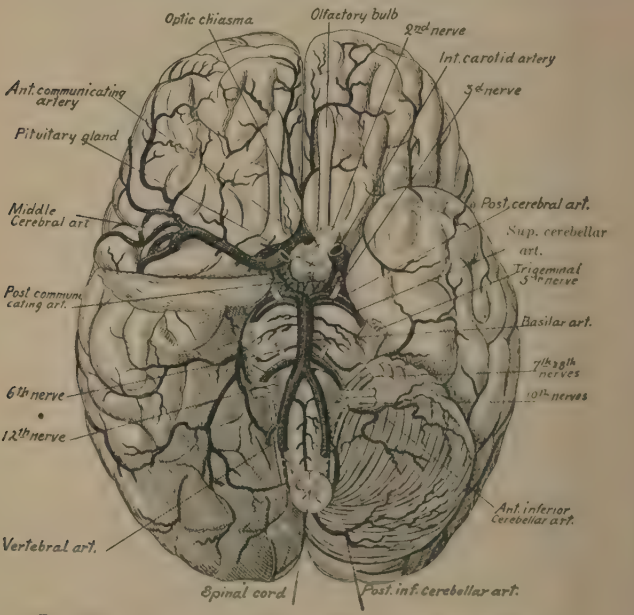

Fig. 283.—The arteries of the base of the brain (Spear).

the former lying on its mesial aspect and the latter on its lateral. Numerous branches are given off to muscles, ligaments, and bone. The *ulnar artery* ends in the palm, where it forms the *superficial palmar arch.* The *radial artery* on the thumb side terminates in the *deep palmar arch.* Both arches anastomose and supply the structures of the hand.

Projection of the Subclavian and Arm Vessels: The course of the subclavian is given by a curve from the sternoclavicular

articulation arching outward to the center of the clavicle. The convexity of the curve should be about ½ inch above the clavicle. The position of the *brachial artery* may be determined by palpation. The course of the *radial artery* may be marked by a straight line drawn from the lateral border of the tendon of the biceps to the anterior aspect of the styloid process of the radius. The *ulnar artery* holds a similar course on the mesial aspect of the forearm, with its upper third directed mesially in a marked convexity a little below the bend of the elbow.

Fig. 284.—Projection of the carotids. Cervical ganglia are also shown: *A*, Superior ganglion; *B*, middle ganglion; *C*, inferior ganglion. (Campbell.)

Palpation Points: The brachial pulsation may be easily felt at the mesial margin of the biceps muscle half-way between shoulder and elbow. The radial is readily palpable and is the artery of choice in taking the pulse-rate. It is very superficial, 1 inch to 1½ inches above the folds of the wrist. The ulnar is quite deep, the axillary and subclavian not very accessible; hence these arteries are not commonly palpated.

The Thoracic Aorta and its Branches.—The branches of the thoracic aorta are not large, but they supply important struc-

tures. The *intercostal arteries* (Fig. 286), ten on each side, pass laterally to supply the intercostal muscles, chest muscles, mammary gland, pleura, spinal cord (Fig. 287), and vertebral column. The main vessel passes between the internal and external intercostal muscles and anastomoses near the sternum with the intercostal branches of the internal mammary artery.

Several small vessels, the *pericardial arteries*, supply the pericardium.

The *bronchial arteries* are the nutrient vessels to the lungs and serve a purpose there similar to that of the coronary arteries for

Fig. 285.—Surface markings of the upper extremity, showing the relation of the arteries and bones. Anterior view: *A*, The deltoid muscle; *B*, the biceps muscle; *C*, prominence formed by the extensor muscles; *D*, prominence formed by the flexor muscles; *E*, triceps muscle. (Campbell.)

the heart. These vessels pass into the lung along with the bronchi. They supply the bronchi, the lung tissue itself, and the lymphatic nodes at the hilum of each lung.

The *esophageal arteries* are four or five branches that form a network of vessels over the esophagus.

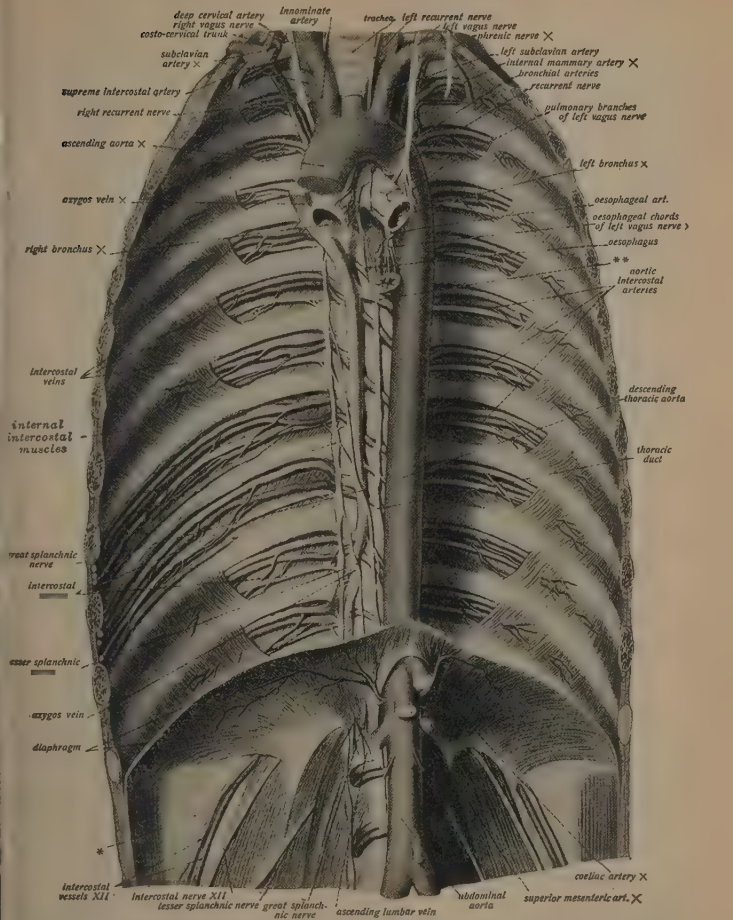

Fig. 286.—The large vascular and nervous trunks of the posterior thoracic wall as viewed from in front and somewhat from the right: *, Location of twelfth rib; **, communication between azygos and hemi-azygos veins. Sobotta and McMurrich.)

The *posterior mediastinal arteries* are numerous small vessels supplying the structures in the posterior mediastinum and the posterior part of the diaphragm muscle.

The Abdominal Aorta and its Branches.—The continuation of the aorta in the abdominal cavity is called the abdominal aorta until it divides into the common iliac arteries. The branches of the abdominal aorta are in two main groups: (1) those supplying the walls of the abdomen, known as *parietal branches*, and (2) those supplying the viscera, known as *visceral branches*.

Parietal Branches of the Abdominal Aorta: The *phrenic arteries* (Fig. 286) are two small vessels supplying the under surface of the diaphragm.

The *lumbar arteries* are usually four branches of the aorta, analogous to the intercostals. They supply the muscle and skin of the abdominal wall, the lumbar vertebræ, spinal cord, and its membranes. The middle *sacral artery*, analogous to a larger vessel seen in animals with a caudal extremity, is in man a very

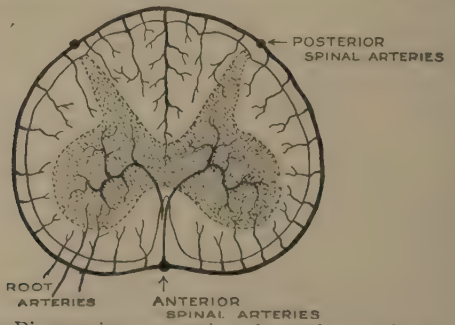

Fig. 287.—Diagram in cross-section of vascular supply to spinal cord.

small artery distributing blood to the sacrum, coccyx, and neighboring parts.

Visceral Branches of the Abdominal Aorta: The *celiac axis*, a short trunk which soon divides into three important branches, gastric, hepatic, and splenic (Fig. 288).

The *gastric artery* passes upward to supply the stomach by coursing along its lesser curvature. It sends branches to the œsophagus and liver at either end of its course.

The *hepatic artery* is the nutrient vessel of the liver and holds a position in this respect comparable to the bronchial arteries for the lungs and the coronary arteries for the heart. It gives off a pyloric branch that anastomoses with a branch of the gastric, a gastroduodenalis that splits into two vessels: one to supply the

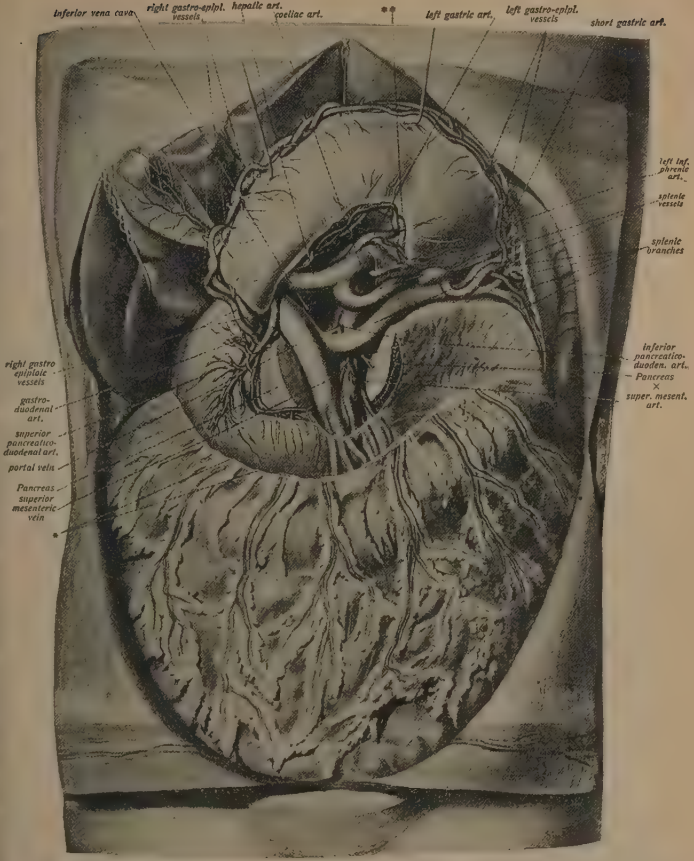

Fig. 288.—The branches of the celiac artery and the origin of the portal vein. After division of the anterior layer of the great omentum the stomach has been drawn upward, so that its posterior surface looks forward, and the pancreas has been divided along the superior mesenteric vessels: *, Cut margin at the greater curvature of the stomach; just above is the inferior portion of the duodenum; **, cut margin of the lesser omentum at the lesser curvature of the stomach. (Sobotta and McMurrich.)

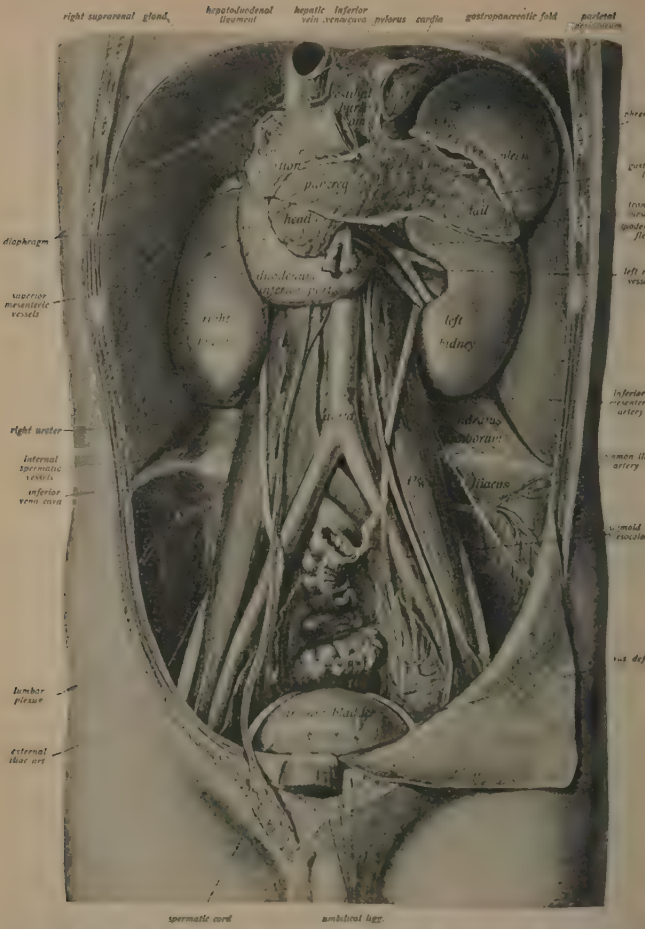

Fig. 289.—The viscera resting on the posterior abdominal wall *in situ* in an eight-year-old boy. The anterior abdominal wall, with the exception of its lower left portion, and the anterior part of the diaphragm have been removed by a frontal section. The stomach from the cardia to the pylorus has been removed so as to show the posterior wall of the abdominal cavity. The liver has been completely removed, and also the parietal peritoneum with the ascending and descending mesocolons, so that the kidneys, duodenum, the great vessels, and the muscles are exposed; only a small portion of the peritoneum has been left in the pelvic cavity. (Sobotta and McMurrich.)

duodenum and the head of the pancreas, the other by a course along the greater curvature of the stomach distributes branches to that organ and anastomoses with a similar branch from the splenic artery. The third division of the hepatic is the cystic artery to the gall-bladder.

The *splenic artery* is the largest of the three divisions of the celiac axis. It passes to the left, where its terminal branches enter the spleen. Along its course it gives off numerous small vessels to the pancreas, several small branches to the stomach, and one large vessel to the stomach. This vessel, the gastro-epiploica sinistra, analogous to the gastric branch of the gastro-duodenalis, distributes blood to the greater curvature of the stomach and anastomoses with its analogue.

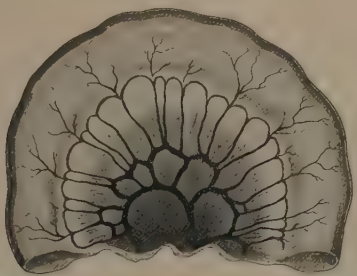

Fig. 290.—A loop of intestine at 6 feet. The distribution is in the form of arterial arches which lie between two layers of peritoneum. (Campbell, after Monks.)

The *superior mesenteric* arises from the abdominal aorta immediately below the celiac axis (Fig. 289). It supplies all of the small intestine except the first part of the duodenum. In addition, it is distributed to the cecum, ascending and transverse colon. To gain these organs it passes between two layers of peritoneum (Fig. 290).

The *inferior mesenteric artery* arises from the abdominal aorta below the superior mesenteric and about $1\frac{1}{2}$ inches above the bifurcation of the aorta. It serves the descending colon, the sigmoid flexure, and the greater part of the rectum.

The *suprarenal arteries* are two small branches arising from the sides of the aorta at the level of the superior mesenteric. They enter the suprarenal glands.

The *renal arteries* are two large vessels arising from the sides of the aorta below the superior mesenteric. In proportion to the organs they supply they are very large. The right is usually slightly longer than the left. Before entering the kidney several branches are given off, which break up into numerous divisions to ramify through the kidney substance.

The *spermatic arteries* in the male arise from the aorta a little below the renal arteries. They pass downward behind the peritoneum, and leave the abdomen through the internal abdominal ring to supply the testes.

The *ovarian arteries* are vessels in the female corresponding to the spermatic in the male. They do not pass out of the abdominal cavity, but are distributed to the ovaries in the pelvic cavity and send a branch with the uterine artery to supply the uterus. During pregnancy the ovarian artery increases greatly in size.

Terminal Divisions of the Abdominal Aorta.—The aorta terminates in the common iliac arteries. These vessels with their branches are destined to supply the pelvis, hip-joint region, and lower extremities. They are paired arteries. The *common iliac arteries* pass downward only a short distance, about 2 inches, until they form two main divisions: (1) the *internal iliac* which gives branches to the pelvic walls and viscera, muscles of the buttocks, and the external genitals. In the female, one branch, the *uterine artery*, serves the uterus. (2) The *external iliac* passes through an opening below Poupart's ligament. It is destined for the lower extremity. Similar to the subclavian, it receives different names along its course. In the thigh it is called the *femoral;* under the knee, *popliteal*, and in the leg it divides into the *anterior* and *posterior tibial arteries*. The chief distribution areas of these divisions are as follows:

From the *femoral* (Fig. 291) are branches to the wall of the abdomen, external genitals, all the structures of the thigh, and an anastomotic branch to the popliteal.

From the *popliteal* are branches to the knee-joint. It divides into the anterior tibial and posterior tibial arteries.

The *anterior tibial* supplies the front part of the leg and terminates in the *dorsalis pedis artery* lying over the instep. By its branches communication is made with branches of the posterior tibial.

The *posterior tibial* supplies the calf and posterior leg structures. It gives off one large branch, the *peroneal artery*, which distributes

blood to structures on the lateral aspect of the leg. The terminal divisions of the posterior tibial are the *internal* and *external plantar* arteries, which supply structures on the plantar surface of the foot, and after forming the *plantar arch* anastomose with communications from the dorsalis pedis artery.

Projection of the Arteries of the Lower Extremity: The course of the femoral for its upper two-thirds is indicated by a line drawn from the middle of Poupart's ligament to the adductor tubercle. The lower third is deep, lying behind the femur (Fig. 291). The course of the popliteal is indicated by a vertical line drawn half-way between the tendons at the posterior aspect of the knee. The anterior tibial follows a course marked by a line drawn from the mesial margin of the head of the fibula to a point half-way between the two malleoli. The course of the dorsalis pedis is from a point midway between the two malleoli to the first intermetatarsal space. The arteries on the posterior aspect of the leg are deep, lying below the soleus and gastrocnemius.

Fig. 291.—Relations of the surface markings to the bones of the lower extremity (anterior view): *A*, Anterior superior spine; *B*, great trochanter; *C*, mesial condyle; *D*, head of fibula; *E*, mesial malleolus; *F*, base of fifth metatarsal bone. (Campbell.)

Palpation Points: Pulsation of the femoral may be detected by pressure in the groin, half-way between the anterior superior spine of the ilium and the symphysis pubis and immediately below Poupart's ligament. The popliteal may be palpated in the popliteal space. The superficial character of this artery is

indicated by the oscillation of the foot, to be seen at times when one sits with the knees crossed. Pressure on the line of its course may readily elicit pulsation. The dorsalis pedis artery corresponds to the radial in affording an accessible position for pulse taking. It lies directly beneath the skin and may be palpated just below the annular ligament and midway between the two malleoli.

The **systemic capillaries** are minute tubes which result from the continual division of the arteries of the systemic circulation. They are found in all tissues supplied by the arterial system of vessels.

The **systemic veins** are the tubes formed by the coalescence of numerous small capillaries. They are characterized by a reversal of the process noted in the arteries. An artery divides again and again, always increasing the number of arteries, always producing smaller branches whose total area is larger than the original vessel, until the capillaries are reached. The veins, however, from the capillaries to the heart grow fewer in number, and show increasingly larger vessels with a cross-section area smaller than that of the vessels confluent with them. In the main the veins take the same course as the arteries. There are several distinguishing points of difference, however. In the first place, the veins are distributed in two sets—*superficial* and *deep* veins—and in the second place, in the interior of the skull, the venous channels, called *sinuses*, are formed by layers of the dura mater arching over grooves in the inner tables of the skull. In the third place, the blood from the digestive tract is returned via a special system of the systemic circulation, called the *portal system*.

For the purposes of description the systemic veins may be divided into four groups:

1. The *cardiac veins*, which open directly into the right auricle of the heart.

2. The *superior vena cava*, which drains the head, neck, thorax, and upper extremities.

3. The *inferior vena cava*, which drains the abdomen, pelvis, and lower extremities.

4. The *portal system*, which comprises a special circuit emptying into the inferior vena cava.

The *cardiac veins* have been mentioned before (page 317). They receive blood from the heart muscle itself, and empty into the right auricle.

The *superior vena cava* drains the head and neck through two large vessels—the *internal* and *external jugular veins* (Fig. 292). The external jugular receives blood from the area supplied mainly by the external carotid. The internal jugular drains the brain

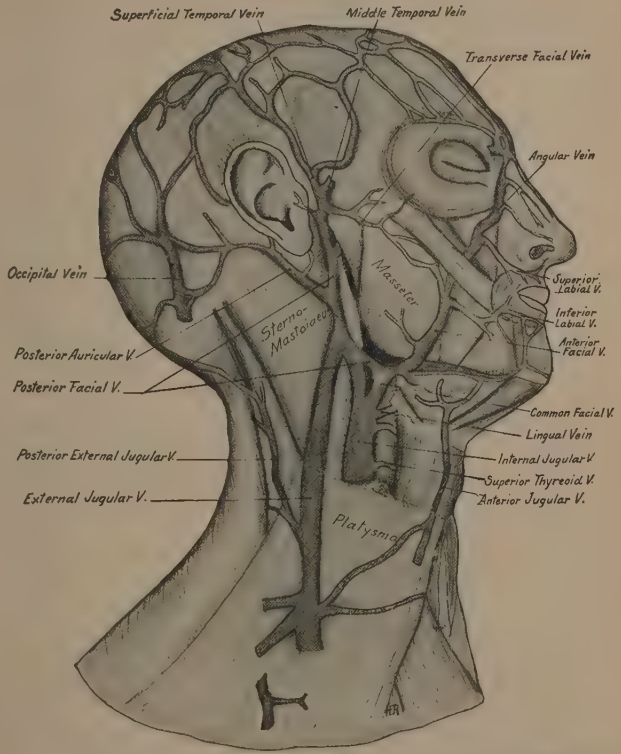

Fig. 292.—The veins of the right side of the head and neck (Radasch).

and inner structures of the skull, receiving blood from the large sinuses mentioned above. The blood from the upper extremity is conveyed toward the heart by numerous vessels (Fig. 293) which finally enter the subclavian vein. The external jugular enters the subclavian vein, and immediately after the latter unites with the

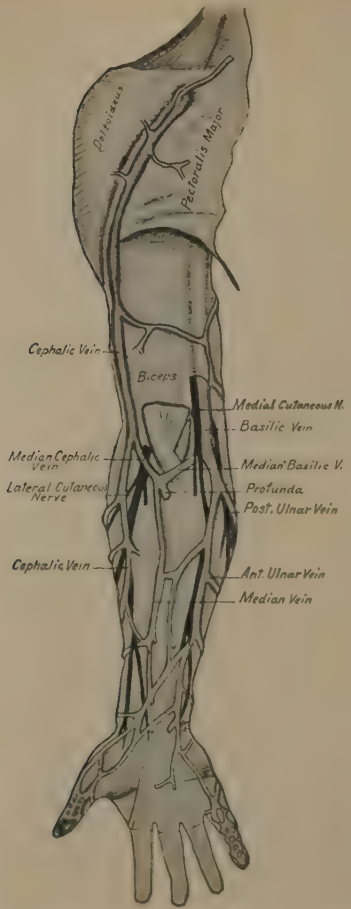

Fig. 293.—Superficial veins of the flexor aspect of the upper extremity (Radasch).

internal jugular to form the innominate vein. At the junction of the subclavian and internal jugular veins on the left side the thoracic duct opens, and on the right side the lymphatic duct.

The two innominate veins unite to form the superior cava (Fig. 294). The thorax is drained by vessels that open into the superior cava and the two innominates.

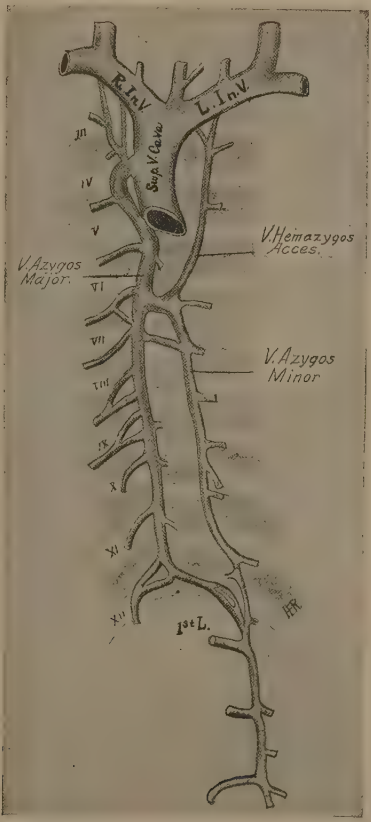

Fig. 294.—The azygos system of veins (Radasch).

The *inferior vena cava* drains the lower extremities by vessels that follow in the main the course of the arteries in these parts. Entering the pelvis the blood-supply from the lower extremities (Fig. 295) is gathered into two large vessels—the left and right

Fig. 295. The superficial veins of the lower extremity: *A*, The great saphenous vein and its tributaries; *B*, the small saphenous vein and its tributaries. (Radasch.)

common iliac veins (Fig. 296). These unite to form the inferior vena cava, which now in shape and position resembles the abdominal aorta. Parietal branches are received. The lumbar,

middle sacral, and right phrenic follow a regular course; the left phrenic opens onto the left renal vein. The visceral branches come from the kidneys (the renal veins), from the suprarenals (the suprarenal veins), from the testes (the spermatic veins), and from the ovaries (the ovarian veins). These vessels from the sex

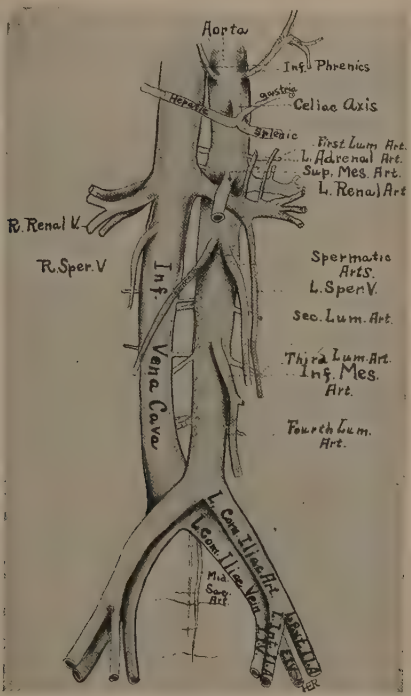

Fig. 296.—The abdominal aorta and its branches, and the inferior vena cava and its tributaries (Radasch).

glands vary somewhat from the course of the corresponding arteries. The right opens into the inferior cava, but the left empties into the left renal vein. The veins that correspond with the celiac axis, superior mesenteric, and inferior mesenteric are grouped in the *portal system*.

The *portal circuit* receives blood through four large vessels from the stomach, intestine, pancreas, and spleen. From these areas the blood is carried by the *portal vein* to the liver (Fig. 297). After passing through the tissue of this organ it is drained by the hepatic veins into the inferior vena cava. The contributing branches of the portal vein are: (1) the *gastric veins*, from the



Fig. 297.—The portal vein and its tributaries (Radasch).

stomach and duodenum; (2) the *superior mesenteric vein* draining the small intestine, cecum, ascending and transverse colon; (3) the *inferior mesenteric* vein receiving blood from the rectum, sigmoid, and descending colon; (4) the *splenic vein* from the spleen, stomach, and pancreas. Ultimately the blood from the digestive

tract reaches the inferior cava. The portal system represents a side line by which the blood is shunted through the liver before entering the main circuit.*

Vasomotor Phenomena.—Ordinarily the blood-vessels maintain a condition half-way between constriction and dilatation, similar to the state of tonus noted as a characteristic of muscle cells (page 77). Vasoconstriction is a decrease in the size of the lumen of the vessel brought about by contraction of the pericytes or muscle cells forming the vessel. Vasodilation is an increase in the diameter of the tube, probably occasioned by an inhibition of the normal impulses that give arterial tone. The effect of these vascular changes is, in the case of constriction, an increase in the resistance to the flow of blood, with reduction in the blood-supply, sufficient frequently to blanch the part. In vasodilatation the resistance to the blood in the area involved is decreased, giving a condition known as *hyperemia.*

The sevasomotor changes are directed by the vasomotor center which is in close communication with practically all the receptors of the body. The skin in particular is extremely sensitive to conditions resulting in vasomotor phenomena. Heat and cold cause marked changes. The former dilates the vessels; the latter constricts them. Frequently these changes are followed by their opposites. Dilatation favors loss of body heat, and severe "chilling" of the body may result in temporary paralysis of the vasomotor mechanism, loss of vascular tone, and further heat loss.

* The circulation of blood through the portal vessels is impeded at times due to obstructive influences in the liver through which the portal blood must go. Interference with this passageway results in back pressure in the veins concerned and gives rise to characteristic symptoms. Reference to Fig. 298 will help to explain this interesting anatomic relation. Back pressure in the gastric veins causes congestion of the stomach, and hence imperfect functioning, resulting frequently in indigestion, morning vomiting, and hematemesis. Congestion of the spleen due to back-pressure gives pallor of the patient, pain located in the left hypochondrium, and enlargement of the spleen. Back-pressure in the veins from the rectum causes enlargement of those vessels, producing hemorrhoids. Obstruction to the return from the mesenteric area results in an accumulation of fluid in the peritoneal cavity, known as ascites. The superficial epigastric vein empties toward the liver, into the inferior cava system. Obstruction in the portal circuit may reverse the current, and since it anastomoses with the superior epigastric branches that open into the internal mammary vein emptying into the superior caval system embarrassment to its normal flow may be overcome by the selection of the unaccustomed course. If this occurs, the small veins forming the anastomotic branches increase greatly in size, forming on the abdominal wall a marked varicosity of extreme tortuosity. This structure is called *caput medusæ.*

Vasomotor activity is especially useful in the body functions. It has been taught for a long time that the vasomotor center through appropriate impulses is able to dilate one area with a resulting increase in blood in that section of the body. Krogh* has shown, however, that the number of capillaries functioning in an area is not due to the pressure of the blood. There is considerable reason to believe that chemical stimulation is responsible for the shift of blood from one area to another. In fact, Krogh is of the opinion that capillary tonus is not of nervous but of chemical origin. The dilatation of the blood-vessels of the digestive tract after eating would be explained in terms of a chemical stimulus rather than a nervous one. The phenomenon, *shock*, has been explained as being due to paralysis of the vasomotor center. If Krogh's hypothesis is accepted, the great dilatation of the vessels of the abdomen is chemical rather than nervous in origin.

Blood-pressure.—The blood in the vessels is under a certain pressure that varies according to the force of the heart and the size and place of the vessels.[1] The systole of the heart forces the blood from the ventricles into the arteries. Since the blood cannot escape from the arteries as fast as it comes in from the ven-

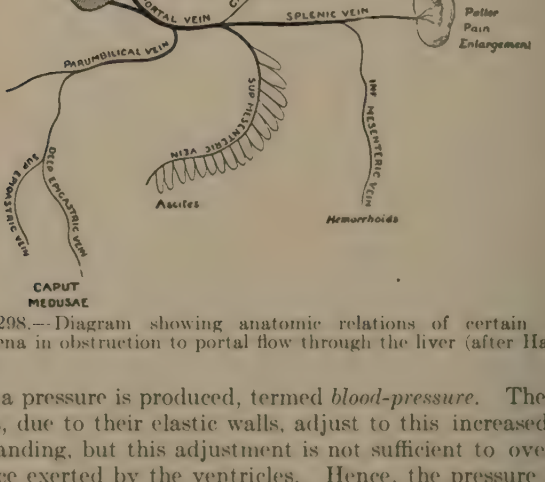

Fig. 298.—Diagram showing anatomic relations of certain clinical phenomena in obstruction to portal flow through the liver (after Hare and Taylor).

tricles, a pressure is produced, termed *blood-pressure*. The large arteries, due to their elastic walls, adjust to this increased force by expanding, but this adjustment is not sufficient to overcome the force exerted by the ventricles. Hence, the pressure of the blood is distributed throughout the vascular channels. Pro-

* Krogh, A.: Journal of Physiology, 1920, p. 399.
Krogh, A.: The Anatomy and Physiology of Capillaries. Yale University Press, New Haven, 1924.

eeding from the large arteries to the capillaries, one finds a gradual loss in pressure, however, that is most marked in the apillary area. This decrease is due to the using up of the pressure in overcoming the resistance to the flow of blood through small tubes. The capillary area (Fig. 278) is much greater and presents a larger blood bed, made up of an enormous number of channels. By the time the blood has passed through this area he pressure is almost gone, and hence in the veins it is very small ndeed. In fact, in the large veins entering the heart there exists negative pressure that is increased during inspiration due to he pull exerted by the expanding lungs on the soft, pliable walls of the large veins.

Blood-pressure in Children.—The blood-pressure in infants is ower than in children and adults. From the first day after birth, when the blood-pressure is about 60 mm. Hg., it increases gradually to about 85 mm. Hg. at the age of seven.[2] The following able is tabulated for boys and girls from seven to fifteen years:

Age.	Blood-pressure, mm. Hg.	
	Boys.	Girls.
7 years	85	83
9 "	95	90
12 "	105	100
13 "	108	105
15 "	116	110

How Blood-pressure Is Determined.—Blood-pressure is measured by calculating and measuring the amount of force necessary o equal the pressure in an artery of the extremities. The brachial artery of the arm is usually selected, although similar esults are secured from the leg. The technic consists in circling he arm with a rubber bag which can be inflated with air. Air is orced into this bag by means of a bulb, and this mechanism of bulb and bag is connected with a graduated mercury tube, egistering the air pressure in the bag. When the air in the bag is nder sufficient pressure to occlude the artery of the part, a pulse will not be detected distal to the bag. The pressure in the bag is now lowered gradually by opening an air-cock for that purpose. At the moment that the blood appears in the artery beyond the bag, the pressure in the mercurial tube is noted.

This gives the blood-pressure during the systole of the heart, or the *systolic blood-pressure.* Detection of the appearance of blood in the arteries distal to the bag may be made by palpation, but a more accurate method is the use of a stethoscope, placed at the division of the brachial artery into the ulnar and radial. This point is in the bend of the elbow. Listening with the stethoscope at this point a sound is heard at the moment the blood comes through the artery comparable to the heart sounds at the apex. This corresponds with the pulsation felt in the radial and marks systolic pressure. If pressure in the bag is further reduced, a point is reached about 40 mm. Hg. under the systolic pressure, when no sounds are heard. This point gives the *diastolic pressure.* The difference between systolic and diastolic pressures is known as the *pulse pressure.* Normally in adults these pressures are:



Fig. 299.—Sphygmomanometer of recent construction (manufactured by Green and Bauer).

Systolic blood-pressure...	120 mm. Hg.
Diastolic blood-pressure..	80 mm. Hg.
Pulse pressure.....	40 mm. Hg.

The instrument used in measuring blood-pressure is called a sphygmomanometer (Fig. 299).

Variations in Blood-pressure.—The pressure in the arterial vessels is modified by two factors: the force of the heart and the change in size of the smaller vessels, the arterioles. Influences lessening the force of cardiac systole decrease the pressure, other things being equal. Hence the pressure is less in sitting than in standing, less in lying than in standing, less in sleeping than in conscious states. Weakness of the heart muscle is reflected in a lowered pressure of blood. Influences modifying size or character of the smaller vessels change the pressure, if the heart's force remains the same. Temperature changes have marked effect upon the vessels acting through the vasomotor system. Likewise emotional states. Disease of the arteries rendering

them inelastic—*e. g.*, arteriosclerosis—increases the resistance, and hence raises the pressure. In persons with arteriosclerosis[3] sudden or unusual demands on the circulatory system may cause too great a pressure in the small vessels, with subsequent rupture and hemorrhage. If such occurs in the brain, the condition is called *apoplexy*.

The Arterial Pulse.—At each systole of the heart a volume of blood is forced suddenly into the artery of the systemic circulation. This volume of blood coming into a full tube causes an expansion of the aorta which recoils during the heart's diastole. This alternate increase in pressure with subsequent fall is communicated along the arterial system as a wave of pressure and can be felt in superficial arteries as a pulsation, called the *pulse*. By the time this wave reaches the capillaries it has disappeared due to the resistance to its flow, even as the spreading waves caused by dropping a stone in a lake gradually grow smaller and cease entirely as they proceed from the spot where the stone entered the water.

It is important not to confuse the pulse rate, which usually is identical with the heart rate, with the velocity of the pulse wave or the velocity of the blood flow. The pulse wave is faster than the blood flow in precisely the same way that a wave produced by throwing a stone into a river travels faster than the river itself. The velocity of the pulse wave is about 7 m. per second; the velocity of the blood-stream usually not over 0.5 m. per second.

The pulse is present in all arteries, but is only readily felt in the superficial ones, such as the radial at the wrist, the carotid in the neck, the temporal above the zygoma, the popliteal under the knee, and the dorsalis pedis over the instep.

The pulse is used as a ready indicator of the rate of the heart-beat. Careful palpation and experience enables one to detect not only frequency but also character of the beat. There is then noted the *weak* or *soft pulse* in instances of low blood-pressure, and the *strong* or *hard pulse* in opposite conditions.

The Pulse Rate and Pulse Deficit.—The frequency of the pulse indicates the rate of the heart. This frequency has been stated for the heart in the preceding chapter. It happens, however, that there may occur a difference between the heart rate and the pulse rate. Under certain conditions the ventricles do not contract with sufficient power to force open the semilunar valves, or if they are forced open, do not have power enough to propel a wave

that will reach the peripheral vessels. This condition is noted in "premature contraction" of the heart, or "extrasystole," as it is often called. Remembering that the cardiac contraction is a wave that begins at the sino-auricular node and passes from auricle to ventricle, this condition is easily understood. For some unaccountable reason the ventricle makes a "premature contraction" that usually falls outside the rhythm set by the auricles. This contraction is weak, and hence the pulse does not show. There occurs, therefore, a *deficit* in the heart rate as indicated by the pulse. This is known as the *pulse deficit.*

Auricular Fibrillation.—The contractions of the heart normally follow a rhythmic frequency determined by the sino-auricular node, often called the "pace maker." In auricular fibrillation "the normal impulse formation in the auricle is replaced by stimulus production at multiple auricular foci."* Instead of the rhythmic contractions of the auricle, very rapid and exceedingly small twitchings occur. The effect upon the ventricles is marked. The loss of the regular preceding auricular contractions robs the ventricle of its normal impulses over the bundle of His, and hence the ventricular systoles are haphazard and without rhythm. The rate increases also considerably. The pulse is correspondingly modified.

Heart-block.—Disturbance in the conduction pathway in the bundle of His results in delayed ventricular response, or even its complete absence at times. Thus auricular systole may not be followed by ventricular systole, and a "dropped beat" results. In complete heart-block the auricular rate may be 72 and the ventricular 30 times per minute. The pulse in heart-block is very slow.

Measures to Increase Blood Volume.—The fluid content of the blood is continually being renewed from the water ingested in food and drink. Loss in blood volume, as in hemorrhage, may be made up by drinking water, but this takes time and often the urgency is so great that additional methods are necessary.

Hypodermoclysis.—In addition to rectal irrigations and liquid diet, water is supplied at times by injection under the skin. This is called hypodermoclysis. The sites selected are ones favorable for absorption and where there is considerable loose

*Lewis, T.: Clinical Disorders of the Heart, P. B. Hoeber, New York, 1913, p. 71.

tissue, *e. g.*, beneath the breasts, in the axillary line of the chest, and in the anterior abdominal wall. Physiologic salt solution is used and as much as a pint may be given in ten or fifteen minutes.

Transfusion.—Hypodermoclysis is an injection of saline into the subcutaneous tissues; transfusion is an injection directly into a blood-vessel. The latter method will secure more rapid results. In transfusion salt solution may be used, but usually blood is employed because cellular and other blood elements are desired also. Not any blood may be used. Only the blood of a person whose serum will not cause hemolysis (disintegration of red blood-cells) of the patient's red cells may be selected for the procedure. Nor may it be permitted that the patient's serum hemolyze the cells of the donor.

By laboratory tests the hemolytic character of the blood can be determined and persons selected as donors whose blood will not show or produce hemolysis when mixed with the blood of the patient.

There are different methods of procedure in blood transfusion, but great care is always taken to prevent clotting. For this purpose a 2 per cent. solution of sodium citrate is employed at times.

The Fetal Circulation.—After fertilization of the ovum by the spermatozoön formation of the embryo begins. But its growth and development are conditioned by means of nourishment; the fertilized cell requires food to grow. In oviparous animals the yolk of the egg furnishes food during the period of gestation; in viviparous animals which develop the embryo in a special organ within the body of the mother the yolk portion of the egg (ovum) is very small. In these forms nourishment is taken direct from the mother by means of the placenta which develops from a section of the chorion (see page 49).

But even in viviparous animals such as man the early circulation in the developing egg shows its similarity to the vascular system in oviparous forms. The vitelline circulation that is characteristic of oviparous animals is to be regarded in man as an ancestral inheritance of a form employed at one time by the earliest progenitors of the vertebrate family. In birds this form is still very important; in man it has been greatly altered.

The blood from the placenta of the mother is carried to the embryo by one large vessel, the umbilical vein. This vessel

traverses the umbilical cord* to the umbilicus, at which point it turns upward in the peritoneal fold of the falciform ligament of the liver to join the portal vein. The blood is returned from the embryo to the placenta by two hypogastric arteries within the abdomen of the fetus. On emergence from the umbilicus they

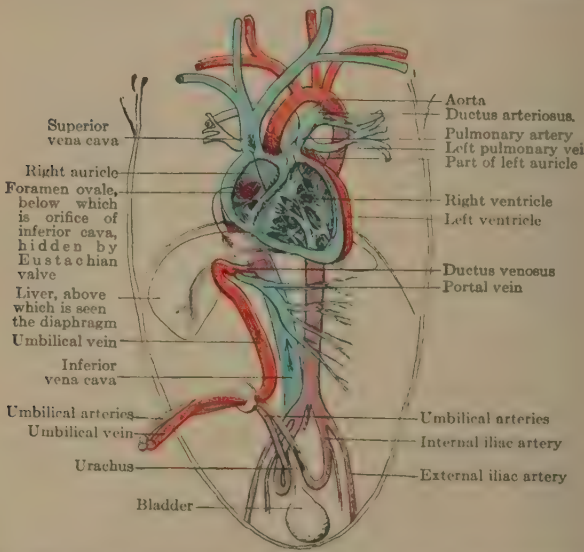

Fig. 300.—Diagram of fetal circulation before birth. The arrows indicate the course of the blood-current; the colors show the character of the blood carried by the different vessels (Heisler).

are called the umbilical arteries. Tracing the blood through the umbilical vein until it returns in the umbilical arteries will show the very interesting plan by means of which the fetus is supplied by blood until birth, when certain significant changes occur.

* The umbilical cord is formed from the belly stalk that at an early stage in development attaches the embryo to the chorion; the vitelline stalk that supported the early vitelline veins; and the amnion, one of the developmental layers. After birth the umbilical cord will show on section: (1) The amniotic sheath or covering of the cord; (2) a soft mucoid substance forming the mass of the cord known as Wharton's jelly; (3) the umbilical vessels—one vein and two arteries; and (4) remains of the allantoic duct, an outlet for the effete materials at an early stage in development of the mesonephros (see Chapter XVI).

The blood in the umbilical vein reaches the portal vein on the under surface of the liver (Fig. 300). Due to the inability of the liver to accommodate all the blood received from the portal and umbilical veins a new vessel is formed out of the early veins of the vitelline circulation. This is the *ductus venosus*, which serves

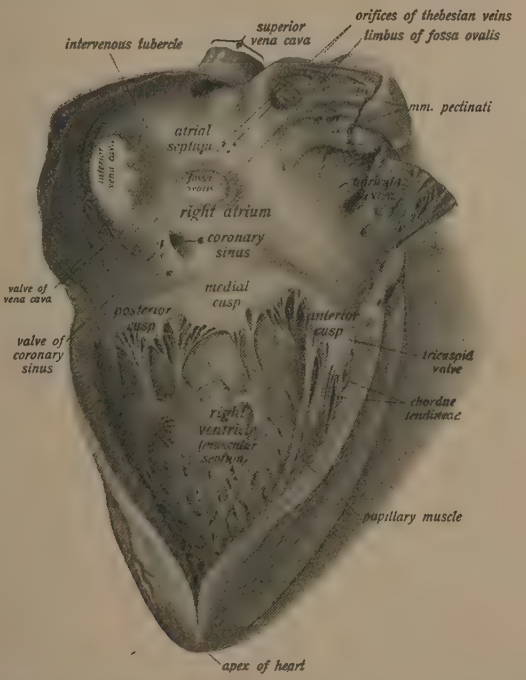

Fig. 301.—The right auricle and ventricle opened along the right border of the heart. The foramen ovale when closed is the fossa ovale (Sobotta and McMurrich).

as a short cut for the oxygenated blood from the placenta to the inferior cava. On entering the inferior cava the oxygenated blood from the placenta mixes with the blood from the lower extremities and then enters the right auricle of the heart. On entering the auricle the stream of blood is directed by the eusta-

chian valve through an opening in the interauricular septum, the *foramen ovale* (Fig. 301). This brings it into the left auricle. A very small amount of blood enters the left auricle also from the pulmonary veins, and this joins with the blood coming through the foramen ovale and passes into the left ventricle. Ventricular systole forces the blood into the aorta, from which vessel it is distributed to all parts of the body except the lungs. The blood returning to the heart through the superior cava passes by the stream coming from the inferior cava, and hence enters directly into the right ventricle. When the ventricle contracts, blood is sent into the pulmonary artery toward the lungs. *In utero*, however, the lungs are functionless and uninflated, so that large amounts of blood are not needed and cannot be used. The main portion of the pulmonary current is shunted from the lungs into the aorta by means of a vessel, the *ductus arteriosus*, which represents the distal portion of the last aortic arch on the left side.*

After birth the following changes occur:

1. The *foramen ovale* closes by means of a valve that shuts the opening from the right auricle to the left. Complete closure does not occur at once, but normally the aperture is closed by the tenth day after birth. Even when the valve flaps do not completely adhere, equal pressure during auricular systole prevents the passage of blood through the slit that sometimes persists. At times the opening remains quite large, and blood from the right auricle passes into the left without going through the lungs. This presents a serious circulatory defect and is the frequent cause of "blue baby."

2. The *ductus arteriosus* begins to grow smaller after respiration is established and is completely closed by the tenth day. Ultimately it degenerates into a cord-like structure.

3. The *hypogastric arteries* remain useful in the adult for the first part of their course, persisting as the superior vesical arteries of the bladder. Beyond the bladder after the fifth day these vessels are obliterated in their lumen, remaining only as fibrous

* In the development of the circulatory vessels in man the embryonic form shows the dorsal aorta connecting with the ventral vessels by means of six paired arches, called branchial arches. The adaptation of this structure that is made in fishes to serve the gills, and the close similarity in reptiles, birds, and mammals, is well known. The ductus arteriosus is recognized as a previous portion of the sixth arch on the left side that remains patent until birth, at which time it undergoes degenerative changes, existing in the adult as only a fibrous cord.

cords whose outline may be seen beneath the peritoneum on the anterior abdominal wall.

Fig. 302.—The complete arterial circulation of a six and a half month human fetus (female) from the level of the diaphragm downward. The superior mesenteric artery was tied off. *SM*, Superior mesenteric artery (origin); *R*, main renal arteries with their subdivisions as far as the interlobular branches; *IM*, inferior mesenteric artery; *U*, umbilical trunks. The vessels of the pelvic contents are, unfortunately, somewhat obscured, but those of the lower extremities can be identified even to the small interdigital branches. The introduction of relatively more dye into the thin injection solution causes the finer ramifications to stand out in contrast to the main trunks. (Hinman, Morison, and Lee-Brown.)

4. The *umbilical vein* from the umbilicus to the liver and the *ductus venosus* close between the second and fifth day after birth.

The former forms a cord-like structure that gives some support to the liver, being known as the round ligament; the latter remains as a fibrous band on the under surface of the liver.

5. After birth of the child the *umbilical cord* is tied and severed close to the abdominal wall. It undergoes degenerative changes and the desiccated remains of the cord come away at between the fourth and sixth day, leaving a contracted and puckered area, the umbilicus. The scar where the cord was attached remains moist and soft until the tenth or twelfth day. It is important to keep the cord dressed in an antiseptic manner, as infection through this umbilical entry is the commonest one that befalls the newborn.

The changes in the fetal circulation after birth may be tabulated as follows:

Structure.	Before birth.	After birth.
Umbilical vein:	Brings arterial blood to liver and heart.	Obliterated. Becomes the round ligament of liver.
Umbilical arteries (hypogastric):	Bring arteriovenous blood to the placenta.	Obliterated. Become vesical ligaments on anterior abdominal wall.
Ductus venosus:	Shunts arterial blood into inferior cava.	Obliterated. Becomes ligamentum venosum.
Ductus arteriosus:	Shunts arterial and some venous blood from the pulmonary artery to aorta.	Obliterated. Becomes ligamentum arteriosum.
Foramen ovale:	Connects right and left auricles.	Obliterated usually. At times open.
Lungs:	Contain no air and very little blood.	Filled with air and well supplied with blood.
Pulmonary arteries:	Bring little blood to lungs.	Bring much blood to lungs.
Aorta:	Receives blood from both ventricles.	Receives blood only from left ventricle.
Inferior vena cava:	Brings venous blood from body and arterial blood from placenta.	Brings venous blood only to right auricle.

PRACTICAL EXERCISES

1. Place a tourniquet around the forearm sufficiently tight to constrict the venous return, but not to impede the arterial flow. The superficial veins on the back of the hand or front of the forearm will stand out. Strip one of the veins distally with the finger. Note that a section of the vein will disappear, and that as the movement is continued, the vein suddenly fills. Explain.

2. Place a tourniquet on the arm and on the leg, arranging the knot to press severally upon the brachial, radial, ulnar, femoral, and popliteal arteries.

3. With a skin pencil draw the projection line marking the course of the carotids, the subclavians, the radials, the femorals, and the anterior tibials.

4. Take a deep inspiration, close the glottis, and forcefully expire. Observe the jugular veins of the neck.

5. Palpate the pulse in radial, temporal, and carotid arteries. What causes the pulsation?

6. Count the radial pulse during four consecutive fifteen-second periods in
   (*a*) Horizontal position face up.
   (*b*) Horizontal position face down.
   (*c*) Sitting position.
   (*d*) Standing position.
   (*e*) After ten deep knee bendings.
   Does it vary? Why? (Allow two minutes between each change.)

7. Count the radial pulse during four consecutive fifteen-second periods:
   (*a*) Subject holding breath during two middle periods.
   (*b*) Vigorous expiratory efforts during the two middle periods.
   (*c*) Grasp tightly with both hands showing "effort" during the two middle periods.
   Explain any variation that may occur.

8. Count the radial pulse during four consecutive fifteen-second periods. Compare rate and regularity in frequency of pulse during natural respiration and increased respiration after twenty deep knee bendings. What are respiratory irregularities?*

9. (*a*) During four consecutive fifteen-second periods count heart rate of subject, standing.
   (*b*) Record blood-pressure with sphygmomanometer.

10. (*a*) Have subject make sixty flexions and extensions of arms in sixty seconds with an 8-pound dumb-bell. During the four consecutive fifteen-second periods following count heart rate, standing.
    (*b*) Record blood-pressure of same subject.

11. (*a*) Let fresh subject make thirty deep knee bendings in sixty seconds, first counting the normal rate standing, and recording blood-pressure.
    (*b*) Record blood-pressure and make tracing.

12. (*a*) Let fresh subject make a stationary run for one minute with knees coming up high, first counting the normal rate standing.
    (*b*) Record blood-pressure and make tracing before and after exercise.

13. The efficiency of the circulation has been measured in terms of heart rate and blood-pressure variations. Practice taking the heart rate and blood-pressure until the technic is well learned. Then try the Barringer, Crampton, and Schneider tests.†

14. By palpation determine the line of the brachial artery in the arm. Mark these palpation points with a skin pencil and connect the points showing the course of the vessel.

* Lewis, Thos.: Clinical Disorders of the Heart Beat, Hoeber, New York, 1913, pp. 11–15.

† Schneider, E. C.: A Cardiovascular Rating as a Measure of Physical Fatigue and Efficiency, Jour. Amer. Med. Assoc., May 29, 1920, p. 1507. Crampton, C. W.: Proc. Soc. Exper. Biol. and Med., 1915, p. 119. Barringer, T. B., Jr.: Studies of the Heart's Functional Capacity, Archiv. Int. Med., December, 1917, p. 829.

15. Obstruction to the venous return in the portal circuit may result in an accumulation of fluid in the peritoneal cavity. This is called *ascites*. Where may such obstruction occur?

16. An inflammation of the femoral vein with thrombus formation may result from a pelvis infection. Such a condition is called *thrombophlebitis*. What circulatory disturbance would result?

17. Thomas* measured the blood-pressure in 627 children, seven to fourteen years of age, with the following results: Boys, seven to eleven years, systolic 98, girls 93; boys, eleven to fourteen, systolic 107, girls 106 mm. Hg. The amplitude of variation is 5 to 10 mm. Hg. greater in children, according to Thomas, than in adults. Explain.

QUESTIONS

1. What are the structural and functional differences between arteries and veins?
2. Describe the pulmonary circulation.
3. What are the chief divisions of the aorta?
4. Name and locate the larger arteries of the extremities, and give the arterial supply to the organs of the abdomen.
5. Describe the effects of obstruction to the venous return in the portal system.
6. What is hyperemia? Congestion? Shock?
7. What is blood-pressure? How is it determined?
8. What are simple means of lowering the blood-pressure? Of raising the blood-pressure?
9. What occurs in apoplexy? Why is there usually paralysis? Why is the extent of paralysis frequently decreased after the attack? Why does some paralysis usually persist?
10. What is a soft pulse? A hard pulse?
11. What is auricular fibrillation? Heart-block?
12. If the pulse rate is less than the heart rate, what term is applied to the condition? Explain it.
13. Describe hypodermoclysis.
14. Why is physiologic salt solution used in hypodermoclysis? Why must non-hemolytic blood be used in transfusion?

REFERENCES FOR FURTHER STUDY

1. Burton-Opitz, R.: Text-book of Physiology, W. B. Saunders Co., Philadelphia, 1920, pp. 347–444.
2. Hall, G. S.: Adolescence, D. Appleton & Co., New York, 1911, pp. 88–97.
3. Williams, J. F.: Personal Hygiene Applied, W. B. Saunders Co., Philadelphia, 1928, pp. 284, 285.

* Schweizerische medizinische Wochenschrift, Basel, September 24, 1925, p. 896.

CHAPTER XIII

THE RESPIRATORY SYSTEM

I. Development of the Respiratory System.
II. The Structure of the Nasal Passages.
III. The Nasopharynx:
Adenoids.
IV. The Pharynx.
V. The Larynx.
VI. The Trachea:
Tracheotomy.
VII. The Bronchi.
VIII. The Lungs:
1. Right Lung.
2. Left Lung.
3. Projection of the Lungs on the Chest Wall.
4. The Lungs in Infants and Children.
5. Changes in the Lungs at Birth.
IX. The Mediastinum.
X. The Mechanism of the Thorax:
Pneumothorax and Artificial Pneumothorax.
XI. How the Lungs Expand:
Vital Capacity.
XII. Different Types of Breathing:
Eupnea, Apnea, Dyspnea, Asphyxia, Cheyne-Stokes, and Asthmatic Breathing.
XIII. How the Gases of the Air Enter the Blood.
XIV. How the Gases of the Blood Enter the Tissues.
XV. Nerve Supply to the Lungs and Muscles of Respiration.

Development of the Respiratory System.—In simple one-celled animals the respiratory gases diffuse readily through the membrane of the organism. With multicellularity, however, a special apparatus appears to provide oxygen for the deeper cells and to remove the waste carbon dioxid. The simplest type of respiratory apparatus would be a respiratory membrane, to which venous blood flowed for oxygenation. Such a membrane to supply quantity needs would require a generous surface which is naturally provided for by a process of invagination (Fig. 303). This process, greatly expanded, would result in numerous units branching off from a central stem (Fig. 304) so typical of vertebrate life.

Now, developmentally, the lungs of man follow precisely this course. They arise as a pouch in the pharyngeal region just

behind the mouth cavity (Fig. 305). By a process of extension and invagination, the developed lung appears in the embryo, presenting many small sacs, each one of which structurally and

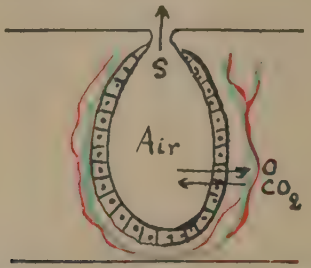

Fig. 303.—Diagram of an elementary lung: *S*, Stigma; *O*, oxygen diffusing from air of saccule into tissue fluids; CO_2, diffusing in reverse direction. (Burton-Opitz.)

functionally corresponds to the simple invagination of an elementary lung (Fig. 303). The final structures*—the lungs—reach the thorax, retaining their connection with the site of origin

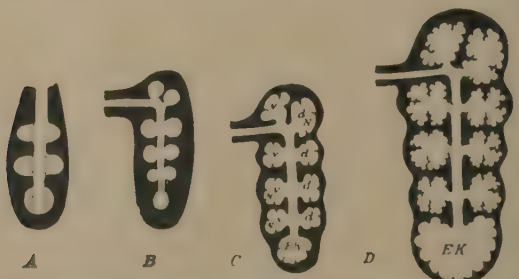

Fig. 304.—Diagrams illustrating the budding of the bronchi in the developing lung of Emys (after Fanny Moser).

through their own tubes, the bronchi, trachea, and larynx. Anterior to the larynx connecting passages serve dual functions.

* The typical respiratory apparatus in vertebrates are gills or lungs. Both forms may appear in the same individual, but usually they are not functional at the same time. In man lungs afford the respiratory apparatus, but even here the human embryo presents branchial arches and clefts comparable to the gills of fishes.

Thus, the passages leading to the pharynx serve both the respiratory and digestive systems. The mouth may serve for the transmission of air, but it is pre-eminently for food and drink purposes. The nose gives the main respiratory passageway, serving also the related function of smell.

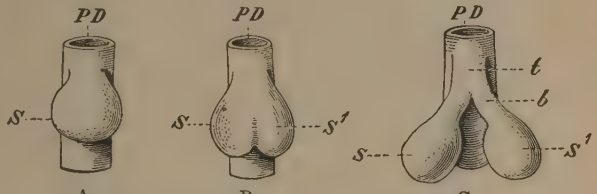

Fig. 305.—*A*, *B*, *C*, Diagrams showing the mode of development of the lungs: *b*, Bronchus; *PD*, primitive alimentary tube; *S*, S^1, the lung-sacs, which are at first unpaired; *t*, trachea. (Wiedersheim.)

The Structure of the Nasal Passages.—The nasal passages are narrow channels formed in the nose. The nose is shaped by the two nasal bones, the nasal processes of the maxilla at the root where the nose projects from the center of the face, and by cartilages (Fig. 306) at its forepart. Internally it is divided by a

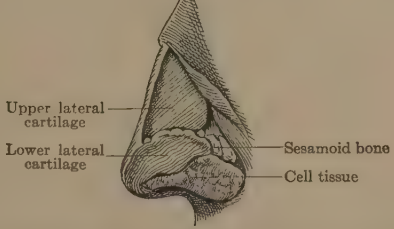

Fig. 306.—Lateral cartilages of the nose (Pyle).

septum formed by the perpendicular plate of the ethmoid, the vomer rising above the palate and maxilla, and the cartilage of the septum. This perpendicular septum divides the cavity of the nose into two passageways, the left and right *nasal fossæ*, or passages. The external openings are called the nostrils, or *anterior nares*. Internally the nasal fossæ are lined with mucous

membrane which is continuous with skin at the anterior nares and with the mucous membrane of the pharynx at the *posterior nares*. The nasal mucous membrane presents the specialized endings of the *olfactory nerve*, distributed mainly to the septum (Fig. 307). This nerve, passing upward through perforations in the horizontal plate of the ethmoid, conveys olfactory stimuli to the brain. The lateral wall of the nasal passage presents a series of three curved structures, the *superior*, *middle*, and *inferior turbinate bones*, all covered with mucous membrane. The frontal

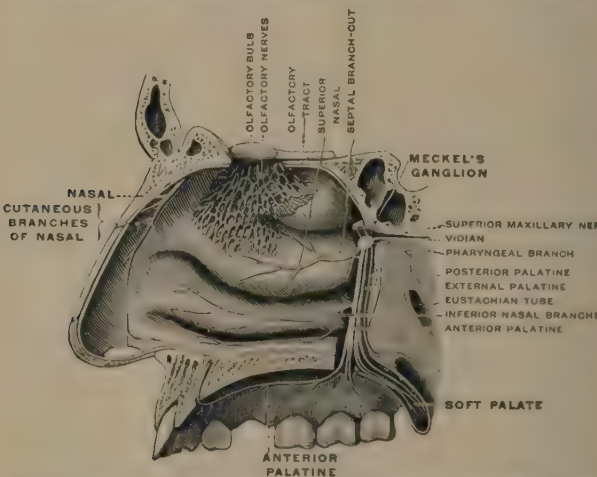

Fig. 307.—Lateral wall of nose, showing olfactory nerves and nerves of common sensation (Testut).

sinus, ethmoidal cells, maxillary sinus, and nasal duct open on the lateral walls (Fig. 308). The proximity of the sphenoidal sinus should also be noted. The nasal passages are related structurally and functionally to other important parts.*

* The relation of the nasal passages to other structures shows why a coryza may cause numerous conditions:

1. Lacrimation from extension of the infection to the tear duct, lacrimal sac, and conjunctiva.
2. Dysphagia by extension through the posterior nares to the pharynx.
3. Cough by involvement of the larynx, trachea, or bronchi in the same process.
4. Frontal headache by extension of the infection upward to the frontal sinuses.

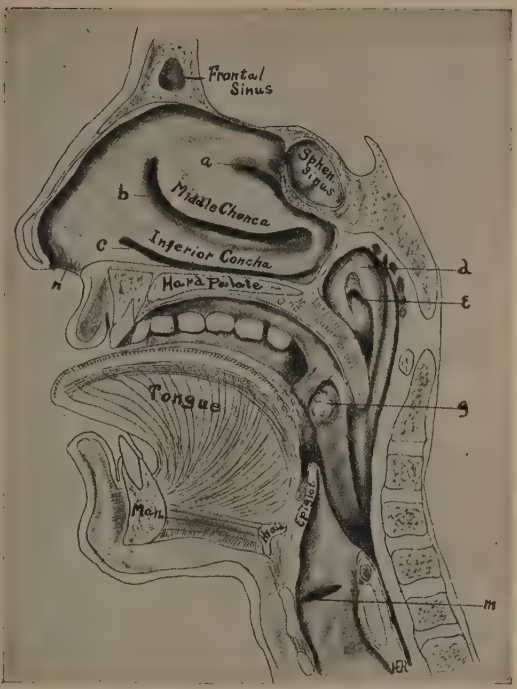

Fig. 308.—Sagittal section through head and neck: *a*, Superior meatus of the nose; *b*, middle meatus of the nose; *c*, inferior meatus of the nose; *d*, eustachian cushion; *e*, orifice of auditory tube; *g*, tonsil; *m*, vocal cord; *n*, vestibule of nose. (Radasch.)

5. Ache over the top of the head by involvement of the sphenoidal sinus.

6. Face ache by extension to the antrum of Highmore.

7. Earache and even involvement of the mastoid by extension of the process through the eustachian tube to the middle ear.

8. Intra-orbital or intracranial disturbance may result from the more virulent forms of infection by extension to the ethmoidal cells. There is a pathway into the brain cavity by way of the lymphatics passing with the olfactory nerve to the anterior fossa of the cranium.

9. Retropharyngeal abscess by drainage of certain nasal lymphatics into the retropharyngeal lymph-nodes.

10. Lymphadenitis, particularly of the submaxillary, and deep cervical nodes by drainage from the nasal mucous membrane. The continuity of the respiratory mucous membrane is the reason for not using indiscriminately the nasal douche. Infection that is localized may be extended in such procedure to other areas.

The Nasopharynx.—Posteriorly, the nasal fossæ are marked by the posterior nares. Posterior to the nares is the *nasopharynx*, that part of the vault of the pharynx above the palate. In this region are the openings of the *eustachian tubes*, situated on the lateral walls. In children *adenoids* are present in the vault of the nasopharynx, often blocking the posterior nares.

Adenoids.—The mucous membrane covering the vault of the pharynx is thick and in folds. The thickness is due to the large amount of lymphoid cells massed in the membrane. The lymphatic tissue so formed is commonly called *adenoids*, although the name "pharyngeal tonsil" is at times used. Adenoids are particularly marked in children, but tend to grow smaller with age, a characteristic of all lymphatic tissue in the body. Unfortunately, its large size in this location* may cause serious difficulty, and hence require surgical removal before the natural degenerative changes of age ensue.

The Pharynx.—This serves as a common passageway for food and air. The former passes from the mouth into the pharynx, from which place it easily enters the esophagus; the latter may come in either through the mouth or the nose, though preferably the nose, and after traversing the pharynx enters the first part of the respiratory tube leading to the lungs. This is the larynx.

The Larynx.—Externally the larynx is located by the rather prominent hard structure in the median line of the neck below the jaw (Fig. 309). This is the thyroid cartilage, especially large in men and particularly tall, thin men, in whom it projects as a distinct structure (Adam's apple). In women it is much less marked. The larynx lies within the shell-like thyroid cartilage. It is fully movable; elevation of the head raises the larynx, lowering the head causes the larynx to sink. Its movement may be easily detected in the act of swallowing.

Up until puberty the larynx of the male and female are alike, but with the onset of the changes leading up to adolescence the male larynx undergoes a pronounced modification in size. Hence, marked differences in the male and female adult larynx are noted.

The larynx is formed of nine cartilages, so placed and constructed to serve the functions of sound production. The *thyroid cartilage* is the largest and most conspicuous. The *cricoid* lies

* Note particularly the orifices of the eustachian tubes and the nasal openings into the pharynx.

below the thyroid. All the cartilages serve to give form and stability to the larynx and to afford attachment for muscles and vocal cords. The uppermost one, the *epiglottis*, projects upward from the thyroid and lies at the base of the tongue. When the larynx is to be shut off, as in swallowing movements, the whole structure is raised against the lid-like epiglottis, muscles act as sphincters, and the tongue pushes the epiglottis down, completely closing the laryngeal aperture. Failure of this adjustment may result in aspiration of food, causing the choking reflex. Strung

Fig. 309.—Vertical section of mouth, pharynx, and larynx: *A*, Vestibule; *B*, cavity of mouth proper; *C*, tongue; *D*, hard palate; *E*, soft palate; *F*, uvula; *G*, geniohyoglossus muscle; *H*, tonsil; *I*, nasopharynx; *J*, orifice of eustachian tube. (After Deaver.)

across the cavity of the larynx are two white glistening tendinous bands, the *vocal cords*. Above the vocal cords are thickened bands in the mucous membrane, called the false vocal cords.

The opening between the true vocal cords is called the *glottis*. The varying tenseness of the cords and the degree of opening of the glottis are controlled by muscles. This constitutes the mechanism by which vocal sounds are produced. Speech and singing are initiated here, and other parts of the face are called into play to modify or enhance the sound produced. Thus, the

teeth and tongue are particularly important in speech, and the teeth, tongue, and nasal fossæ in singing.

The larynx is lined by mucous membrane that is ciliated in part and is continuous with that of the pharynx and trachea. Over the vocal cords it is extremely thin. The blood-vessels are from the external carotid artery. The nerves are branches of the vagi, and numerous filaments from the autonomic system.

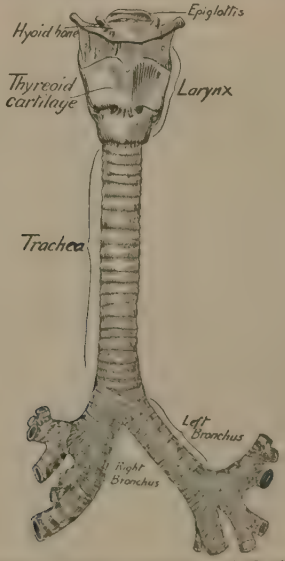

Fig. 310.—The larynx, trachea, and bronchi (Fiske, after Sobotta).

The Trachea.—This is a cartilaginous, membranous tube, cylindric in shape (Fig. 310), but flattened on its posterior surface. It is 11 cm. ($4\frac{1}{2}$ inches) long and 1.9 cm. ($\frac{3}{4}$ inch) from side to side. It extends from the larynx at the level of the sixth cervical vertebra into the thoracic cavity, where it divides at the level of the fourth dorsal into two tubes, called *bronchi*.

The trachea is constructed of connective tissue with cartilaginous rings, incomplete behind, embedded in its wall. The cartilage gives a certain rigidity to the tube and prevents its collapsing. The deficiency in the cartilaginous rings of the

posterior wall is filled in with smooth muscle tissue, so that a complete tube is formed. The trachea is lined with mucous membrane which is continuous with that of the larynx above and the bronchi below. The epithelium of this membrane is ciliated and the movements of the cilia sweep upward toward the larynx any foreign particles that have been inspired.

Among the ciliated cells are triangular-shaped cells, called goblet cells, which secrete quantities of mucus. In the wall of the trachea are tracheal glands which open by ducts. They are especially numerous on the posterior wall. They secrete mucus and serve to lubricate the inner surface of the trachea.

The trachea is supplied by blood from a branch of the subclavian artery. Its nerves are the vagi and branches from the autonomic system. Lymph vessels are abundant. These drain into lymph-nodes situated in groups along either side above and below the bifurcation of the trachea (Fig. 257).

Fig. 311.—Parts exposed in tracheotomy (Esmarch and Kowalzig).

Tracheotomy.—Obstruction of the trachea or larynx that is irremovable through the mouth may necessitate opening into the trachea in order to permit entrance and exit of air. Such procedure is called *tracheotomy.* The parts exposed in such an operation are shown in Fig. 311.

The **bronchi** are divisions of the trachea, and are known as the *left* and the *right bronchus.* On entering the lungs they break up into numerous smaller divisions, called *bronchioles,* which, in turn, end in the unit of lung structure, the *infundibulum.* The bronchi continue the same general structure found in the trachea. The cartilaginous rings are less complete and appear now as semicircular plates. As the bronchi become smaller, all the elements grow less in amount, but even in the bronchioles, ciliated epithelium, cartilaginous plates, and muscle cells are present. Finally, in the smallest tubes, cartilage is absent and the wall is then composed of only a thin layer of muscle and elastic tissue lined by mucous membrane.

The left bronchus is longer (Fig. 310) than the right and the right shows a higher branch corresponding with the upper lobe of the right lung. Foreign bodies tend to fall into the right

bronchus because its diameter is greater than that of the left. Moreover, there is a septum at the bifurcation to the left of the median line, and the right bronchus is more vertical than the left.

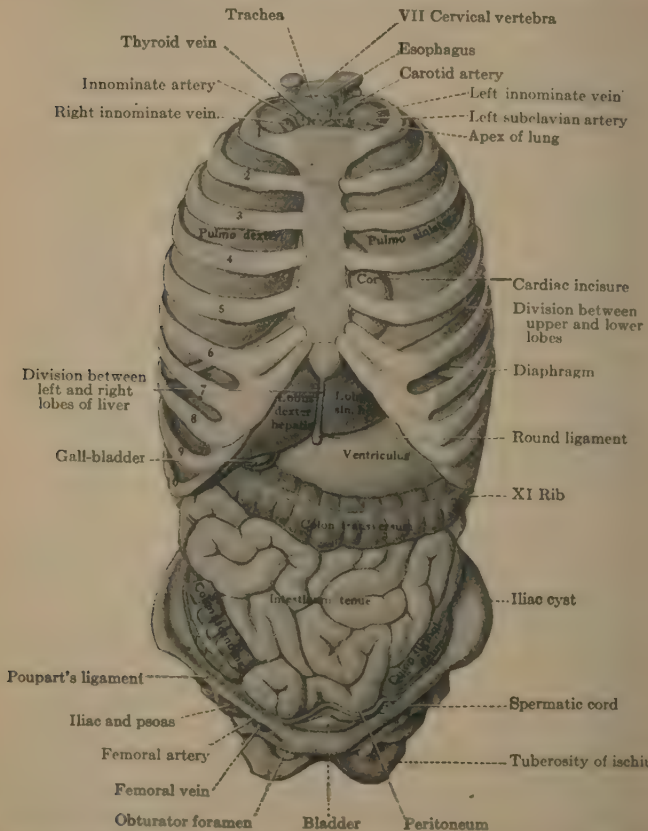

Fig. 312.—Diagram of thoracic and abdominal contents in axial skeleton (Schultze-Stewart).

The **lungs** are bilateral organs lying in the thorax (Fig. 312) and attached to the bronchi. Each lung shows a tapering cone-like upper part called the *apex*. This portion corresponds to the

area above the clavicle, as determined outside the chest cavity. The bottom of each lung is called the *base*, and the sides are described as *surfaces*. On the mesial surface of the lung is a vertical slit called the *hilum*. In the hilum lie the blood-vessels, nerves, lymphatics, lymph-nodes, and bronchi, which, taken together, are called the *root of the lung*.

Each lung is made up of elongated saccules, the *infundibula*, which are the units of structure. These units lie at the terminal divisions of the bronchioles. Massed together they form the lung in precisely the same way that muscle cells form a muscle. Each infundibulum is divided by incomplete partitions into smaller compartments, known as *alveoli* (Fig. 313).

Fig. 313.—Scheme of lung lobule after Miller: *b.r*, Respiratory bronchiole; *d. al.*, alveolar duct (terminal bronchus); *a. p.*, air-cells or alveoli. (Böhm, Davidoff, and Huber.)

The infundibulum and the pouch-like lung of lower animals are very much alike. By massing a great many infundibula in one organ and by further breaking them up into smaller compartments, alveoli, the lung of the higher mammals has increased greatly the respiratory surface. It is estimated that the infundibulum is less than 1 mm. (1/30 inch) in diameter. The alveoli are much smaller, about 120 μ in length. It is estimated that there are about 400,000,000 alveoli in each lung, giving approximately 125 square meters (1300 square feet) of respiratory surface. The surface area of a man of medium size is about 1.25 square meters. Hence the respiratory area of man is about one hundred times greater than his surface area. Since these figures are in part estimates and not exact measurements they should not be memorized. They are given to convey some idea of the tremendous size of the respiratory surface.

The wall of the alveolus is composed of flat cells, with and without nuclei. This respiratory epithelium is in direct contact with the pulmonary capillaries. It is through these structures that the gaseous interchange occurs in respiration. In the wall of

the alveolus and between the blood-vessels is considerable quantity of elastic tissue. This accounts for the elastic recoil of the lung following inspiration.

The infundibula are bound together to form lobules and the lobules to form lobes. The right lung has three lobes and the left two. The structure thus formed is covered with a layer of smooth epithelial-like cells, called *pleura*. This covering is attached to the lung, and at the root, where the bronchi and blood-vessels enter, it is reflected on to the inner wall of the chest cavity and upper surface of the diaphragm. That covering the lungs is called *visceral pleura;* the lining of the chest cavity is called *parietal pleura*.

The lungs normally are always in contact with the chest wall and diaphragm, and hence the two pleural surfaces are always in contact. The space between these two layers is only a potential space. These membranes secrete a fluid, the pleural fluid, which serves to moisten and lubricate their surfaces. Disturbances of the normal condition of this membrane result in a condition known as *pleurisy*. If there is an increase in the fluid content it is called *pleurisy with effusion*. Infection of the exudate gives rise to a condition known as *empyema*.

Right Lung.—The right lung has three lobes and is larger and heavier than the left. It is somewhat shorter, due to the higher arch of the diaphragm on that side. The three lobes are divided into upper, middle, and lower lobes. The volume in cubic centimeters is about 875 for man and 705 for woman.

Left Lung.—The left lung is smaller, narrower, and longer than the right. It has upper and lower lobes. Along the anterior aspect of the upper lobe there is a marked incisure, called the *cardiac notch*. This marks the relation of this part with the heart. The volume in cubic centimeters is about 745 for man and 585 for woman.

Projection of the Lungs on the Chest Wall.—The lungs lie in the thorax, everywhere in contact with the chest walls and diaphragm. The apex reaches up above the first rib and clavicle in front, and extends downward to the seventh rib in front and the eleventh rib behind. The pleural sacs extend beyond these lower limits. Two distinguishing characteristics mark the relation of the left and right lungs to the chest wall. The left lung shows the cardiac incisure. The right lung rides higher in the chest, due to the liver placed on the right side. These facts are made clear by examination of Fig. 312.

The Lungs in Infants and Children.—The beginnings of the lungs are well defined at the sixth month of fetal life. From birth to adolescence they show a definite growth with two marked accelerations, one from birth to three months and the other from thirteen to sixteen years. Gedgowt gives the weight of both lungs at birth as 57.3 grams (body weight 3025 grams) and at three months 100.8 grams (body weight 4570 grams). From thirteen to sixteen years the gain is 277 grams (increase from 413 to 690 grams). In the preceding years the largest yearly gain is 83 grams (from five to six years). The volume of the lungs at various ages is given by Feldman as follows:

Age.	Volume in cubic centimeters, Right.	Left.
Fetus, sixth month, male	14.5	9.9
Fetus, sixth month, female	12.0	10.0
Birth	38.4	29.3
11 months	149.0	123.0
4 years	250.0	180.0
8 years	280.0	247.0
15 years, male	354.0	405.0
15 years, female	296.0	272.0
Adult, male	873.0	744.0
Adult, female	705.0	585.3

Changes in the Lungs at Birth.—During fetal life the lungs are airless (atelectatic). A fetal lung or the lung of an infant that has not breathed will not float in water, but after respiration has occurred the lungs always contain some air that renders them lighter than water and gives them buoyant quality. Normally, a few seconds after birth, the infant breathes, due to stimulation of the respiratory center by the blood of the infant. Deprived of the gaseous interchange from the placental circulation, it must begin its own respiratory processes.

The Mediastinum.—Between the two lungs is an area filled with the heart, blood-vessels, bronchi, esophagus, lymphatics, lymph-nodes, and some fat. This is the *mediastinum.*

The Mechanism of the Thorax.—The bony thorax formed by the ribs is converted into a well-formed cavity by the diaphragm that forms the inferior wall, the intercostal muscles that fill the spaces between the ribs, and the fascia, vessels, and muscles that close its superior opening. Thus, in the living person, the thoracic cavity presents a completely walled chamber, lined by a serous membrane, the parietal pleura.

But the thorax is not a fixed cavity. Its size and shape are changeable. It can be enlarged in three diameters: vertically,

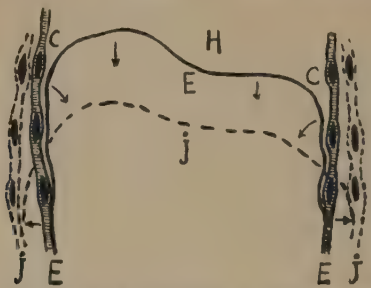

Fig. 314.—Diagram showing the position of the diaphragm and adjoining wall of the trunk on inspiration and expiration: *E*, Expiration; *J*, inspiration. The diaphragm moves downward and the walls of the trunk outward, increasing the size of the complementary space *C*. The slight depression at *H* is caused by the apical portion of the heart. (Burton-Opitz.)

anteroposteriorly, and transversely. The vertical enlargement results from contraction and descent of the diaphragm (Fig. 314); the other diameters increase with intercostal action upon ribs that are inclined downward (Fig. 315) and that are articulated in two places.

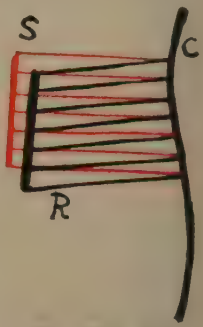

Fig. 315.—The position of the ribs on inspiration (red) and expiration (black): *S*, sternum; *C*, spinal column; *R*, ribs. (Burton-Opitz.)

Under such structural conditions enlargement of the thoracic cavity results in expansion of the lungs because of the pull that the thoracic walls make upon these elastic organs. This pull is the force of a negative pressure which increases with inspiration, but remains as a negative force even at the end of expiration, keeping the lungs in contact with the chest cavity.

Pneumothorax and Artificial Pneumothorax.—Perforation of the chest wall or rupture of bronchus or lung may allow air to rush in, disturbing the normal negative pressure and substituting the positive pressure of the atmosphere. Such condition is known as *pneumothorax*. Under such a condition the

lung will collapse due to the air in the pleural cavity. In surgical operations on the chest such unfortunate condition does not usually occur because the operator opens into an area* that has been walled off from the general interpleural space an by inflammatory reaction. Certain types of pulmonary tuberculosis are treated by artificially producing a pneumothorax either by injections of nitrogen into the pleural cavity or by surgical removal of part of the chest wall. This is known as *artificial pneumothorax*.

How the Lungs Expand.—With increase in the size of the thorax the lungs follow the chest wall, and hence they also increase their size and capacity for air. Increase in size of the lungs lowers the air pressure within, and air rushes in (inspiration) to establish a normal air pressure. The reverse occurs in expiration. Decrease in the size of the thorax causes compression of the lungs with a corresponding increase of pressure on the contained air. Hence, in expiration, the air rushes out. In this entire process the lungs are passive, acting very much as rubber bags would act in similar physical conditions.

Vital Capacity.—This flow into and out from the lungs constitutes the essential mechanical aspects of respiration. It results in a constant change or shift of the air within the lungs. The amount shifted in each respiration, the *tidal air*, is small (about 500 c.c.) compared with the total amount that the lungs contain. Thus, after a normal expiration, one can still force out about 1500 c.c. This is called the *supplementary air*. There still remains about 1500 c.c. in the lungs which cannot be expired. This is the *residual air*. By pressure on the excised lungs it is not possible to expel all of the residual air because the small bronchi collapse and trap some air in the alveoli. That which cannot be removed in this way is known as the *minimal air*. In addition to the air moved in normal respiration, one can take in about 1500 c.c. more air than normally would be inspired. This is the *complemental air*. Complemental air plus tidal air plus supplemental air constitutes what is called the *vital capacity*, normally about 3500 c.c. (Fig. 316).

Different Types of Breathing.—In the normal inspiratory and expiratory excursions of the thoracic mechanisms the action of the diaphragm is the striking fact. The lower intercostals assist in normal respiration, but they play a minor part. The descent

* Typically this operation is performed for empyema. Collapse of the lung does not occur usually in this operation.

of the diaphragm increases intra-abdominal pressure, forcing the abdominal organs downward and the abdominal wall outward. On expiration the recoil of these organs and parts return the diaphragm to its high arched position of relaxation at the end of expiration.

Interference with diaphragmatic action or need for greater lung ventilation results in increased use of the intercostal mechanism. Then the upper ribs are brought into play, giving costal respiration. The statement that costal respiration is characteristic in women and diaphragmatic in men is erroneous. Restriction of the action of the diaphragm by clothing or other interferences with diaphragmatic action is the cause of costal respiration.*

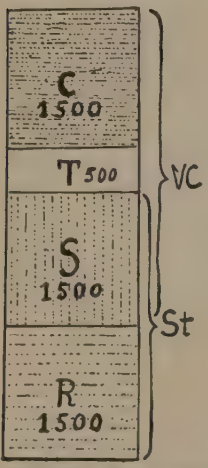

Fig. 316.—Volumes of air respired: *T*, tidal air; *C*, complemental air; *S*, supplemental air; *R*, residual air; *St*, stationary air; *VC*, vital capacity. (Burton-Opitz.)

Normally the respiratory rate in quiet states is 14 to 16 per minute. In exercise the rate is increased. Variations from the normal occur due to changes in the circulation, the respiratory center, and local conditions in the lungs.

Eupnea, Apnea, Dyspnea, Asphyxia, Cheyne-Stokes, and Asthmatic Breathing. Normally in quiet states, in which the respiratory rate is about 14 times per minute,† there is an equilibrium established in the body. That is to say, in terms of the needs of the body a normal amount of oxygen is taken in and a normal amount of carbon dioxid is given out. Under this condition the body is said to be in a state of *eupnea*.

If one forcefully respires for ninety seconds at the rate of 30 times per minute there will follow an interval in which respirations do not occur. This condition is *apnea*, due to a scarcity of

* In forced respiration both costal and diaphragmatic breathing occur.

† The rate is higher in children.

Birth	44	1 year	30
One month	35	5 years	25
12 years	20		

The ratio of respirations to heart rate is practically the same as in adults, *e. g.*, one respiration to every four heart beats.

CO_2. There are other views that seek to explain this phenomenon but even the apnea produced by breathing pure oxygen may be also caused by breathing hydrogen. This indicates that excess oxygen is not the cause and stimulation of the vagi nerves has been proposed. The generally accepted view of apnea is scarcity of CO_2. Apnea is a reminder of the balance the body seeks to keep between body needs and physiologic processes. Overventilation of the lungs with consequent diminution of CO_2 is followed by apnea until the blood has become normally charged with the products of combustion, at which time normal respirations occur to prevent an excess. Physiologically the body seeks to prevent both excess and deficiency.

Dyspnea—labored or difficult breathing, breathlessness—is a common phenomenon. It results commonly from physical exercise and is characterized by an increase in the respiratory rate and force due to the increased production of carbon dioxid. Any cause that is operative to prevent normal ventilation of the lungs and removal of the excess carbon dioxid may act as a cause of dyspnea. Therefore, it may result from heart conditions because the blood is not sent through the lungs fast enough, or from carbon dioxid poisoning because of the loss of the oxygen-carrying powers of the hemoglobin, or in laryngeal diphtheria because of the mechanical interference with the passage of oxygen into the lungs, or in pneumonia because of the exudate filling the alveoli. The causes are many and varied that produce dyspnea. Whatever the cause, the condition is a scarcity of oxygen and an increase in carbon dioxid.

Dyspnea continued may result in *asphyxiation*, which is marked by cessation of breathing and usually with a bluish discoloration of the skin, indicating the marked increase in carbon dioxid in the blood.

Under certain conditions the breathing may show a form in which intense respiratory efforts are followed by a period of no respiration. There is alternating dyspnea and apnea. This form of breathing is called *Cheyne-Stokes*. It is seen frequently just before death.

Asthmatic breathing is characterized by difficulty in expiration. The inspiration is comparatively free, but the patient has great difficulty in getting the air out of the lungs. In the spasmodic form this is due to contraction of the muscles in the walls of the smaller bronchi.

How the Gases of the Air Enter the Blood.—The pulmonary arteries entering the lungs break up into minute capillaries that course between the alveoli of the lungs. The air within the lung is separated from the blood in the capillary by the capillary wall, the alveolar wall, and a small amount of areolar tissue between the two. The gases of the air for respiratory purposes are oxygen and carbon dioxid. The proportion of these gasses in inspired and expired air are as follows:

	Nitrogen, per cent.	Oxygen, per cent.	Carbon dioxide, per cent.
Inspired air	79	20.96	0.04
Expired air	79	16.50	4.00

This analysis shows the essential fact of respiration, namely, a loss of oxygen from the inspired air and a gain of carbon dioxid by the expired air.

The passage of oxygen from the inspired air to the blood and of carbon dioxid from the blood to the lung is explained by the pressure of these gases in the respectives areas. A gas exerts pressure in accordance with its volume in an atmosphere. In inspired air the pressure of oxygen is about 1/5 (20 per cent.) of an atmosphere,* or about 152 mm. Hg. and that of carbon dioxid practically nothing.† The pressure of oxygen in the blood is about 100 mm. Hg., and that of carbon dioxid about 35 mm. Hg. Hence, in accordance with their pressures, oxygen will pass from the lungs to the blood and carbon dioxid from the blood to the lungs (Fig. 317).

How the Gases of the Blood Enter the Tissues.—Oxygen joins with the hemoglobin in the red cells to form oxyhemoglobin. Oxygen is also carried dissolved in the plasma. Under such conditions the blood leaving the lungs is well supplied with oxygen and has lost much of its carbon dioxid. Circulated to the tissues of the body by the left side of the heart the gases of the blood interchange in a manner very similar to that observed in the lungs. Oxygen leaves the systemic capillaries in response to needs in the tissues, combining with the various chemical substances of the cells. Carbon dioxid is given up by the tissues to the blood. Thus the essential step in the respiratory act is completed, namely, the supplying of the tissues with oxygen and the relieving of them of carbon dioxid.

* An atmosphere equals 760 mm. of Hg.

† Pressure of CO_2 in lungs is nearly 0, about 0.3 of a mm. Hg.

Nerve Supply to the Lungs and Muscles of Respiration.—The lungs are supplied by branches of the vagi nerves, which on their passage through the neck give off branches to the bronchi and bronchioles, in addition to small filaments to the larynx and adjoining structures. The muscles of respiration receive their innervation from the phrenic nerves for the diaphragm and from the intercostal nerves for the intercostal muscles. The activity of these muscles is controlled through the action of a group of nerve-cells in the medulla, called the *respiratory center*. This

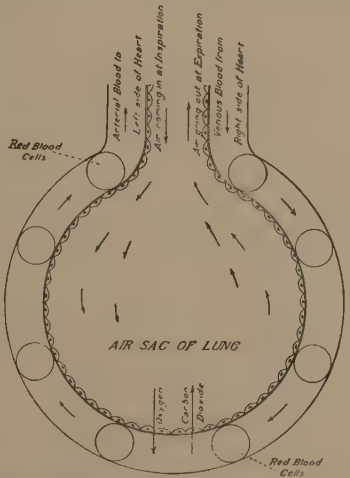
Arterial Blood to Left side of Heart
Air rich in Oxygen at Inspiration
Air going out at Expiration
Venous Blood from Right side of Heart
Red Blood Cells
AIR SAC OF LUNG
Oxygen
Carbon Dioxid
Red Blood Cells

Fig. 317.—Diagram of respiratory mechanism in lung showing how the blood comes in contact with an air-sac and thus receives oxygen and gives up carbon dioxid (modified after Adami and Nichols) (from Williams, Healthful Living, published by The Macmillan Company).

center is in connection with the vagi, receiving over the vagi afferent impulses from the lungs. It is also in connection with the nerves to the muscles of respiration, sending over them efferent impulses to the diaphragm and intercostals. The respiratory function is then under the direct control of the respiratory center, acting in an automatic way.

The automatic character of the center enables it to discharge impulses over the efferent nerves controlling the rate and depth of respirations. This automatically is influenced by two factors:

carbon dioxid of the blood, impulses over the vagi from the lungs, and influences acting reflexly on the center, *e. g.*, cold water on the skin, emotions; and drugs after absorption, *e. g.*, strychnin and atropin as stimulants, opium, ether, and chloroform as depressants.

Experimental evidence has shown that increase in the carbon dioxid content of the blood is the significant stimulus to increased activity of the center.* Conditions causing increased production or deficient elimination of carbon dioxid result in increased respiratory activity. The afferent impulses over the vagi from the bronchioles and bronchi guide the center as regards the different respiratory movements. Thus expansion of the lungs stimulates the vagi causing the center to inhibit the act, and the end of expiration incites a stimulus which provokes an inspiration. The rhythm and length of the respiration are controlled by these afferent impulses; the frequency, by the condition of the blood.

PRACTICAL EXERCISES

1. Procure a sheep's heart with lungs and vessels attached. Insert a tube in the trachea and inflate the lungs. Note their elastic character, the relation to the heart, the bronchi, and the visceral pleura.

2. Grasp the thyroid cartilage between thumb and index-finger. Drink a swallow of water and note movement of the cartilage.

3. At times foreign bodies are aspirated into the trachea and even into the bronchi. They may be removed by the forceful expiratory movements resulting from their presence. Usually, however, because of irregular surfaces they cannot be removed by natural means, and it is necessary to locate them by a radioscopic picture and remove them by a bronchoscope. Locate exactly the tubes to be radiographed, and draw with a skin pencil their projections on the chest wall.

4. In laryngeal diphtheria the inflammation may be so intense that asphyxiation would ensue but for intubation. This consists in inserting an irregular, cylindric, metal tube into the larynx, thus keeping the passageway for air open. Is there any other way to get the passageway open?

5. With a measuring tape placed horizontally around the chest below the inferior angle of the scapula (chest circumference) take the mobility of the chest at the end of the greatest possible expiration after the greatest possible inspiration. In the U. S. Army (revised 1918) the following mobility† is required in the examination of recruits:

Inches.			Inches.	
2	for persons from		63 to 67	in height
2½	"	"	68 to 71	"
3	"	"	72 to 74	"
3¼	"	"	75	"
3½	"	"	76	"
3¾	"	"	77	"
4	"	"	78	"

* What would be the proper attitude with regard to breathing exercises? See Williams, J. F., Personal Hygiene Applied, W. B. Saunders Co., Phila., 1928, pp. 230–234.

† Variation from the above standard is permitted if the applicant has firm muscles and is active.

Would you be accepted into the army if chest mobility were the only requirement?

6. Artificial respiration is used to bring oxygen to the lungs and remove carbon dioxid in conditions of asphyxiation. The Schäfer method, which is

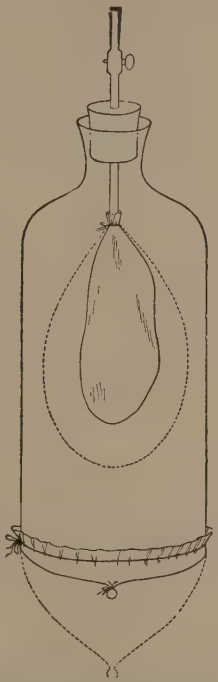

Fig. 318.—This apparatus is made by tying over the bottom of the bell jar a sheet of dental dam which has tied in the center a marble for a handle. The mouth is fitted with a cork through which passes a glass tube with stop-cock. At one end of the glass tube is tied a small rubber bag. When the tube is inserted in the jar and the cork put in place the rubber diaphragm should be pressed upward as it is in the human body (from Williams, Healthful Living, published by The Macmillan Company).

most generally accepted, is described in numerous books. Can you perform artificial respiration?

7. Assemble an artificial thorax and lungs as indicated in Fig. 318. Locate upon the respiration scheme what corresponds to the following structures:

(*a*) Trachea, (*b*) glottis, (*c*) thoracic cavity, (*d*) lungs, (*e*) intrapleural space, (*f*) diaphragm.

8. Using the apparatus* in Exercise 7—
   (1) Produce inspiration by lowering diaphragm.
      (*a*) What has happened to the intrathoracic pressure?
      (*b*) What has happened to the intrapulmonic pressure?
      (*c*) How does the pressure in each case compare with atmospheric pressure in inspiration and expiration?
      (*d*) Compare intrathoracic and intrapulmonic pressures.
   (2) Produce expiration by raising the diaphragm.
      Answer (*a*), (*b*), (*c*), (*d*) for this procedure.
   (3) Produce a condition of pneumothorax. Lower the diaphragm as in inspiration. What effect does this have upon the expansion of the lungs? Account for it. What change is there in intrathoracic pressure as a result of lowering the diaphragm.
   (4) Close the glottis after expiration. Lower the diaphragm as in inspiration.
      (*a*) What effect does this have upon the expansion of the lungs?
      (*b*) What change is produced in intrathoracic pressure? Account for it.
   (5) Close the glottis after deep inspiration. Raise the diaphragm as in expiration. What effect occurs upon the lungs and intrathoracic pressure? What effect upon the intra-abdominal pressure occurs in the living subject with the same condition? What relation has this to hernia?
9. Forced breathing and apnea vera.
   (*a*) Subject seated breathes as deeply as possible about 24 times a minute. Attention should be fixed on drawing deep inspirations. The process is continued for thirty seconds (nine respirations). Count normal rate before and after experiment, and notice normal depth of respirations.
   (*b*) Repeat experiment for a one-minute period. Count rate for succeeding minute period. Record any subjective sensations.
   (*c*) Repeat experiment for a two-minute period and record observations.

10. Forced breathing without excessive elimination of carbon dioxid. Repeat 9 (*a*) while holding a paper bag over nose and mouth of subject. Record results and explain the condition in the light of Experiment 9.

11. Respiration in a mammal. Anesthetize a mammal and maintain the anesthesia throughout the experiment until animal has been killed. Make a longitudinal ventral incision and expose ribs and abdominal muscles. Open the abdominal cavity and study action of the diaphragm. Describe the mechanism of respiration. Observe the lungs through the pleura of an intercostal space after removing muscles. Remove lungs and drop in water. Do they float? Why? Place lungs in the respiration model in place of rubber bag and study action of lungs.

12. The mucous membrane of the nasal fossæ is sometimes known as the Schneiderian membrane. On the septal side near the anterior nares it is not unusual to find an ulcer in children. What habit do children often have that would likely cause an ulcer?

QUESTIONS

1. What are the conditions that may result from cold in the nose? Explain the anatomic relationships.

* Apparatus for physiologic experiments may be secured from the Harvard Apparatus Co., Back Bay Station, Cambridge, Mass.

2. What are adenoids? What are the signs of the presence of obstructive adenoids?

3. What are the anatomic details that enable the lungs to serve as ventilating organs for the blood?

4. What is empyema?

5. What periods in the life of the child show the greatest lung growth?

6. What is the mediastinum? Name the parts exposed in Figure 282.

7. What are the anatomic and physiologic grounds upon which you would form an opinion concerning the use of breathing exercises?

8. What is Cheyne-Stokes' breathing? When does it occur?

9. What is the cause of dyspnea? Give illustrations.

10. What is the nerve control of respiration? How does this nervous mechanism respond to the chemical factors in respiration?

11. What element of structure in the bronchi would account for bronchial asthma?

12. At what rate would artificial respiration be performed?

REFERENCES FOR FURTHER STUDY

1. Burton-Opitz, R.: Text-book of Physiology, W. B. Saunders Co., Phila., 1920, pp. 482–286.

Burton-Opitz, R.: A Comparative Study of the Different Methods of Artificial Respiration, Amer. Jour. Phys., vol. lxi, No. 3, August, 1922, pp. 562–573.

CHAPTER XIV

THE DIGESTIVE SYSTEM

I. Development of the Digestive Tract.
II. The Abdominal Cavity.
III. The Abdomen.
IV. General Characteristics of the Digestive System:
    Functions of the Three Coats of the Canal.
V. The Mouth:
    1. Parts of the Mouth.
    2. The Tongue:
        Vessels and Nerves of the Tongue.
    3. Tonsils:
        Vessels and Nerves of the Tonsils.
    4. Salivary Glands:
        Structure of the Salivary Glands.
        The Secretion of Saliva.
    5. Teeth.
    6. What Happens to Food in the Mouth.
VI. Pharynx.
VII. Esophagus.
VIII. Stomach:
    1. Coats of the Stomach.
    2. Vessels and Nerves of the Stomach.
    3. Gastric Digestion.
    4. The Production of Gastric Juice.
    5. Movements of the Stomach.
IX. Small Intestine:
    1. The Duodenum.
    2. The Jejunum and Ileum.
    3. Structure of the Small Intestine:
        Valvulæ Conniventes.
        Villi.
        Glands of Lieberkühn.
        Brünner's Glands.
        Lymph-nodules.
    4. Vessels and Nerves of the Small Intestine.
    5. Meckel's Diverticulum.
X. Large Intestine:
    1. The Cecum.
    2. The Vermiform Appendix.
    3. The Colon.
    4. The Rectum.
    5. Coats of the Large Intestine.
    6. Vessels and Nerves of the Large Intestine.
    7. Dilatation of the Colon.
    8. Enemata and Colon Irrigations.

Development of the Digestive Tract. The digestive system comprises that part of the body concerned with the preparation

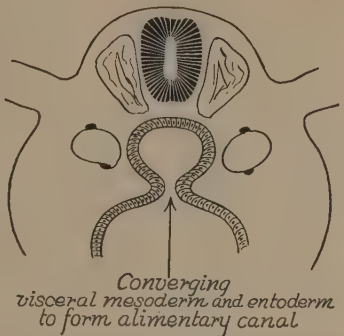

Fig. 319.—Diagram of cross-section of early embryo to show formation of alimentary canal.

of food for assimilation. Simply stated, it consists of a tube within the head and trunk with two external openings. Only

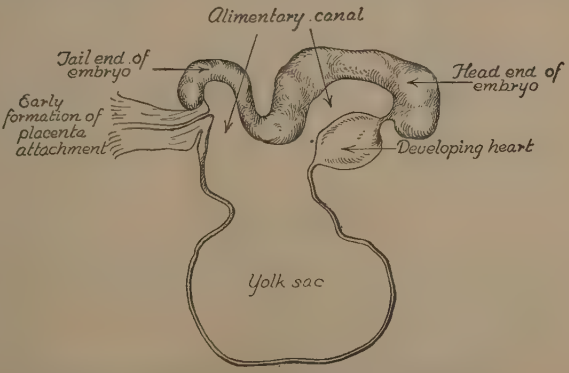

Fig. 320.—Diagram of early stage of alimentary canal.

after the food is digested, has left the tube, and its constituents are taken into the blood- and lymph-channels has it actually entered the body.

This tube is not of one size throughout. There are dilatations, recesses, and enlargements. It presents characteristic qualities in special areas. It shows in man evidences of its relation to lower animals.[1] The head end of the tube is connected by a small narrow passageway with the main part which lies in the *abdomen*, the trunk cavity below the diaphragm.

The tube is formed by the converging layers of visceral mesoderm and entoderm from the sides (Fig. 319). At first the

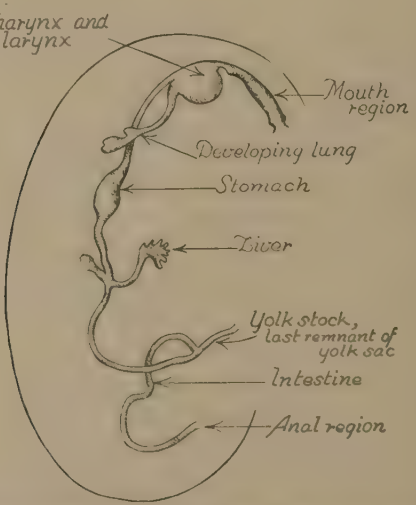

Fig. 321.—Diagram of early stage of alimentary canal, showing also budding lung, pancreas and liver.

alimentary canal is a part of the yolk sac as it is in the chick but soon constrictions occur from head and tail ends and from side to side (Fig. 320). A twenty-eight day embryo will show a canal as diagrammed in Figure 321.

In the early weeks of embryonic life the intestine is a nearly straight tube in the body cavity. By the sixth week the main divisions of the tube are well established (Fig. 322): the upper end dilates at one part, which is known as the stomach, with the lesser curvature forward and the greater curvature backward. At

this stage the blood-supply and the nerves reach the organs between the two layers of *mesentery* that runs from the abdominal wall to the tube. With the growth in length of the intestine a series of remarkable changes occur, the explanation of which

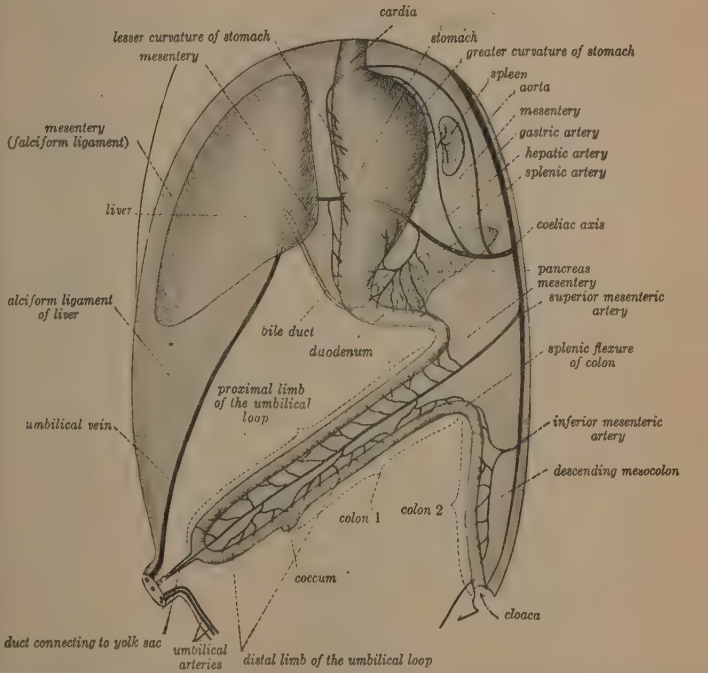

Fig. 322.—First stage of the development of the intestinal canal and the peritoneum, seen from the side (diagrammatic). From colon 1 the ascending and transverse colon will be formed, and from colon 2 the descending and sigmoid colons and the rectum (Sobotta and McMurrich).

enables one to understand the rather complex picture presented by the anatomy of the fully developed individual. The upper end of the stomach undergoes a swing to the left and the lower end to the right. This brings the lesser curvature that was forward to a horizontal and superior plane and the greater curva-

ture tends to approach the position seen in the adult. The greatly lengthened intestine loops upon itself, forming a sharp angulation at the ultimate site of the splenic flexure. The

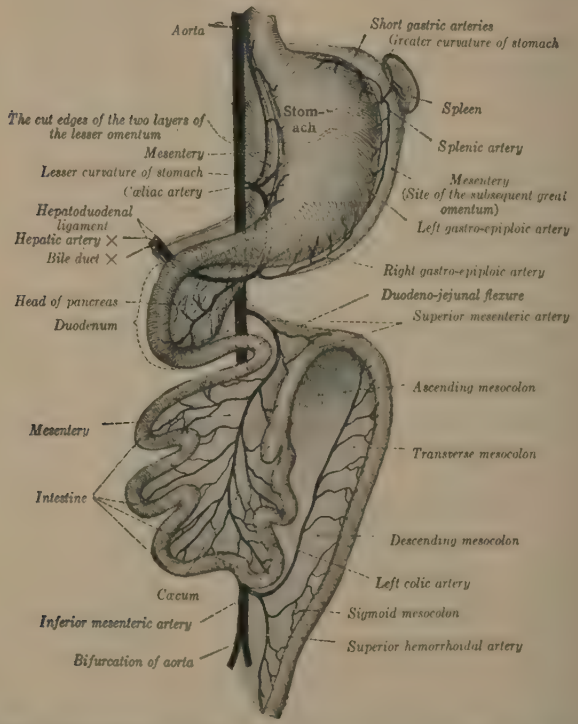

Fig. 323.—Second stage of the development of the intestinal canal and peritoneum, seen from in front (diagrammatic). The liver has been removed and the two layers of the ventral mesogastrium (lesser omentum) have been cut. The vessels are represented in black and the peritoneum in the grayish tint (Sobotta and McMurrich).

elongated tube keeps moving downward, and from the splenic flexure there is a rotation during growth, so that the cecum that was lying on the left side and toward the rear comes to take a

position in front and on the right side (Figs. 323, 324). This rotation of the intestinal tube carries with it the mesentery, so that in the adult the mesentery is seen to run as the parts of a fan from the periphery (the intestine) to the handle (the posterior wall of the abdominal cavity). A view of these organs before

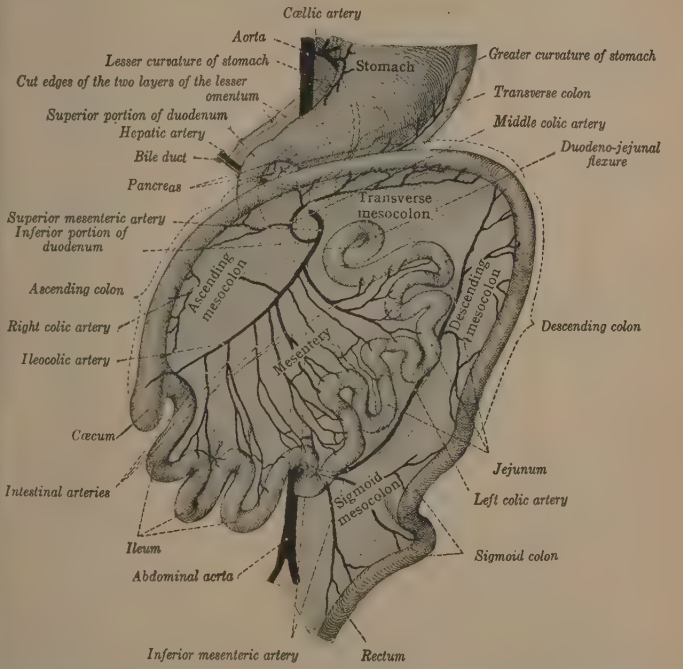

Fig. 324.—Third stage of the development of the intestinal canal and peritoneum, seen from in front (diagrammatic). The mode of preparation is the same as in Fig. 323 (Sobotta and McMurrich).

rotation is given in Fig. 322. This diagram presents a side view and represents the peritoneum as reflected on to all the organs of the cavity. The liver is shown with that part of the peritoneum that is known in the adult as the falciform ligament. The portion between the liver and lesser curvature of the stomach becomes the

gastrohepatic omentum (see page 412). The portion from the greater curvature of the stomach to the abdominal wall becomes, on rotation of the stomach and development of the mesentery, the great omentum.

Throughout this rotation of the intestine the blood-vessels, lymphatics, and nerves traversing their course between the two original layers of mesentery continue to keep their contact with the abdominal organs. Thus, in this remarkable movement of

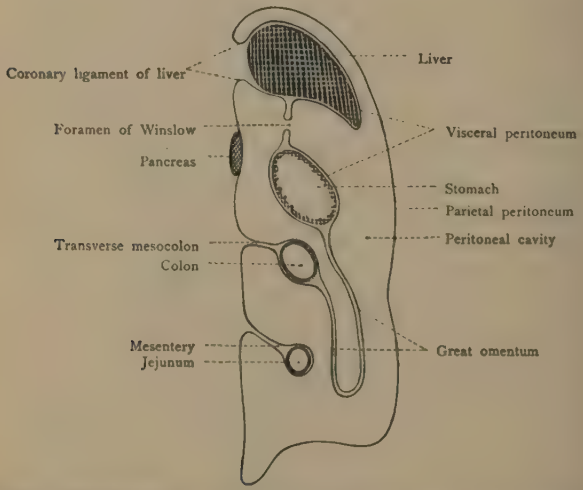

Fig. 325. Diagram of the peritoneum. Parietal and visceral peritoneum are indicated and the reflections show the mesentery. Anterior aspect is to the right (from Schultze-Stewart).

parts, two significant facts stand out: (1) The mesentery continues to afford support to the abdominal viscera, and (2) the vascular and nerve supply follow the viscera, retain their connections with them, and keep their original position between the two layers of the mesentery.

The **abdominal cavity** is bounded above by the diaphragm; below it is continuous with the pelvic cavity. Within this cavity is a lining membrane, called *peritoneum*. The peritoneum is a

serous membrane and secretes a lubricant, the *peritoneal fluid.* Constituting the lining of the abdominal wall, this membrane is reflected on to the organs contained within the abdomen and forms also their *mesentery* (Fig. 325). Similar to the arrangement in the chest cavity the covering of the organs is called the *visceral peritoneum;* that of the wall, the *parietal peritoneum.*

The **abdomen** is of oval form. This varies with sex and age. In the adult male it is barrel shaped, with marked flattening

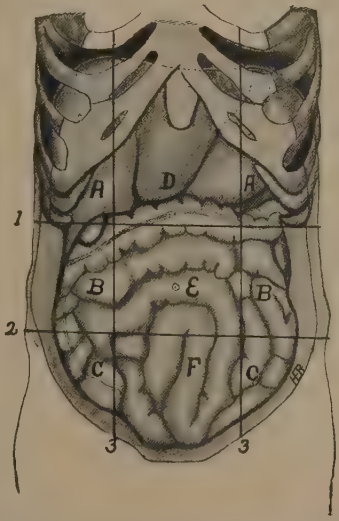

Fig. 326.—Lines and regions of the abdomen and the viscera in each: 1, Subcostal line; 2, intertubercular line; 3, 3, midinguinal lines; *A*, *A*, right and left hypochondriac regions; *B*, *B*, right and left lumbar regions; *C*, *C*, right and left inguinal regions; *D*, epigastric region; *E*, umbilical region; *F*, hypogastric region. (Radasch.)

from before backward. In the adult female with broad pelvis the form is conical with the apex above. In children it is conical with apex below, and on cross-section almost circular and without the flattening found in the adult. The abdomen is divided into nine regions by four artificial lines represented on the anterior wall (Fig. 326). Two are vertical lines bisecting Poupart's liga-

ments, and two are horizontal lines: the upper at the level of the ninth costal cartilages and the lower at the level of the crests of the ilia. The nine regions and the organs contained in artificial compartments made by projecting these lines horizontally and vertically backward are given in Fig. 326.

General Characteristics of the Digestive System.—The digestive system consists of the digestive tube, called the *alimentary canal*, which performs certain mechanical operations and secretes digestive ferments,* and *appendages* or accessory organs, related in proximity or function to the tube itself. Thus, there are described with this canal, the teeth and tonsils. The former is concerned in the first stage of the digestive act, the latter has nothing to do with digestion, but is an important part of the structure of

* Ferments or enzymes are widely distributed in nature. Those concerned with digestion have been extensively studied. The following table by Burton-Opitz† shows the ferments involved in different places:

	Ferment.	Place of action.	Character of action.
Amylolytic and inverting (hydrolyzes starch)	Ptyalin	Saliva	Starch—maltose
	Amylopsin	Pancreatic juice	Starch—maltose
	Glycogenase	Liver and muscles	Glycogen—dextrose
	Invertase	Small intestine	Cane-sugar—dextrose
	Maltase	Saliva and small intestine	Maltose—dextrose
	Lactase	Small intestine	Lactose—dextrose and galactose
	Lactic acid ferment	Intestine	Glucose—lactic acid
Lipolytic (fat splitting)	Steapsin	Pancreatic juice	Neutral fats—fatty acids and glycerin
	Lipase	Liver, etc.	Neutral fats—fatty acids and glycerin
Proteolytic (protein splitting)	Pepsin	Gastric juice	Proteins—peptones and amino-acids
	Trypsin	Pancreatic juice	Proteins—peptones and amino-acids
	Erepsin	Small intestine	Proteoses—amino-acids
	Nuclease	Pancreas, spleen, thymus, etc.	Nucleic acid—purin bases
	Enterokinase	Small intestine	Trypsinogen—trypsin
Deaminizing	Guanese	Thymus, adrenals, pancreas	Guanin—xanthin
	Adenase	Spleen, pancreas, liver	Adenin—hypoxanthin
	Deaminase	Tissues	Amino-acids—oxyacids
	Arginase	Liver and spleen	Arginin—urea

† The deaminizing ferments split off NH_2 from the amino-acids. This is converted to ammonia, NH_3, and then to urea, $NH_2—CO—NH_2$. The urea is formed in the liver and is excreted by the kidneys.

the mouth. The alimentary canal may be divided into the following parts:

- Mouth
  - Tongue
  - Tonsils
  - Salivary glands
  - Teeth
- Pharynx
- Esophagus
- Stomach
- Small intestine
  - Duodenum—appendages
    - Liver
    - Pancreas
  - Jejunum
  - Ileum
- Large intestine
  - Cecum
  - Appendix
  - Colon
    - Ascending
    - Transverse
    - Descending
  - Rectum

While there are marked differences in the parts of the canal, with special modification in the mouth, the tube, in the main, conforms to the following plan of structure:

From the lumen of the canal outward there are *mucous, submucous, muscular,* and *serous* coats. In the stomach and intestines this plan is followed throughout. In the esophagus the serous coat is replaced with a fibrous one, in the pharynx the submucous coat is absent and a fibrous coat replaces the serous. In the mouth the plan is not followed at all, although, of course, the mucous membrane is intact and continuous with the mucous covering of the contiguous parts of the canal.

Functions of the Four Coats of the Canal.—The *mucosa* is composed of cells arranged in membrane form. Some cells of the mucosa secrete digestive juices, as in the stomach and intestine, or mucus, as in the mouth, small and large intestine.

The *submucosa* is composed of loose areolar tissue and affords an adjustable basis for movements and changes in size of the other coats. It carries a rich supply of vessels and nerves.

The *muscular* coat is usually arranged in two layers: A circular one surrounding the tube, and a longitudinal one placed in alignment with its axis. This muscular coat provides for the movements of the tube. The circular layer constricts the tube and the longitudinal one shortens it. The combined action of constriction and shortening gives rise to a movement known as the *peristaltic wave* which results in forcing the food ahead of the constricted segment.

The *serous* coat is very smooth and secretes a lymph-like fluid, the *peritoneal fluid*, which serves to lubricate the parts, preventing friction and irritation.

The Mouth.—In the development of the head end of the embryo the formation of the mouth constitutes a most interesting

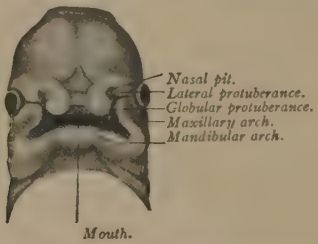

Fig. 327.—Development of the face of the human embryo of about twenty-nine days (His).

phase. In Fig. 327 the primitive oral fossa, the forerunner of the mouth, is seen. Two processes, the maxillary and mandibular, grow forward on either side to form the upper and lower jaws of the face, and a third, the frontal, grows downward to form the nose. Perfect fusion of these parts produces normal contours of

Fig. 328.—Harelip (Campbell).

the face. Imperfect development results in such deformities as *harelip* (Fig. 328) and *cleft palate* (Fig. 329). The former occurs when the frontal and maxillary processes fail to unite. If this non-union occurs only on one side, single harelip occurs; if they fail to unite on both sides, double harelip is the result. Cleft

palate is caused by imperfect union of horizontal plates that grow inward from the maxillary processes. This defect is always in the median line. It may involve only the part of the roof of the mouth, or it may extend the entire distance of the palate and connect with a single or double harelip.

Parts of the Mouth.—The opening to the mouth is marked by two musculomembranous structures, the lips. Beyond the lips is the vestibulum or buccal cavity which is bounded externally by the cheeks and lips and internally by the teeth and jaws. On opening the jaws there is seen the mouth proper. Above is the palate* composed of bone in front (the hard palate) and

Fig. 329.—Cleft palate (Campbell).

muscle behind (the soft palate). The *soft palate* is attached to the bone of the hard palate and extends backward to end in the uvula behind. It is prolonged downward in the two *pillars of the fauces*. Between these pillars on either side lie the tonsils. Posteriorly the soft palate is prolonged into a tip-like structure, the *uvula*. The *hard palate* is marked in front by transverse ridges analogous to the palatal rugæ of most mammals. They are prominent in childhood, but gradually decrease in size with age, and even disappear. Both hard and soft palates receive blood from a branch of the external carotid artery. Veins follow the arterial course. The lymphatics drain into nodes in the neck. In the floor of the mouth is the tongue.

* In congenital idiots this is particularly narrow and high.

The Tongue.—When the jaws are closed the tongue fills the mouth cavity. Opened, the tongue is seen to lie in the hollow between the two ridges of the lower jaw. It is composed of muscle tissue which forms the body of the organ. The muscles arranged in four pairs are responsible for its varied movements. The tongue is covered with mucous membrane. On its under surface near the tip is a band of tissue passing to the floor of the mouth and posterior surface of the lower jaw. This is the *frenum*. Contraction of the frenum, or "tied tongue" is not as common as often supposed. The mucous membrane of the upper part of the tongue is studded with elevations, called *papillæ*. There are three varieties:

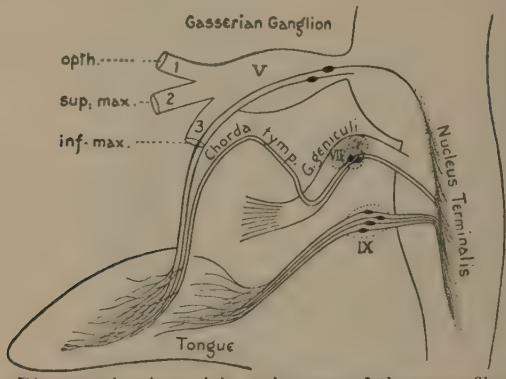

Fig. 330.—Diagram showing origin and course of the nerve-fibers of taste (Burton-Opitz).

1. Fungiform papillæ appear as red points chiefly near the edges of the tongue. They contain endings of the seventh (facial) and fifth (trigeminal) cranial nerves in the anterior two-thirds of the tongue, serving the function of taste in the former and general sense in the latter nerve.

2. Filiform papillæ are more numerous and are widely distributed except at the very back of the tongue.

3. Circumvallate papillæ are located only at the root of the tongue. They contain *taste* buds in which are endings of the ninth cranial nerves (glossopharyngeal) (Fig. 330).

Vessels and Nerves of the Tongue: The tongue receives its blood-supply from the lingual artery, a small subdivision of the

external carotid. The lymphatics drain into nodes in the neck. The sensory nerve supply is from (1) the fifth (trigeminal), (2) the seventh (facial), and (3) the ninth (glossopharyngeal) cranial nerves. The motor nerve is the twelfth cranial nerve (hypoglossal).

Tonsils.—The name "tonsil" is commonly* applied to the small masses of lymphoid tissue situated between the two pillars of the fauces. They consist of groups of lymph-nodes bound together with fibrous tissue and covered by a distinct fibrous capsule over which is mucous membrane. The surface of the tonsil is marked by twelve to fifteen openings, each leading into a small recess or pocket, called a *crypt.* The crypts communicate by irregular channels throughout the substance of the gland.

Vessels and Nerves of the Tonsils: The blood-supply of the tonsils comes from numerous branches of subdivisions of the external carotid. Its nerve supply is from the glossopharyngeal and the autonomic via the superior cervical ganglion. The internal carotid lies behind and to the lateral side of the tonsil, nearly 1 inch (2 to 2.5 cm.) distant from it.

Salivary Glands.—The secretion (saliva) of the mouth comes from glands in the mucous membrane that secrete mucus, and from three pairs of glandular organs, the parotid, submaxillary, and sublingual salivary glands. The *parotid* is situated in front of and below the ear. Its duct runs horizontally forward to open into the buccal cavity opposite the second molar tooth of the upper jaw. The *submaxillary* gland lies under the jaw, halfway between the angle and point of the lower jaw. The *sublingual* lies in a position anterior to it. Their ducts open into the floor of the mouth. Infection in these glands (usually the parotid) causes mumps (acute epidemic parotitis).

Structure of the Salivary Glands: The salivary glands show an arrangement of epithelial cells around the terminal ends of the gland ducts. This arrangement of the secretory cells is called an acinus (Fig. 49). In submaxillary and sublingual glands there are both serous and mucous tubules. The mucous tubules constitute the main bulk of the gland. The serous cells are arranged in crescent formation forming the demilunes, hence the name *demilune cell* often applied to these crescents.

* Anatomists at times use the term *lingual tonsil* to note the aggregation of lymphoid tissue on the root of the tongue seen in some children; *pharyngeal tonsil* for the lymphoid growth commonly called *adenoid;* and *palatine tonsil* to describe the organs situated between the palatine pillars.

The Secretion of Saliva: The nerve supply to the salivary glands is derived from the fifth and seventh cranial nerves and branches of the autonomic system. The stimulation of the glands by these two different innervations results in different types of salivary secretion. The central nervous system nerves stimulated by the sight or smell of food give rise to a saliva that is of watery consistency, readily produced, and in copious

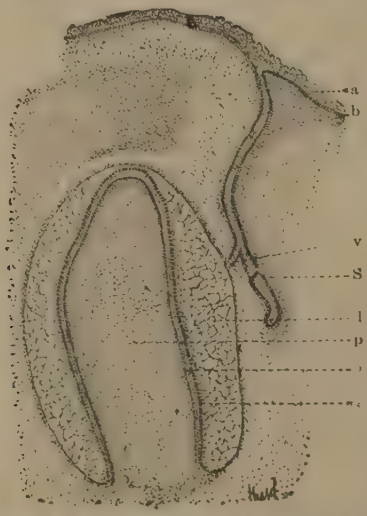

Fig. 331.—A stage in the development of a tooth in a sheep embryo (from the lower jaw): *a*, Epithelium of the oral cavity; *b*, its basal layer; *d*, enamel pulp; *p*, dentinal papilla; *s*, enamel-forming elements (enamel cells); *o*, odontoblasts; *S*, enamel germ of the permanent tooth; *r*, part of the enamel ledge of a temporary tooth. (Böhm, Davidoff, and Huber.)

amount. The autonomic fibers stimulated by the presence of food in the mouth produce a thick secretion, maintained for a long time, and in smaller amount. The former is at times spoken of as the psychic flow of saliva; the latter is dependent upon the sensory endings in the taste corpuscles in tongue, cheeks, and fauces.

Teeth.—While serving an important part in the feeding and digestive process, the teeth do not belong developmentally with the organs of the alimentary canal.[2] The latter arise from the

entoderm. The teeth arise from the ectoderm and come from the same layer that produces the hair and nails. The ectoderm in the invertebrates has one layer of cells that secretes hard calcareous material that forms a protective covering for these animals. This power to form calcareous material resides in a layer of cells which in the vertebrates is known as the malpighian layer.

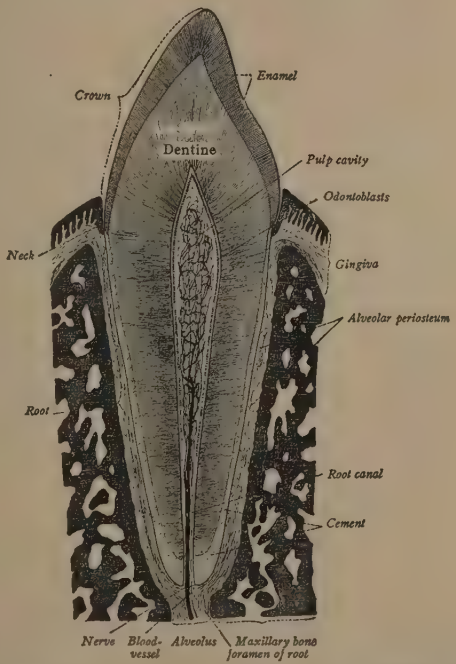

Fig. 332.—Longitudinal section of a tooth in its alveolus (diagrammatic) (Sobotta and McMurrich).

The teeth arise from the malpighian layer of the epidermis. In man the process begins at about the seventh week of embryonic life. First a furrow forms in the alveolar process of the jaw bones. This furrow extends in the soft tissues of the jaw, dividing into two parts, one to give rise to the temporary teeth, the other the germ of the permanent teeth (Fig. 331). The cells of

the malpighian layer grow into cap-like projections, the future enamel of the teeth. Into these push prolongations of the derma to form the dentin. The completely formed tooth (Fig. 332) shows enamel, dentin, and pulp cavity in which are the blood-vessels, nerves, and lymphatics. The tooth lies in a pocket (the alveolus) in the jaw bone. The alveolus is lined with periosteum which is continuous with the periosteum of the jaw. A cement substance covers the tooth below the enamel, serving to hold it securely in place.

There are two sets of teeth: the first, temporary, or deciduous; and the second, permanent (Figs. 333, 334). The temporary set are 20 in number, 10 in each jaw. After their eruption, which begins at the sixth to seventh month usually and ends at two and one-half years, the germs of the permanent teeth develop and mature, so that at the proper time their growth pushes outward the temporary teeth The permanent set are 32 in number. The following tables show the time of eruption and number of the temporary set:

ERUPTION OF TEMPORARY TEETH

Dental periods.	Groups of teeth.	Number.
1. Six to eight months	Middle lower incisors	2
2. Eight to ten months	Upper incisors	4
3. Twelve to fourteen months	Lateral lower incisors. First bicuspids	2 4
4. Eighteen to twenty months	Cuspids	4
5. Twenty-eight to thirty-two months	Second molars.	4

It will be noted that the teeth erupt in periods followed by stages of rest, except that there is no interval between the first and second periods. Also that there is a range of from two to four months within which they may erupt.* At times the range is even greater and the appearance of the permanent teeth may be quite variable in different individuals. Rotch gives the following:

* Delayed dentition is usually due to rickets. Early dentition is not very common and rarely (1 in 10,000 to 15,000 births) a child is born with the lower central incisors erupted. Recent experiments indicate (Howe, P. R.: Jour. Dental Research, March, 1921; Jour. Nat. Dental Assoc., January, 1922) that the quality of tooth structure and the development of caries are related to the diet of the mother before birth of the child and the diet of the child during the first years of life.

TABLE OF ERUPTION OF PERMANENT TEETH

Years.	Groups.	Years.	Groups.
6	Four first molars	10	Four second bicuspids
7	Four middle incisors	11	Four cuspids
8	Four lateral incisors	12	Four second molars
9	Four first bicuspids	17–25	Four third molars (wisdom teeth)

Incisors are eight in number, four in each jaw. They are specially adapted for cutting both by position and shape.

Cuspids (sometimes called canines) are four in number, two in each jaw. They are pointed and serve in man as a cutting tooth. In lower mammals they are longer and sharper and are used to tear food.

Bicuspids (in the temporary set, sometimes called molars or premolars) are eight in number, four in each jaw, in the permanent set only. They have broad crowns and serve to cut and grind food.

Molars are eight in number in the temporary, and twelve in the permanent set. They have broad surfaces, specially adapted for grinding.

The variability of eruption is shown by Livy, who observed several thousand children:

TIME OF ERUPTION OF PERMANENT TEETH
(Boys and Girls)

Groups.	Ages, years.																Total observations.	
	9		10		11		12		13		14		15		16			
	B.	G.	B.	G.	B.	G.	B.	G.	B.	G.	B.	G.	B.	G.	B.	G.	B.	G.
Lateral incisors	2	..	42	74	9	8	4	4	1	...	1	...	..	..	..	..	39	36
First bicuspids	1	..	76	56	12	13	1	2	...	1	...	1	..	..	..	..	90	73
Second bicuspids	..	..	59	51	36	16	5	2	...	2	1	...	..	..	..	..	101	71
Canines	..	..	18	30	28	34	25	12	8	5	...	...		1	..	..	79	82
Second molars	..	..	5	5	42	44	67	80	275	288	184	249	78	66	12	14	663	746

What Happens to Food in the Mouth.—Food undergoes two changes in the mouth: a mechanical one, *mastication*, in which the coarse food masses are ground into smaller pieces, and a chemical one, *digestion*, in which the digestive juices of the saliva cause certain changes in the chemical compounds of the food.

Fig. 333.

During mastication the food is moved about in the mouth by the action of the tongue and cheeks. After a variable period the food mass, mixed with saliva, is forced through the arch of the pillars in a small rounded mass, called the *bolus*. At this point the pharyngeal muscles begin a contraction that forcefully propels the bolus to the stomach.

Digestion of the food in the mouth is not very important because the food does not stay there long enough for digestive action. The saliva, an alkaline juice, contains an active digestive principle, the enzyme *ptyalin*, which acts upon *starch*, transforming this to *maltose*. The hydrolysis* of carbohydrates shows the following stages:

Fig. 333.—Dissected skulls showing the development of the teeth (Noyes): 1. Skull at nine months, central incisors just erupted, laterals not yet through the gum. The root of the central about half-formed. The lower first and second temporary bicuspids seen in their crypts. The crypt for the lower first permanent molar shown, but the developing tooth has dropped out of it. The upper temporary cuspid and first and second bicuspids are seen in their crypts. Notice the straightness of the lower jaw.

2. Skull at one year. Two incisors in each jaw are erupted. The first bicuspids are just starting. Notice the formation of the root of the lower temporary bicuspids just beginning. Also notice the first permanent molar in its crypt with half of the crown formed.

3. Skull in the second year. The temporary first bicuspid and cuspid partly erupted. Notice the development of their roots. Notice the permanent cuspid above and the first molar below in their crypts.

4. Skull in fourth year. Complete temporary dentition. Notice the upper central, lateral cuspid, and bicuspid in their crypts; the lower incisors, cuspid, first bicuspid, and first permanent molar.

5. Skull in sixth year. Complete temporary dentition with the first permanent molar in place. The lower central incisors have just been lost and the permanent ones are just coming through the gum. The cuspids, bicuspids, and second molar are seen in their crypts.

6. The left side of the same skull as No. 5. Notice the extent to which the roots of the first permanent molar are developed.

7. Front view of the same skull as No. 6. Notice the position of the incisors and cuspids in their crypts.

8. Skull in seventh year. The toothless age. Upper incisors lost and the permanent ones not erupted. One lower incisor in place. First permanent molar in place, but the roots not fully formed. Crown of the second permanent molar seen in its crypt.

* Hydrolysis is a chemical change involving the addition of water. It is typical of the process that goes on in the decomposition of the more complex carbohydrate compounds to the simple sugars which are capable of utilization by the body cells. For example, the disaccharid cane-sugar is hydrolyzed to the monosaccharids, grape-sugar and fruit-sugar, as follows:

$$C_{12}H_{22}O_{11} + H_2O = C_6H_{12}O_6 + C_6H_{12}O_6$$

For full treatment of the chemical changes which foods undergo consult any good book on organic chemistry.

Fig. 334.

Class.	Example.	Formula.
Polysaccharids	Starch, glycogen	$(C_6H_{10}O_5)n$
Trisaccharids	Raffinose	$C_{18}H_{32}O_{16}$
Disaccharids	Sucrose, maltose, lactose	$C_{12}H_{22}O_{11}$
Monosaccharids	Glucose, fructose, galactose	$C_6H_{12}O_6$

Maltose is an intermediary stage in carbohydrate hydrolysis. Conversion to the final stage of the simple sugar is completed by enzymes of the pancreatic and intestinal juices. Thus the chemical action of the saliva in the mouth is relatively slight; the chief action is a mechanical one, rendering the food moist and the surfaces slippery.

Pharynx.—Developmentally, the mouth is only the entrance to the digestive tract. The beginning of the tract is the narrow cavity behind the mouth and nose. This is the pharynx. It is an irregular shaped cavity with numerous openings. Viewed from the side (Fig. 308) it is seen to communicate with the mouth and nasal fossæ and to present openings to the middle ear and larynx. Viewed from the rear (Fig. 335), with the posterior wall cut open, these orifices are more clearly presented. The pharyngeal passage has three parts placed one above the other without any clear line of division. The upper or *nasopharynx* lies behind the nasal fossæ. Its upper limit is defined by the sphenoid bone of the skull. At this site there develops in children the lymphoid growth, called *adenoids*. The lateral walls of the nasopharynx are marked by the openings of the eustachian tubes. The proximity of these openings to the adenoids explains how an enlarged growth of this tissue may occlude the orifices of the tubes and so interfere with hearing. The middle part of the pharynx is the

Fig. 334.—Dissected skulls showing the development of the teeth—Continued (Noyes): 9. Skull in eleventh year. The incisors are in position, but the temporary bicuspids and cuspids are still in position. The second permanent molar is through the bone, but not through the gum.

10. The left side of the same skull. On this side the lower temporary cuspid and first bicuspid have been lost. Note the position of the upper cuspid in these pictures and the distance the root extends toward the orbit. The lateral on the left side is not of typical form, but is a "peg tooth."

11. Skull in the thirteenth year. The lower second bicuspid the only remaining temporary tooth. The second permanent molar is in place, but the roots are not fully developed. The crypt for the third molar (wisdom tooth) is seen.

12. Skull of young adult. The upper centrals are broken. The second molars are fully developed and the third molar shows the crown fully formed in the crypt.

13. Skull of adult. This shows the full permanent dentition and the roots of the teeth.

14. Edentulous jaws. Notice the position of the mental foramen.

oropharynx and corresponds with the region of the mouth. The lower part is the *laryngopharynx*, marked by the laryngeal opening and the epiglottis. Below this portion the pharynx becomes continuous with the esophagus.

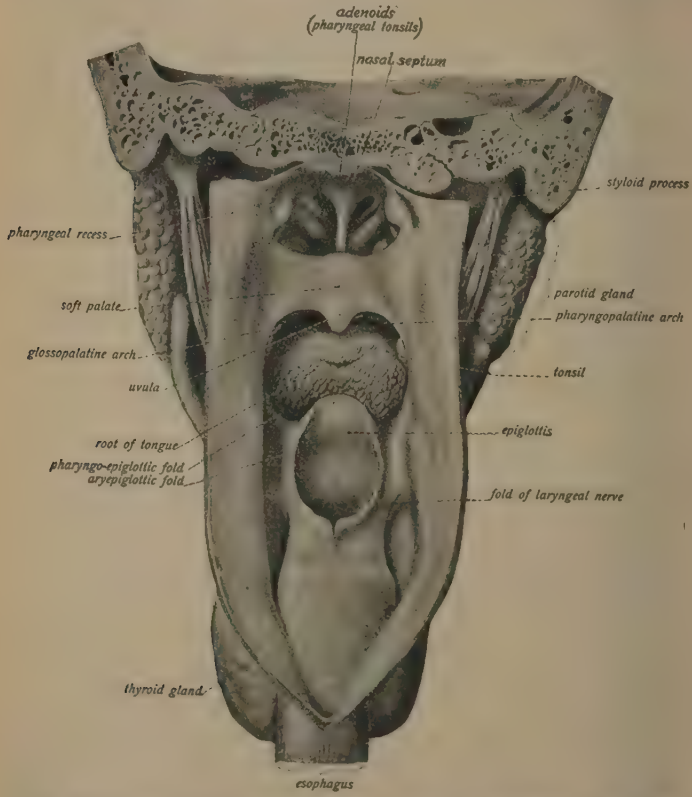

Fig. 335.—View of the pharynx from behind, its posterior wall being divided in the sagittal line. Horizontal incisions have also been made in its upper portion and its posterior and lateral walls reflected (Sobotta and McMurrich).

The pharynx is covered with mucous membrane like that of the passages opening into it. The posterior wall shows irregular masses of lymphoid tissue, more marked in children. The sub-

mucous layer is absent, but a well-defined muscular layer makes possible the constricting movements of the pharynx. Outside of

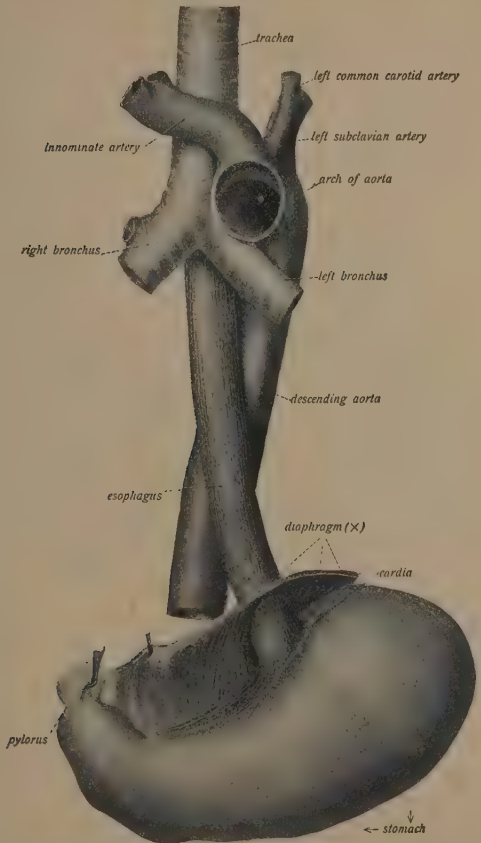

Fig. 336.—Lower portion of the esophagus and the stomach, with the aorta and a part of the diaphragm. The diaphragm and the pylorus of the stomach are drawn upward and the stomach is rather strongly contracted (Sobotta and McMurrich).

the muscle is a fibrous layer that binds the structure to the vertebral column and the deep fascia of the neck.

The blood-vessels come mainly from the external carotid. Lymphatics drain into the deep cervical nodes. Sensory nerves from the ninth and tenth cranial and the autonomic form a plexiform arrangement on the mucous membrane.

Esophagus.—The pharynx continues into the esophagus, a straight tube about 22 cm. (9 inches) long. It is a musculomembranous channel with mucous, submucous, muscular, and fibrous layers. The esophagus curves slightly to the left (Fig. 336) and, passing through the diaphragm, it enters the stomach. Although nearly cylindric in shape it shows three constrictions.*

Stomach.—The stomach is a sac-like dilatation of the digestive tract. It lies in the upper left side of the abdominal cavity just under the diaphragm. It presents an anterior and posterior surface, and its upper and lower borders are marked by curvatures —the *lesser* and *greater*. The opening from the esophagus is called the *cardia*, the opening into the intestine is the *pylorus*. The bulging dilatation at the left end is the *fundus* (Fig. 336).

At birth the stomach occupies an oblique position approaching the vertical position of its earlier stages. After the fourth month it changes to a horizontal position which is typical of the adult. The shape of the stomach varies with the amount of gas present, the emptying of the intestines, and the presence of food. Feldman, quoting Holt, Marfan, and Zuccarelli, gives its volume† as follows:

Age.	Ounces.	Cubic centimeters.
Birth	1.2	36
2 weeks	1.5	42
4 weeks	2.0	60
6 weeks	2.27	68
8 weeks	3.37	100
10 weeks	4.25	128
12 weeks	4.50	132
14–18 weeks	5.00	150
5– 6 months	5.75	172
7–18 months	6.88	200
10–11 months	8.14	244
12–14 months	8.90	265
2 years	11.80	350
3 years	16.85	500
4 years	20.22	600
10 years	25–27.40	750–800

* The three constrictions of the esophagus are important in the passing of a stomach-tube. Huntington gives the following: from the teeth to the first constriction the distance is 15 cm. (6 inches.); from the teeth to the second constriction it is 25 cm. (10 inches); from teeth to third constriction it is 37 cm. (15 inches); and when in the stomach the distance from teeth is 42 cm. (17 inches).

† Physiologic capacity may be larger than anatomic capacity as determined at postmortem.

Coats of the Stomach.—The stomach conforms to the general structural plan of the alimentary canal: it has a mucous, submucous, muscular, and serous layer. The mucous membrane of the stomach is very soft and thick, and shows numerous folds, *rugæ*, running the long way of the organ. The change from the membrane of the esophagus to that of the stomach is very marked. The surface is pitted by numerous holes, the openings of the gastric glands. The glands are composed of cells (Fig. 337) of two types—*chief* and *parietal*. The chief cells are more numerous and secrete pepsin and rennin, the parietal cells produce hydrochloric acid.

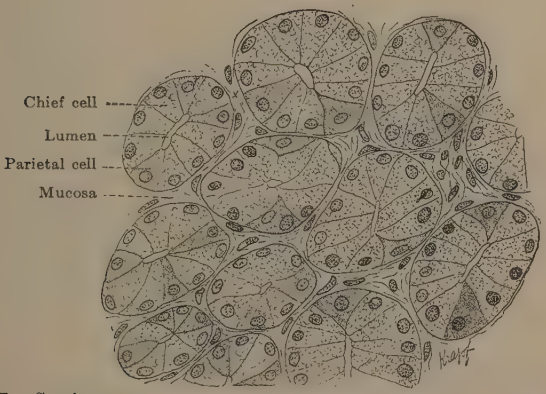

Fig. 337.—Section through fundus of human stomach in a condition of hunger; × 500 (Böhm, Davidoff, and Huber).

The submucous coat is composed of loose connective tissue. It carries the vessels and nerves which pass to the mucous coat and to the muscle.

The muscular coat is composed of three layers: an outer one with the muscle-fibers running longitudinally, a middle one running circularly, and an inner coat, with the fibers disposed in an oblique direction. At the cardia and pylorus there are many muscle-fibers arranged in a circular manner in the form of a sphincter, controlling the opening and closing of these orifices.

The serous coat is composed of peritoneum and invests the organ on both surfaces. The two layers come together at the lesser curvature and are continued upward to the liver as

the *gastrohepatic* or *lesser omentum*. At the greater curvature the two layers of peritoneum are continued (Fig. 308) downward as the *greater omentum*. This structure descends as an apron over the small intestine as far down as the pelvis. It then turns upon itself and ascends as far as the transverse colon, where its two layers split to enclose the transverse colon (Fig. 325). The great omentum contains some fat which in some people accumulates to considerable amount.

It will be noted that the lesser omentum may serve as a support to hold the stomach in place. The right and left margins are

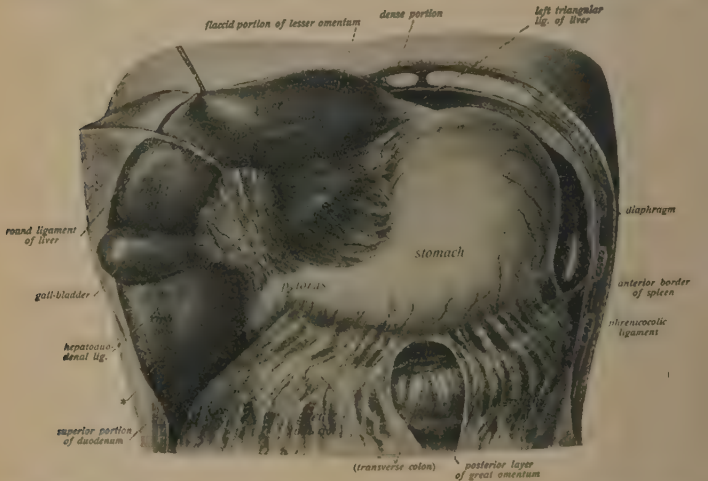

Fig. 338.—The upper portion of the abdominal cavity with the stomach, liver, spleen, and lesser omentum (Sobotta and McMurrich).

heavier than the central portion, and are known as the *hepatoduodenal* and *hepatogastric* ligaments.

Vessels and Nerves of the Stomach.—The arteries of the stomach come from the celiac axis (see page 336). The veins open into the *portal vein*. The lymphatics drain from the pyloric end to the lesser curvature and from the greater curvature toward the pylorus. The nerve supply is from the tenth cranial (vagus) nerves and numerous branches from the autonomic system.

Gastric Digestion.—The food received into the stomach is thoroughly mixed with saliva. The enzyme ptyalin acts only in

an alkaline medium, and since the gastric juice is of acid reaction, the action of the ptyalin soon ceases. Probably in the inner part of a bolus of food the ptyalin may continue its activity for fifteen to twenty minutes, but the outer portions become at once subject to the action of the gastric juice.

This secretion of the stomach is acid in reaction and of sour taste. During the ingestion of food the chief and parietal glands are very active, continuing their activity for some time after the meal. The enzyme pepsin derived from the chief cells possesses the power of breaking down proteins (hence called proteolytic) and changing them as far as the peptone stage. Proteins are very complex, and some of them break down directly into their terminal units; others pass through an intermediary stage, of proteoses and peptones, as indicated by the classification offered by the joint committee of the American Physiological Society and the American Society of Biological Chemists.*

Thus the action of pepsin only starts the digestion of the protein; it is concluded in the intestine. Rennin acts upon the caseinogen of milk, transforming it into a curd of casein. The casein is subsequently reduced by pepsin to the peptone stage. The hydrochloric acid produced by the parietal cells plays a multiform rôle. On entering the duodenum, it acts as a powerful stimulus to the flow of pancreatic juice, intestinal juice, and bile. Upon the food the acid renders the action of pepsin more thorough, shortens the time, and assists in breaking down the cellulose and connective-tissues coverings of the carbohydrates, fats, and proteins.

- * Proteins
  - Simple
    - Albumins
    - Globulins
    - Glutelins
    - Alcohol solubles
    - Albuminoids
    - Histones
    - Protamins
  - Conjugated
    - Nucleoproteins
    - Glycoproteins
    - Phosphoproteins
    - Hemoglobins
    - Lecithoproteins
  - Derived
    - Primary derivatives
      - Proteins
      - Metaproteins
      - Coagulated protein
    - Secondary derivatives
      - Proteoses
      - Peptones
      - Peptids

There is no carbohydrate enzyme, and although a fat enzyme is present in gastric juice, its action is so small that it is relatively unimportant. Hence gastric digestion is essentially proteolytic, reducing protein to peptone.

The Production of Gastric Juice.—If the state of appetite and hunger is present, the gastric glands are stimulated to action by the sight and smell of food and by the presence of food in the stomach. They resemble the salivary glands in responding to psychic and local stimuli. The chewing of indifferent substances,

Fig. 339.—Shadows of the human stomach obtained with the aid of the Roentgen rays fifteen minutes, one hour, and four hours after the ingestion of the bismuth meal (Burton-Opitz).

that are unrelated to food, causes no secretion of gastric juice. The gastric secretion caused by appetite is not necessary to normal digestion. Carlson* notes, however, "If the mechanism is not necessary to health it is at least a factor of safety." This doubtless may be taken as another illustration of the wide margin of safety so generously provided in the body.

For hundreds of years bitter substances have been used in medicine to aid digestion. Some experimenters, notably Pavlov and Borissow, report that bitters before a meal increase appetite gastric juice. On the contrary Carlson and Moorhead found that bitters had no appreciable effect on gastric secretion in normal man. The present evidence would seem to indicate that little importance is to be attached to certain therapeutic measures that are supposed to induce appetite gastric juice.†

* Carlson, A. J.: The Secretion of Gastric Juice in Health and Disease, Physiological Reviews, January, 1923, vol. III, No. 1, pp. 1–40.

† The use of nux vomica in tincture from 15 to 30 minutes before meals is an illustration of a therapy based upon stimulation of appetite gastric secretion.

Movements of the Stomach.—Successive radioscopic pictures of the stomach, after the ingestion of a barium meal,* will show the position and movements of the stomach (Fig. 339). Such pictures show that the fundus of the stomach serves mainly as a reservoir for food and that marked peristaltic waves traverse the pyloric end.† These movements of the stomach result in the passage of liquid portions of the gastric contents, called chyme, into the duodenum.[5] The complete evacuation of the stomach requires several hours, although this time is dependent upon the quantity and quality of the food. Large amounts of food and fats delay evacuation. If the stomach is not empty after four hours its mobility is considered impaired.

Small Intestine.—The small intestine is a cylindric tube 6 to 6.5 meters (about 20 feet) in length. It commences at the pylorus and gradually diminishes in caliber as it passes downward to empty into the colon. The length of the small intestine is somewhat variable.‡ Commonly the small intestine is divided for descriptive purposes into three portions: the *duodenum*, the *jejunum*, and the *ileum*. The first part is firmly attached to the posterior abdominal wall; the second and third parts are freely movable.

The *duodenum* is the first portion of the small intestine and extends for about 20 cm. (8 inches) in a quadrilateral course. Beginning at the stomach, it passes to the right toward the liver. It then turns sharply downward in front of the right kidney, and then again turns, this time to the left, passing in front of the vertebral column, aorta, and inferior cava. These three portions enclose in the space so formed by their turning the head of the pancreas. The fourth and last portion of the duodenum turns upward to join the jejunum. The second portion receives the common bile-ducts, and this opening is marked by an elevation, the papilla of Vater, with a central depression. This orifice may

* The standard test-meal for radioscopic pictures is composed of 3 ounces of barium sulphate with 12 to 16 ounces of cereal gruel or fermented milk. The average emptying time of the stomach is three to six hours.

† These waves may be seen on the abdominal wall in cases of pyloric obstruction.

‡ The tall, thin type of person with trunk of small circumference has a shorter intestine than the heavy rugged type. In negroes the small intestine is shorter and the large intestine longer than in the white man of similar build. There are sex differences also. In a series reported by Treves the extremes were: in the male 31 ft. 10 in. and 15 ft. 6 in.; in the female 29 ft. 4 in. and 18 ft. 10 in.

show two pits, one for the pancreatic duct, the duct of Wirsung, and one for the bile-duct. Above this major opening there is often another, an accessory pancreatic duct opening, the duct of Santorini.

The *jejunum* and *ileum* continue until the latter opens into the large intestine at the cecum. The former extends for about 2.2 meters ($7\frac{1}{2}$ feet) and the latter the remaining distance. There is no distinct line of demarcation between the two. This portion of the small intestine is characterized by having a distinct mesentery.

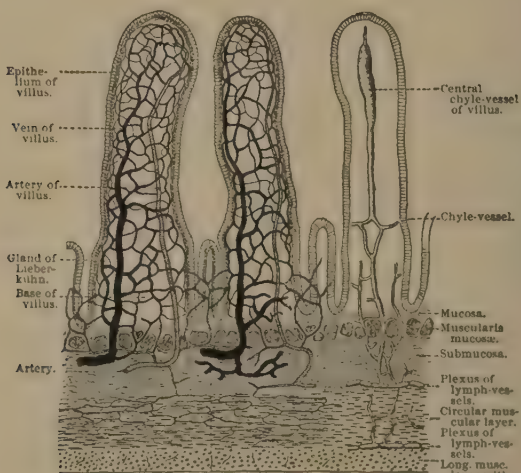

Fig. 340.—Schematic transverse section of the human small intestine (after F. P. Mall).

Structure of the Small Intestine.—It has been noted that the small intestine extends for a variable length as a coiled tube from the stomach to the large intestine or colon. What is the structure of this tube? Does it conform to the general plan of the digestive tract? The four coats of this tract (Fig. 340) are more perfectly represented in the small intestine than elsewhere. The *mucous* coat is thick and very vascular; in children the epithelial cells are packed more closely together than in the adult. The *submucous* coat is composed of loose connective tissue affording a network

for blood-vessels and nerves. The *muscular* coat is in two layers, an outer longitudinal and an inner circular. The *serous* coat completely invests the tube except for a small part where the two layers of the peritoneum come together. In general the small intestine shows then the same structure as the stomach and the preceding parts of the tract. It has, however, distinguishing characteristics.

Valvulæ Conniventes: Beginning about 2 inches beyond the pylorus the mucous coat shows numerous transverse folds that run about half-way around the inside of the tube. These structures, *valvulæ conniventes*, become fewer and lower as they approach the cecum, so that in the lower ileum they occur only as isolated sickle-shaped folds. These folds are similar to those found in the stomach, but differ in the permanence of their form. When the stomach is distended the rugæ disappear; the valvulæ conniventes are permanent structures.

Villi: Closely crowded upon the valvulæ conniventes are numerous finger-like processes, *villi*. Each villus presents a continuation of the mucous membrane covering of the small intestine, and its central core shows blood-vessels, nerves, and lymphatics. The lymphatic of a villus is called a *lacteal*. Digested fat from the intestine passes into the lacteals and thence to the lymphatics emptying into the thoracic duct; digested protein and carbohydrate are collected by the venous capillaries of the portal system and carried to the liver.

Glands of Lieberkühn are tube-like glands found throughout the small and large intestine. In the small intestine these glands or crypts are depressions between the villi and secrete an intestinal juice containing several of the enzymes—*erepsin*, *lactase*, *invertase*, and *maltase*.

Brünner's glands are found only in the duodenum and are a direct continuation of the pyloric glands of the stomach. Brünner's glands secrete the enzyme, *enterokinase*, which, acting upon the *trypsinogen* of the pancreatic juice as it comes into the duodenum, changes it into the powerful digesting *trypsin*.

Lymph-nodules: Masses of lymphoid tissue are scattered throughout the small intestine, but are more numerous in the jejunum and ileum. They may appear as single nodes, the *solitary nodules*, or as aggregations of several nodes, called *Peyer's patches*. In children the lymphoid tissue in the intestine is more numerous than in the adult, even as in the pharynx and elsewhere in the body.

1. Solitary Nodule: The solitary nodule lies in the mucous or submucous coat and projects into the lumen of the intestine. It is connected with the lymphatics of the region and serves in this respect the function observed in lymph-nodes elsewhere in the body.

2. Peyer's Patch: Fifteen to twenty lymph-nodes massed together constitute a Peyer's patch (Fig. 341). They are always found opposite the mesenteric attachment.* They vary in area, but commonly are 2 to 7 cm. (1–3 inches) long and 2.5 cm. (1 inch) wide. During infection in the intestine these lymph-nodes serve the same function that the other nodes do elsewhere



Fig. 341.—A portion of the lower loop of the ileum, cut open along the line of the attachment of the mesentery, showing Peyer's patches (Sobotta and McMurrich).

in the body. Because of their superficial character and the large number of nodes present in the patch severe infection may result in their ulceration. In typhoid fever and in tuberculosis of the intestine ulceration is not uncommon (6.58 per cent. of all cases), resulting at times in the former in perforation of the wall of the intestine.

Vessels and Nerves of the Small Intestine.—The arterial supply is from the superior mesenteric. The mode of distribution is by means of a series of arching branches (Fig. 290) that lie between the two layers of the mesentery of the tube. The venous return is

* Most of them occur in the lower ileum, within two feet of the ileocecal junction.

over the superior mesenteric vein which unites with the splenic to form the portal vein. The lymphatic vessels are very numerous. The lacteals arise in the villi. These join lymphatics from the solitary nodules and Peyer's patches and form a distinct chain of lymphatic vessels that pass between the two layers of the mesentery to reach the thoracic duct. The nerve supply is from the autonomic system and also the tenth cranial, the vagus. The autonomic fibers come from an outlying plexus, the *solar plexus*, and reach the intestine by the route open to the blood-vessels. Nerve-fibers on piercing the outer longitudinal layer of muscle form between the two muscular layers the *plexus of Auerbach;*

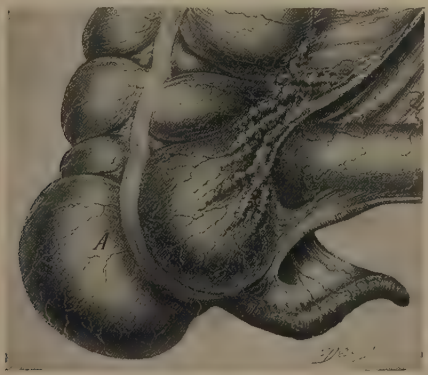

Fig. 342.—The cecum (*A*) with appendix and its mesentery (Campbell).

from this plexus fibers continue on to the submucous coat and form there the *plexus of Meissner*. The connection of the autonomic fibers from the plexuses of Auerbach and Meissner with the lower seven intercostal nerves (see page 232) explains the reference of many internal disturbances to the surface of the body; thus, abdominal rigidity and tenderness which so often precede extension of inflammation from visceral to parietal peritoneum, and the early pains of peritonitis are referred to the umbilicus or epigastrium (solar or superior mesenteric plexuses).

Meckel's Diverticulum.—At times there may be found a blind tube attached to the small intestine about 32 inches from the junction with the colon. This is a remnant of a duct connecting the alimentary canal with the umbilical vesicle, as the yolk sac

of lower animals is called in man. This diverticulum may be open only a short distance or it may extend to the abdominal wall, and appear just below the umbilicus as a pervious tube. This is Meckel's diverticulum.

Large Intestine.—The remaining portion of the digestive tract is called the large intestine, not because of its length (140 cm.—55 inches—in man and 135 cm.—53 inches—in woman), but because of its diameter (about 6 cm.—$2\frac{1}{2}$ inches in its largest part). Three portions are described: cecum, with its attachment, the vermiform appendix, colon, and rectum.

The *cecum* is that part of the large intestine below the opening of the ileum. It is about 6 cm. ($2\frac{1}{2}$ inches) long. Extending from the posterior and mesial aspect of the cecum is the appendix (Fig. 342).

The *vermiform appendix* in man is a rudimentary organ of variable length and size. Its average length is $8\frac{1}{2}$ cm. (3 inches), but it may be as little as 2 and as much as 23 cm. long. There is marked variability in diameter, size of internal opening, and general shape and structure. Its lumen is occluded in 25 per cent. of the cases studied by Ribbert. The degenerate character of this organ is shown by the greater number of occlusions occurring with increase of age. Moreover, the shorter the appendix, the more marked and more often are the signs of occlusion, and hence degeneration. With the length 5 cm. or less the occlusion will show in over 50 per cent. of the cases. The close relation between vestigial structure and susceptibility of such structure to disease is well known.

The coats of the intestine are only barely represented in the appendix. The mucous coat is quite thick and in the submucous coat there is a very large amount of lymphoid tissue. The muscle tissue is scanty and the serous coat, while present, is not continued in the typical mesentery like that of the small intestine, although there is a small supporting band, the meso-appendix. The appendicular artery passes in the meso-appendix to reach the organ.

The *colon* has three parts—ascending, transverse, and descending (Fig. 343). The ascending extends from the cecum to the under surface of the liver, where it makes a turn to the left and becomes the transverse colon. This turn is called the *hepatic flexure*. The transverse colon extends to the left in a horizontal direction, passing in front of the pancreas and close to the lower

border of the stomach. On reaching the spleen it turns downward and becomes the descending colon. This turn is called the *splenic flexure*. The descending colon continues downward on the left side of the abdomen. On reaching the brim of the pelvis

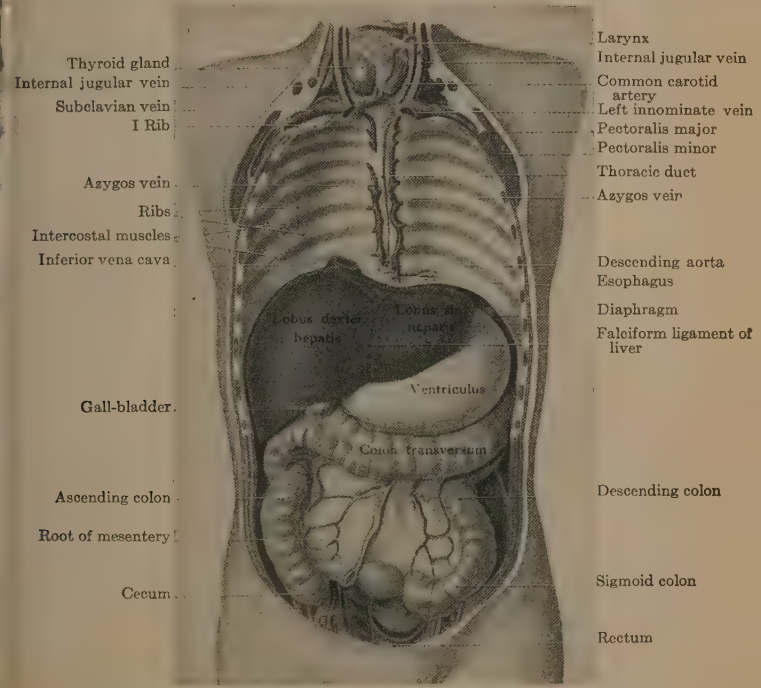

Fig. 343.—The position of the abdominal viscera of a boy. Anterior view. The lungs, the heart, and the anterior half of the diaphragm have been removed; the small intestine has been cut away at the root of the mesentery. From an accurate Leipzig model made from an original dissection (His) (Schultze-Stewart).

it makes a curve like the letter S and takes a position in front of the sacrum, to become the rectum. The S-shaped portion is termed the "sigmoid colon."

The *rectum* is from 15 to 20 cm. (6–8 inches) long and passes downward in the curve of the sacrum and coccyx to terminate in

the lower opening of the tract—the *anus*.* This aperture is formed by both voluntary and involuntary muscle-fibers, comprising two sphincters, internal and external.

Coats of the Large Intestine.—The general plan of structure of the tract obtains here also. The *mucous* coat resembles that of the small intestine. There are no villi, but glands of Lieberkühn are present. Goblet cells are numerous, accounting for the large amount of mucus in this part of the tract. The *submucous* layer is typical and shows here also the plexus of Meissner. Solitary

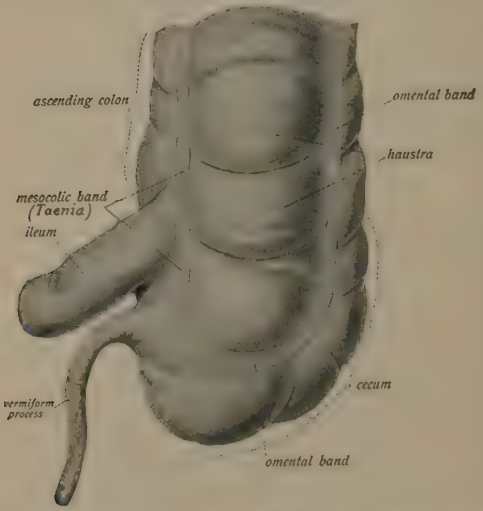

Fig. 344.—The cecum and appendix together with the terminal part of the ileum seen from behind (Sobotta and McMurrich).

lymph-nodules appear through the large intestine, but there are no Peyer's patches. The *muscular layer* shows a marked change in character. The inner or circular layer is present as a well-defined coat. The outer or longitudinal layer appears as three separated bands (Fig. 344) called *tenia*, shirring the tube into numerous sacculations, known as *haustra*. The depressions on the outside between the haustra appear on the inner aspect of

* The direction of the rectum indicates that a rectal syringe should be passed forward and upward and then backward and upward.

the tube as folds. These folds involve all layers of the tube except the serous. The *serous* coat in places is absent, so that the colon is retroperitoneal, as shown in parts of the ascending and descending portions. Attached to the serous membrane are tabs of fat, called *epiploic appendages.*

Vessels and Nerves of the Large Intestine.—The appendix, cecum, ascending and transverse colon are supplied in males by branches of the superior mesenteric artery. In females the appendix may receive a branch from the ovarian artery also. The descending colon and rectum are supplied by branches of the inferior mesenteric artery, and the rectum by additional branches from the iliac arteries. The venous channels follow mainly the arterial, and the lymphatics, especially numerous in the large intestine, enter the thoracic duct. The nerves are from the autonomic by way of the mesenteric, sacral, and hypogastric plexuses, and from the sacral nerves of the cerebrospinal system.

Dilatation of the Colon.—The colon may increase its diameter many times. Thus, in certain diseases, as pneumonia, accumulation of gas may become marked. Or the distention may be caused by solid matter obstructing the lumen in the lower segments. This may be fecal material or may be the result of malignant tumors. Dilatation, occurring in children and young adults, of unknown origin, is not uncommon. It is known as Hirschsprung's disease. These conditions indicate the enormous power of dilatation possessed by this organ.

Enemata and Colon Irrigations.—In instances of poisoning to get rid of toxic substances, in inflammatory conditions of the colon, in dehydration of the tissues from prolonged vomiting, in instances which demand nourishment that cannot be given in the usual way, it is customary to irrigate the colon, or to place therein enemata, as the condition warrants. A quantity of non-irritating liquid introduced slowly 3 to 4 inches into the rectum will often be carried by antiperistaltic waves as far as the cecum. If evacuation is desired, the solution is introduced quickly, producing sudden distention. To supply nourishment nutrient enemata are used. Not over 6 to 8 ounces (180–240 c.c.) can be administered because of the tendency to evacuation. It must be of body temperature and introduced slowly to prevent the reflex peristalsis.

Irrigation of the colon requires inlet and outlet tubes that will give a continuous stream of liquid through the colon. This

is employed "to activate the kidneys or to supply fluid after hemorrhage."* Distilled water is irritating, but normal salt solution is well borne.

PRACTICAL EXERCISES

1. Dissect a rabbit or cat and study the abdominal viscera. Note especially the character of the peritoneum, the visceral and parietal surfaces, the shape and relation of stomach, liver, and intestines.

2. Examine a slide of the human intestinal wall and note the four coats.

3. The taste areas may be grouped into four: sweet, bitter, acid, and salty. Other tastes are combinations of the four or compounded effects of olfactory and taste sensations. The tip of the tongue is most sensitive to sweet, the posterior part to bitter, the margins of the middle segment to acid, and the margins of the anterior third to salty. Try out these four areas with various substances.

4. With tongue depressor make oral examination of the mouth of another student. Note the teeth, look especially for cavities, bridges, crowns. Note the dental hygiene. Are the gums firm and pink or soft and spongy with inflamed margins? Is pus present around the alveolar rims? Depress the tongue well and expose the tonsils. Compare the color of their mucous membrane with the color of the internal wall of the cheek. Are the crypts apparent? Do you notice an exudate in the openings of the crypts?

5. Examine radioscopic plates of the stomach and intestines, noting the time interval for gastric and intestinal digestion. Compare normal and abnormal cases.

6. Cathartics and purgatives are of various kinds. Some act by irritating the nerve endings in the intestinal wall and causing an increased peristalsis; others act according to osmotic laws, forcing water into the intestine by osmotic pressure. At different times try the following preparations and note the subjective effect and character of the stool resulting:

(1) Take ½ ounce of castor oil in milk, orange juice, or ginger ale. Do not stir the layers. The action should be effective within two to six hours.

(2) Take ½ ounce of magnesium sulphate before breakfast. The action should be effective immediately after breakfast.

(3) Take 1 tumbler of citrate of magnesia before breakfast. It should be effective immediately after breakfast.

(4) Take six ½-grain tablets of calomel—one tablet every fifteen minutes beginning at 9.30 P. M. and ending at 10.45 P. M. Follow with one tumblerful of citrate of magnesia in the morning before breakfast.

(5) Take 2 drams of Rochelle salts at night before retiring.

Which of the above are of irritating action?[6]

QUESTIONS

1. On which side of the abdomen does the appendix lie? Could it ever be on the other side?

2. What would be the effect on the nourishment and innervation of the abdominal viscera from relaxation of the abdominal wall and sagging down of the organs? What are the anatomic facts in relation to your answer?

3. What are harelip and cleft palate? How do they occur? Do they result from maternal impressions?

4. Where is the pharyngeal tonsil? The palatine tonsil?

* Bastedo, W. A.: Materia Medica, Pharmacology, and Therapeutics, W. B. Saunders Co., Philadelphia, 1914, p. 135.

5. What is a frequent cause of delayed dentition? What is *pyorrhea alveolaris?*

6. What are valvulæ conniventes? Brünner's glands? Peyer's patches? Lacteals?

7. What is the solar plexus?

8. In typhoid fever ulceration and perforation of the intestinal wall may occur. Where will this perforation most likely be?

9. Describe the appendix.

10. Locate and define the following: hepatic flexure, meso-appendix, haustra, tenia, epiploic appendages, thoracic duct.

11. Describe digestion in the mouth.

12. When do the permanent teeth erupt? How important is it for the temporary teeth to be retained in the jaw until the time for the eruption of the permanent teeth?

REFERENCES FOR FURTHER STUDY

1. Wiedersheim, R.: Elements of the Comparative Anatomy of Vertebrates, Macmillan Co., New York, 1897, pp. 257-272.

2. Walter, H. E.: The Human Skeleton, Macmillan Co., New York, 1918, pp. 45–53.

3. Sherman, H. C.: Chemistry of Food and Nutrition, Macmillan Co., New York, 1920.

4. Burton-Opitz, R.: A Text-book of Physiology, W. B. Saunders Co., Philadelphia, 1920, pp. 926–928.

5. Cannon, W. B.: The Mechanical Factors of Digestion, Longmans, Green & Co., New York, 1911, pp. 32–129.

6. Bastedo, W. A.: Materia Medica, Pharmacology, and Therapeutics, W. B. Saunders Co., Philadelphia, 1914, pp. 110–138.

CHAPTER XV

THE DIGESTIVE SYSTEM—LIVER, PANCREAS, AND SPLEEN—INTESTINAL DIGESTION—ABSORPTION—METABOLISM

I. The Liver:
   1. Surfaces of the Liver.
   2. Internal Structure of the Liver.
II. The Pancreas:
   Internal Structure of the Pancreas.
III. The Spleen:
   Internal Structure of the Spleen.
IV. Intestinal Digestion.
V. The Flow of Intestinal, Pancreatic, and Biliary Juices.
VI. Movement of the Intestinal Contents.
VII. Absorption Phenomena.
VIII. Absorption and Metabolism of Fats:
   1. Obesity.
   2. Fatty Degeneration.
   3. Acidosis.
IX. Absorption and Metabolism of Carbohydrates:
   Diabetes Mellitus.
X. Absorption and Metabolism of Proteins.
XI. Factors Influencing Metabolism:
   1. Vitamins.
   2. Mineral Salts.
   3. Temperature.
   4. Age and Sex.
   5. Muscular Exercise.
   6. Sleep.
XII. Basal Metabolism.
XIII. Heat, Its Production, Dissipation, and Regulation:
   Abnormal Temperature.

The liver is the largest gland in the human body, weighing relatively more in the newborn than in the adult (in the newborn the liver is 4.33 per cent. of body weight, in the adult it is 2.85). It arises as an outgrowth from the digestive tube, and develops as a budding process from the part that ultimately becomes duodenum. It takes a position in the adult in the right hypochondriac and epigastric regions, directly beneath the diaphragm. It extends to the left hypochondrium as far as the mammary line, measuring 25 to 30 cm. (10–12 inches) from side to side. It is

15 to 17 cm. (6 to 7 inches) from front to back and about 10 cm. (4 inches) from above downward in its thickest part. It is held in place by the peritoneal ligaments, the adult representatives of the early embryonic mesentery. The *falciform* ligament, a remnant of the anterior mesentery, attaches to the anterior abdominal wall. It divides the liver into two parts, the right and left lobes (Fig. 333). Above, this peritoneal ligament sends one of its layers to the left as the *left coronary ligament;* and the other to the right as the *right coronary ligament.* Below at the

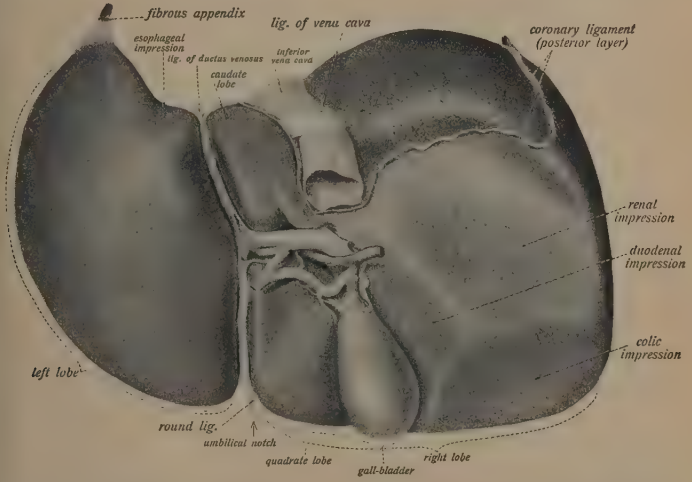

Fig. 345.—The liver seen from below and behind (Sobotta and McMurrich).

lower border of the liver there remains, as a thickened cord, the occluded umbilical vein, now the *round ligament.*

Quite frequently the liver is described as an organ of five lobes, but during life, when the organ is soft and elastic, the only structural lobulation that occurs is in the division into left and right portions. The other lobes at times described can be seen when the organ is hardened *in situ;* they are due to the pressure of organs in relation to the liver.

Surfaces of the Liver.—The anterior surface of the liver is smooth and convex from above downward and from side to side.

The posterior and inferior surface is very irregular and is marked by numerous structures (Fig. 345). The upper part of the right lobe shows a portion devoid of peritoneum where it is attached to the diaphragm. Just to the left of this area is the inferior vena cava partly embedded in the organ. In the middle of the inferior surface is seen the orifice of the portal vein marking its entrance; also the hepatic artery and the hepatic duct, cystic duct and gall-

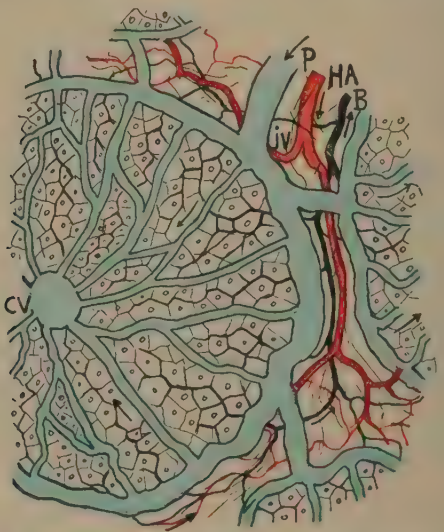

Fig. 346.—Diagrammatic representation of the blood supply of the liver acini: *P*, Portal terminal; *JV*, interlobular veins; *CV*, central veins which are eventually collected in the hepatic vein; *HA*, hepatic arteriole, the interlobular capillaries of which empty into the portal terminals; *B*, biliary capillary which begins as biliary space between the hepatic cells. (Burton-Opitz.)

bladder, and common bile-duct. These vessels entering at the hilum of the liver suggest their related functions: the hepatic artery supplies arterial blood to sustain the liver cells, the portal vein carries food supplies to the organ for certain nutritional needs of the body, and the hepatic duct transmits the secretion of the organ to the gall-bladder, from which it is discharged at certain times through the common duct into the intestine.

Internal Structure of the Liver.—The cells of the liver are arranged in units, called *lobules*, in such fashion as to serve the distribution of the portal blood. The portal vein on entering the liver breaks up into numerous branches that distribute themselves in a network enclosing the lobules. From this network of vessels surrounding each lobule numerous capillaries lead in a radial manner toward the center of the lobule supplying the liver cells that are packed closely along their course (Fig. 346). These liver capillaries empty into a large vein in the center of the lobule, called the central vein. Numerous central veins from different lobules come together to form the sublobular vein which leads to the hepatic veins. The latter vessels empty into the inferior vena cava. The circulation thus described is the venous circulation of the portal system. The liver also receives the ordinary arterial blood which all organs possess. This comes through the hepatic artery, and after thorough distribution to the liver tissue it is returned by veins into the systemic circulation via the inferior vena cava.

The secretion of the liver within each lobule is gathered by small tubules which open into ducts between the lobules (Fig. 347). From these ducts the secretion is carried into larger channels that finally empty into the *hepatic duct.* The latter emerges at the hilum of the liver, pouring its cargo into the *gall-bladder** through the *cystic duct.* The junction of the hepatic and cystic ducts is marked by the formation of the common bile-duct which runs downward for about 3 inches, to enter the duodenum about 3 inches below the pylorus (Fig. 348). The opening of the common bile-duct forms an elevation called the papilla of Vater. This is guarded by a sphincter which keeps the orifice closed except during digestion of food. This aperture is also the common opening for the duct from the pancreas.

The Pancreas.—This is an elongated organ lying with its head in the quadrilateral space formed by the duodenum, with

* The gall-bladder is a musculomembranous bag attached to the under surface of the liver. It receives the cystic duct, which is a branch of the hepatic duct. In the interval between meals the small amount of bile secreted by the liver is stored in the gall-bladder. With the onset of digestive activity the bladder empties itself and the liver cells increase their activity so that copious quantities of bile are delivered to the duodenum. Hard concretions may form in the gall-bladder, giving rise to *gall-stones.* If the stones are small they may escape from time to time. Their passage through the cystic and common bile-ducts is frequently very painful, giving rise to the pain symptoms of gall-bladder colic. Larger stones may blockade the opening of the common bile-duct at the papilla of Vater, causing jaundice.

its body behind the stomach, and with its tail touching the spleen (Fig. 289). It is about 15 cm. (6 inches) long, 5 cm. (2 inches

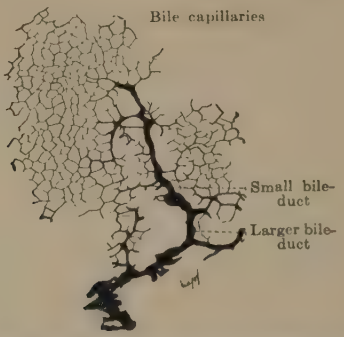

Fig. 347.—From the human liver, showing the beginning of the bile-ducts; × 90 (chrome-silver) (Böhm, Davidoff, and Huber).

wide), and 1 to 2 cm. (about $\frac{1}{2}$ inch) thick. It weighs at birth about $2\frac{1}{2}$ grams and in the adult from 60 to 90 grams (2 to 3

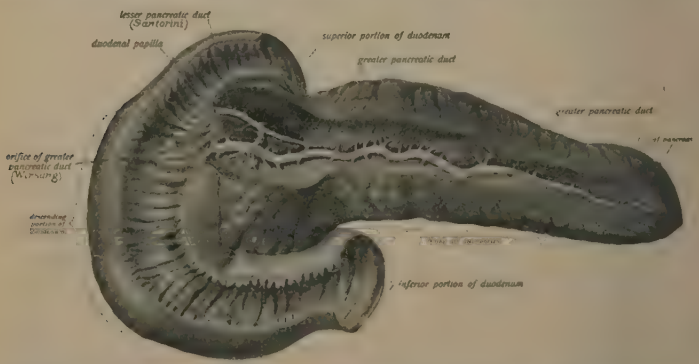

Fig. 348.—Pancreas and duodenum seen from in front. The pancreatic ducts have been exposed by dissection of the pancreas in front; the duodenum has been divided longitudinally (Sobotta and McMurrich).

ounces). An old text on anatomy dismisses the pancreas with the statement that "it is an organ which is very difficult to find,

and therefore has no interest for us." On the contrary, it is one of the most important organs in the body because of the control it exerts over the metabolism of food, especially carbohydrates.

Internal Structure of the Pancreas.—The pancreas is made up of many lobules containing pancreatic cells arranged in the form of secretory tubules (acini). These cells furnish the pancreatic juice which is carried by the interlobular ducts into a main channel running the length of the gland. This main duct is called the *duct of Wirsung*, and opens with the common bile-duct into the duodenum. At times an accessory duct is present, opening separately into the duodenum about an inch above the papilla of Vater. This accessory duct is called the *duct of Santorini* (Fig. 348).

The cells described above supply the pancreatic juice. In addition, there are scattered through the gland numerous groups of cells arranged in spaces between the acini. These cells, known as the *islands of Langerhans*, do not connect with any duct, but give their secretion directly into the blood. Disease of the pancreas with destruction of the cells of the islands of Langerhans gives rise to the condition known as diabetes mellitus.

The **spleen** is topographically and physiologically related to the digestive system, although it may be described under the vascular system. It does not arise from entoderm, as do the other organs of digestion, but probably comes from mesoderm. Some authorities classify it with the endocrine organs giving an internal secretion. This variation in classification emphasizes the uncertainty regarding its essential purpose and illustrates the concern felt by a professor of physiology when one of his students on reciting concerning the function of the spleen, said in a halting and stammering fashion, "I—I did know, but I have forgotten it."

The spleen is a bean-shaped organ lying in the left hypochondrium directly beneath the diaphragm. It weighs from 150 to 180 grams (5 to 6 ounces), is about 12 cm. (5 inches) long, and presents a smooth convex surface of a dark purplish color. It is covered with peritoneum which is reflected from the hilum of the spleen on to the diaphragm and stomach. These peritoneal bands serve as ligaments of support to hold the organ in place. Normally the spleen is movable within narrow limits. It moves with respiration. It may become greatly enlarged during disease, such as typhoid or malaria, or in disease of the organ itself, as

in the leukemias. It enlarges also during digestion. At the hilum of the organ (Fig. 349) the splenic artery enters, breaking up into several branches before gaining the substance of the gland; radicals of the splenic vein may be seen coming from the organ to fuse into a large vessel that joins with the superior mesenteric vein to form the portal vein.

Internal Structure of the Spleen.—Under the peritoneal covering of the spleen is a fibrous coat which sends branching processes

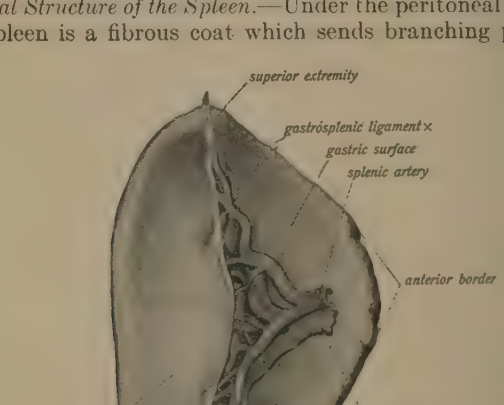

Fig. 349.—The spleen, seen from the hilum (Sobotta and McMurrich).

into the organ, breaking up into numerous fibers to form a network of reticular tissue. Within this network of fibrous tissue are enclosed masses of blood-cells with a great preponderance of white cells. In addition to this typical splenic pulp, as it is called, there are scattered areas having a whitish appearance, called *malpighian* bodies. These are merely collections of white cells around the smaller blood-vessels.

Intestinal Digestion.—Digestion of food in the intestine occurs in an alkaline medium furnished by the intestinal, pancreatic, and biliary juices. The intestinal juice derived from the glands of Lieberkühn contains several enzymes: a proteolytic one,

erepsin, and two amylolytic ones, *invertase* and *maltase*. Erepsin reduces proteins and peptones to simple protein units, called amino-acids. Invertase and maltase change the disaccharids, sucrose and maltose, to monosaccharids. The intestinal mucosa furnishes no fat enzyme.

The pancreatic juice contains also three enzymes: trypsin, amylase, and lipase. *Trypsin* is a very powerful proteolytic enzyme. In the cells of the pancreas it exists as an inactive form, *trypsinogen*, and is secreted as such. Coming into the duodenum it is transformed into *trypsin* by the action of *enterokinase* derived from Brünner's glands. The resulting trypsin carries the cleavage of proteins past the peptone stage to the final units, namely, amino-acids. The *amylase* converts starch into maltose, an action similar to that of the saliva; maltase carries the process further, resulting in the simple sugars. The *lipase* is a fat enzyme which splits fat into fatty acids and glycerin. Before the action of lipase the fats are emulsified by a mechanical process, which separates the larger fat globules into minute ones. After emulsification the splitting of fat into fatty acids and glycerin is easily performed. The fatty acids subsequently unite with the alkali of the intestinal contents, forming soaps.* In this soluble form they pass through the walls of the intestinal villi and enter the lacteals, which empty ultimately into the thoracic duct. The fatty acids and glycerin are present largely in the upper small intestine, while in the lower segments the soaps are in abundance.

The bile secreted by the liver cells is poured into the duodenum during the digestive process following a meal. On entering the duodenum via the common bile-duct, it presents certain characters: it is alkaline, bitter, and viscous. It contains bile-pigments that color the intestinal contents, furnishes bile salts whose function is not clearly known, and it exerts a distinct antiseptic effect in the intestine.† Bile contains no enzyme, but

* Fats and oils of the food liquefy at body temperatures. Each molecule of fat is a chemical combination of one molecule of glycerin and three molecules of a fatty acid. The fatty acids are palmitic, stearic, and oleic, and the fats derived from them are palmitin, stearin, and olein. The saponification of stearin is represented graphically as follows:

$$\underset{\text{Stearin.}}{C_3H_5(C_{18}H_{35}O_2)_3} + 3\underset{\substack{\text{Potassium}\\\text{hydroxid.}}}{KOH} \rightarrow \underset{\text{Glycerin.}}{C_3H_5(OH)_3} + 3\underset{\text{Soap.}}{K(C_{18}H_{35}O_2)}$$

† Conditions in which bile does not enter the intestinal tract give feces that are malodorous and of a pasty, gray color. Bile itself is not distinctly antiseptic, but by hastening the absorption of substances that readily produce putrefaction *its effect* is said to be antiseptic.

nevertheless plays an important part in the emulsification and saponification of fats.

The Flow of Intestinal, Pancreatic, and Biliary Juices.—Stimulating factors similar to those producing salivary and gastric juices are also active in this part of the digestive tract. The psychic factor, however, is not very prominent, and the secretagogue mechanism is much more important. Soon after the acid chyme enters the duodenum the pancreas, intestine, and liver begin to pour out their secretions. This results from an activation of the secretagogue in the duodenal mucosa by the acid chyme. The name given to the substance so activated is *secretin*. This passes into the blood-stream and stimulates pancreatic, intestinal, and hepatic activity. Thus secretin acting through the blood upon distant parts shows a hormonic action, although it is not to be confused with the autacoids of the endocrine organs.

Movement of the Intestinal Contents.—The movement of food materials from the pylorus to the anus is facilitated by a rhythmic contraction or *peristalsis* that is marked in the small intestine and the ascending portion of the colon. In the transverse and descending colon peristalsis occurs at infrequent intervals. Normally, in the early morning, a series of contractions carry the fecal material from the transverse colon into the descending portion, and thence into the sigmoid and rectum. Its descent to this point stimulates nerve endings in the mucous membrane of the rectum, resulting normally in evacuation.

The food of one day is usually evacuated on the morning of the following day. It requires about five hours to traverse the small intestine and about twenty hours to pass the large intestine. In the former it is of watery consistency; in the latter most of the water with its contained nutritive substances in solution has been absorbed, so that only semisolid material remains. The feces so formed and the position and movements of the colon may be pictorially shown by means of a radioscopic picture (Fig. 350).

Absorption Phenomena.—The digestive process results in simplified food-stuffs. The complex masses of fat, carbohydrate, and protein are reduced to their elements. But until these elements have passed into the blood-stream or lymphatic channels the food has not entered the body. This passage of digested food through the wall of the digestive tract is called "absorption."

The nature of the absorptive process is not simple. The passage of water through the gastric and intestinal mucous membrane

pparently follows physical laws. Thus certain processes in the ıse of laxative salts are to be explained. The taking of mag- ıesium sulphate, for example, increases the molecular concentra- ion of the fluids in the intestinal tract, and because this oncentration is greater than that in the capillaries supplying the ırea, water is forced into the lumen of the intestine. This phenom- ınon is called *osmosis* and the pressure responsible for the ıovement of the water is the *osmotic pressure.*

This characteristic of fluids of different molecular concen- ıration to form a uniform mixture is a well-known phenomenon ın physics. It is termed *diffusion* when no membrane separates

Fig. 350.—Shadows of the human large intestine obtained by means of the Roentgen rays: I, Entrance of the contents of the ileum into the cecum and colon. II, The material has progressed through the transverse colon as far as the splenic flexure; some has escaped into rectum. III, The large intestine outlined by means of a solution of subnitrate of bismuth injected through the rectum. (Burton-Opitz.)

the fluids. Diffusion of gases occurs in the lungs when oxygen of the tidal air moves toward the alveoli where the molecular concentration of oxygen is lower, and carbon dioxid of the alveoli moves toward the tidal air where the molecular concentration of carbon dioxid is lower. Diffusion as a phenomenon takes place in many places in the body; osmosis occurs in the digestive tract and possibly between the cells and the tissue fluids.

The passage of water and crystalline substances through an animal membrane occurs by osmosis, but the chief absorptive changes in the body are concerned with organic compounds that do not readily pass through membrane. The membranes of the body are semipermeable, permitting water to pass through, and also the organic substances in solution. This is known as *dialysis.*

When two fluids are of equal molecular concentration there is equal interchange. In the body, fluids are classified according to their influence upon red blood-cells, because if blood-cells are brought in contact with a fluid other than normal serum, they swell, shrink, or remain normal. If they remain normal the fluid is said to be *isotonic* to them and to blood-plasma, meaning that the molecular concentration is the same. If they swell, the solution is *hypotonic, i. e.*, its osmotic pressure is less than plasma; if they shrink, the solution is *hypertonic, i. e.*, its pressure is greater than plasma.

Absorption and Metabolism of Fats.—The mechanical process of absorption, illustrated by phenomena of diffusion, osmosis, and dialysis, does not entirely explain the passage of food-stuffs through the wall of the digestive tract. Thus, fatty acids and glycerin from the upper segments of the intestine and soaps from the lower are taken up by the intestinal cells by some power residing in the cells. This process consists in splitting the soaps to fatty acids and glycerin and in building up neutral fat. The fat is then passed into the lacteals and ultimately reaches the circulation via the thoracic duct.

The metabolism of this fat in the body proceeds by changes that the cells themselves make. The cells are to be considered as chemical laboratories capable of building the needed structures out of the available material. Thus they may use the fat as storage material, or if needed for activity they may burn it, releasing energy and yielding the products of this catabolic activity in carbon dioxid and water. Some cells are especially adapted for the storage of fat, notably the liver, the subcutaneous fascia, the omentum, and the retroperitoneal spaces. From these storehouses the body cells may draw upon when the local supply is used up.

Obesity.—The intake of food-stuffs may exceed the energy needs of the individual and the margin is stored as fat. This is true for carbohydrates and proteins as well as fats, since the body can form fat from the first two. This storage of fat may be so increased that the different fat storehouses are greatly overfilled, a condition known as *obesity*. In some persons this retention of fat occurs even on a greatly reduced diet, indicating either a high efficiency in utilization of food materials or possibly a disturbance of metabolism due to disordered secretions of endocrine organs. In most persons, however, an increased expenditure of energy

through physical activity and a decreased supply of energy foods through a restricted diet will result in oxidation of the deposited fat.

Fatty Degeneration.—Normal cells contain fat in their cytoplasm. Due to poisonous processess in the cells changes may occur in which there is an unusual deposition of fat in the cells. Thus, the heart muscle, liver, and kidneys may exhibit fatty degeneration, and because of the loss of their normal constituents show an impaired functional power.

Acidosis.—Complete oxidation of fat gives carbon dioxid and water. Incomplete oxidation results in intermediate products that are eliminated with great difficulty by the body and act as poisons to the tissues. Thus, in diabetes, where the metabolism of sugar is interfered with, the fats are not burned completely unless their combustion is accelerated by the heat derived from oxidizing sugar. "In the absence of this heat the fats are imperfectly oxidized."* The products of this incomplete oxidation are aceto-acetic and β-oxybutyric acid. These substances produce a condition known as *acidosis.*

Absorption and Metabolism of Carbohydrates.—The monosaccharids are readily dialyzable and hence easily absorbed into the blood-channels of the portal system. The polysaccharids must undergo hydrolysis before they can be taken up, but ultimately the starches are hydrolyzed to the simple sugars and absorbed as such. Normally the blood contains 0.1 to 0.15 per cent. of sugar, but after meals the portal blood contains much more than that. It is also known that the liver contains quantities of *glycogen* $(C_6H_{10}O_5)n$, and hence it is stated that the liver stores the excess above the amount found in the blood.

The ultilization by the body cells of the blood-sugar requires a continual replacement. This deficit is made up by the liver. Hence in the liver carbohydrate metabolism shows a dual process: conversion of sugar to glycogen, and a hydrolysis of the glycogen to simple sugar. If carbohydrate is ingested above the limits of the liver to store it as glycogen, the excess is transformed in the tissues to fat and stored as such.

The storage of sugar as glycogen in the liver and the distribution of sugar to the blood are supposed to be under the control of a center in the medulla, called the *glycogenic center.* Injuries to

* Burton-Opitz, R.: Text-book of Physiology, W. B. Saunders Co., Philadelphia, 1920, p. 1043.

the medulla or to certain divisions of the autonomic nervous system result in an increase of sugar in the blood, called *hyperglycemia*, and the presence of sugar in the urine, called *glycosuria*.

Diabetes Mellitus.—The metabolism of all the food-stuffs is exceedingly complex. Body needs, nervous influences, and secretions of endocrine glands influence the process. The latter factor is particularly important in the capacity of the tissues to oxidize sugar. Disturbance of the pancreatic internal secretion results in an inability of the body to burn sugar, hyperglycemia develops, followed by glycosuria. This is the beginning picture of *diabetes mellitus*. If this condition is severe, the disturbed sugar metabolism reacts upon the metabolism of fat. Incomplete combustion of fat occurs and the diabetes grows worse because of the superimposed acidosis.*

Absorption and Metabolism of Proteins.—The proteins are digested to their terminal units, the amino-acids. As such they are absorbed into the blood. They are subsequently built up into the protein tissue of the body. In the metabolic processes by which the body carries on its activities protein of the body cells is utilized. Its waste products are carbon-dioxid, water, and nitrogen-containing substances, such as *urea*, *creatin*, *creatinin*, and the *purin bases*. The amount of nitrogen in the waste products of protein metabolism is a measure of the amount of protein burned in the body from either the circulating protein or the tissue protein, or both. The body is continually using protein in its metabolic activities, and the amount used can be determined by measuring the amount of nitrogen in the waste eliminated. If the nitrogen of the food and the nitrogen of body waste are determined, it is possible to compute the nitrogen intake and output. If the output exceeds the intake, it means that the body is burning its own protein to supply its needs. By controlling the intake to the point where output and intake balance we reach a condition of equilibrium, known in chemistry as "nitrogen equilibrium." If the intake exceeds the output it means that protein is being stored.† Abundance of protein is desirable in

* Recently very favorable therapeutic results have been announced from the use of a pancreatic extract, called *insulin*, named from the islands (insula) of Langerhans.

† Protein is not stored as protein, but as fat or carbohydrate. There is abundant proof of the production of carbohydrate from protein and some evidence that fat may be produced from protein. At least fat may be produced indirectly, since carbohydrate contributes to fat formation.

childhood and during convalescence. At other times it is desirable to maintain an equilibrium. While the tendency in the past was to provide 100 gm. of protein in the diet, the recent emphasis has been to lower that to 75 gm., and some experiments indicate that from 35 to 40 gm. of protein are sufficient.

Factors Influencing Metabolism.—The utilization by the body of the foods absorbed is influenced by a number of factors. In some instances metabolism is increased, in others it is hindered.

Vitamins.—Metabolic activity as indicated in growth and normal function is dependent upon certain substances called *vitamins.* They have been classified in five groups—A, B, C, D, and E. Doubtless there are others or subdivisions of these to be isolated. Numerous experiments have demonstrated that vitamins were absolutely essential for normal growth.* Nutrition and resistance to disease are also influenced by these substances. Moreover, the absence of certain vitamins from the diet results in disease. Thus scurvy is due to a lack of vitamin C, beriberi to deficiency in B, rickets to insufficiency in A.

Mineral Salts.—Normal metabolism is influenced by the mineral salts ingested. Thus iron, calcium, phosphorus, and iodin have been placed in leading rôles in this respect.

Temperature.—Cold increases metabolism in man.† Extreme variation in temperature decreases metabolism. Temperature of the body is normally 98.6° (37.0° C.). In conditions of fever there is a disturbance of the heat-regulating control, and hence an increase in metabolic activity, with a resulting increase in temperature. Hence conditions of fever such as typhoid are accompanied by a loss of body weight unless the oxidation of food materials is made up by the ingestion of food.

Age and Sex.—Metabolism in the infant and child up to the sixth year is very rapid. This is due to the growth needs of the organism and to the relatively large surface area of the body. After the sixth year it decreases until the onset of puberty, after which it falls again until the twentieth year. After twenty it gradually falls again, until in late adult life metabolism is at a low ebb. It is generally less in the female than it is in the male.

Muscular Exercise.—Physical activity greatly increase metabolism of the carbohydrates and fats. If the activity is severe,

* Eddy, W. H.: The Vitamin Manual, Williams & Wilkins Co., Baltimore, 1921, pp. 89–93.

† Lusk, G.: The Science of Nutrition, W. B. Saunders Co., Philadelphia.

protein metabolism is accelerated also. This fact shows that for average activity the fats and carbohydrates are burned first, and hence are said "to spare protein."

Sleep.—The reverse of physical activity is noted in sleep. Here all the functions of the body are lessened and the metabolism is decreased.

Basal Metabolism.—Food taken into the body is utilized as a source of energy for action or for tissue building. This power to yield energy resides in the heat-producing power of the food. The heat of food is measured in terms of the calorie, which is the amount of heat required to raise 1 kilogram of water 1° C. Using such a standard of measurement it has been found that

1 gram of carbohydrate yields	4.1° C.
1 gram of fat yields	9.3° C.
1 gram of protein yields	4.1° C.

Probably not all of this yield is available for the tissues, since some is lost in digestion. The heat production of an individual at rest, at least eighteen hours after eating, is called the *basal metabolism.*[1] This fundamental metabolic activity is dependent upon the activity of the body cells and to some extent on body weight and body area. The basal metabolism of boys, men, and women is given by DuBois as follows:

Basal Metabolism of Boys, Men, and Women

Subjects.	Age in years.	Calories per hour per square meter of body surface.	
		Meeh.	DuBois (height-weight).
Boys	12–13	45.7	49.9
Men	20–50	34.7	39.7
Women	20–50	32.3	36.9
Men	50–60	30.8	35.2
Women	50–60	28.7	32.7
Men	67–83	....	35.1

Heat, Its Production, Dissipation, and Regulation.—The chemical changes occurring in the metabolic activities of the body yield energy in the form of heat. Heat comes, therefore, from food materials. This production of heat is not constant, but

a variable process depending upon several factors. In particular, muscular activity increases heat production and rest lessens it. Cold accelerates metabolic changes as a result of a reflex activity which is arranged to supply needs of the organism. Foods eaten influence heat production, *e. g.*, fats yielding more units of heat than either proteins or carbohydrates.

Heat is lost from the body in two ways: by radiation or conduction from the body surfaces, and by the heated materials in the fluid and semisolid excreta. Of these two ways, the former shows a greater heat loss. The large area of the skin and the exposed mucous membranes hold large quantities of blood near the surface. The loss of heat from this area easily occurs, except under conditions favoring heat retention, *e. g.*, high temperature of the surrounding air, high humidity, warm clothing over the body. Loss of heat may be controlled by the vasomotor mechanism, constricting the surface vessels and driving the blood to internal channels.

The reflex mechanism that can readily alter the amount of blood in the surface vessels suggests that heat production and heat dissipation do not go on unregulated, but rather that there is heat regulation. That heat production and dissipation are regulated is well known, but just what the mechanism of regulation is remains a secret. Unquestionably the nervous system is involved in the process, but in what fashion is still unknown. There is some evidence of a *heat center* in the brain; there may be more than one center, and they may be of an acceleratory and of an inhibitory character.

Whatever the exact mechanism, it is known that the production and dissipation of heat are controlled so that the body temperature is maintained at fairly constant levels, varying from a low point about 5 o'clock in the morning to a point one- to two-tenths higher at 6 or 7 o'clock in the evening. "The average axillary temperature is 36.9° C., the oral temperature 37.1° C., and the rectal temperature 37.3° C." On the Fahrenheit scale these temperatures are approximately: 98°, 98.6°, and 99°.

Abnormal Temperature.—A disturbance in regulation of heat production or heat dissipation, or both, results in an abnormal temperature. If the temperature is below normal it is called *subnormal;* if above, it is designated *pyrexia.* Pyrexia is frequently the accompaniment of the condition of fever that results from an invasion of the body by pathogenic bacteria. Appar-

ently the toxins set free by the pathologic process reacts on the heat-regulating mechanism, and interferes with heat production, heat dissipation, or both.[2]

PRACTICAL EXERCISES

1. The action of pepsin on protein may be demonstrated as follows: Mix the white of egg with cold water, and fill a test-tube half full of the mixture. Add dry pepsin and a few drops of hydrochloric acid to give an acid reaction. Place the tube in oven, fireless cooker, or near radiator for four to ten hours. Then pour contents of test-tube into an apparatus to test osmosis.* After one hour test the water for protein by Millon's reagent. This gives a white precipitate which turns red on covering, or a red color if a small amount of protein is present.[3]

2. Repeat the experiment, but omit the hydrochloric acid. Repeat and omit both hydrochloric acid and pepsin. Does the egg-white go through the membrane? What conclusion can be drawn from these experiments?

3. The action of pancreatic juice on protein may be demonstrated by repeating the above experiment and substituting pancreatic extract for the pepsin, and sodium carbonate (to render the mixture alkaline) for the hydrochloric acid. What conclusions are to be drawn concerning this experiment?

4. Examine a drop of cream under the microscope. Note the fat cells. Examine a drop of milk under the microscope. Add a drop of 10 per cent. caustic soda and re-examine. What has happened?

5. Saponification of fats is an essential part of intestinal digestion. A soap is made by the action of an alkali on a fat. Castile soap, for example, is made by the action of sodium hydroxid on olive oil, *e. g.*,

$$\underset{\text{Olein.}}{C_3H_5(C_{18}H_{33}O_2)_3} + 3\underset{\substack{\text{Sodium}\\ \text{hydroxide.}}}{NaOH} = 3\underset{\text{Castile soap.}}{NaC_{18}H_{33}O_2} + \underset{\text{Glycerin.}}{C_3H_5(OH)_3}$$

6. With a thermometer take the axillary temperature and the oral temperature.

7. Record the temperature every hour during a period of twelve hours, noting any variations. Explain.

8. Take the temperature. Perform thirty deep knee bendings and take temperature again. Is there any change? Explain.

QUESTIONS

1. What are the ligamentous supports of the liver?
2. What is the origin of bile? How does it get into the intestine?
3. What is an acinus?
4. What results from disease of the islands of Langerhans?
5. Describe gastric and intestinal digestion.[4] What is a secretagogue?
6. What is osmosis? What is an isotonic solution? Is normal salt solution isotonic?
7. Describe the circulation of the liver.
8. What are the chief supports of the abdominal viscera?
9. Where does the common bile-duct empty?
10. What is the gall-bladder?
11. What are common food sources of protein, of fat, and of carbohydrate? What foods should be included in a daily dietary to supply essential vitamins?
12. What selection of food should be made to secure mineral salts?

* A membrane bag (diffusion shell) may be secured from dealers in scientific apparatus.

REFERENCES FOR FURTHER STUDY

1. Lusk, G.: The Science of Nutrition, W. B. Saunders Co., Philadelphia, 1919, pp. 125–129, 141, 301–322, 553–559.

2. Burton-Opitz: Text-book of Physiology, W. B. Saunders Co., Philadelphia, 1920, pp. 1106–1108.

3. Bigelow, M. A. and A. N.: Applied Biology, The Macmillan Co., New York, 1911, pp. 474–484.

4. Sherman, H. C.: Chemistry of Food and Nutrition, Second Edition, The Macmillan Co., New York, 1920. The entire book is very helpful.

CHAPTER XVI

THE EXCRETORY SYSTEM

I. Development of the Excretory System.
II. The Kidneys:
    1. Internal Structure of the Kidney.
    2. Vessels and Nerves of the Kidney.
III. The Ureters.
IV. The Bladder.
V. The Urethra.
VI. How the Kidneys Secrete Urine.
VII. The Composition of the Urine:
    1. Water.
    2. Inorganic Substances.
    3. Organic Substances.
    4. Coloring Materials.
    5. Gases.
    6. Abnormal Constituents.
VIII. Micturition:
    1. Enuresis.
    2. Incontinence of Urine.
    3. Retention of Urine.
    4. Suppression of Urine.
IX. Quantity of Urine.
X. Modifying Kidney Action.

Development of the Excretory System.*—In all classes of vertebrates the urogenital apparatus comprises two related systems: the urinary and the generative. In man the early stages of embryonic development show this same close relationship, and in the individual after birth the proximity of parts still suggests a related origin. A study of the urinary system in its development[1] will help to make clear the anatomy of the fully formed structures, the kidneys, ureters, and bladder.

Even before the fourth week there arises from the epithelium of the body cavity (which corresponds with the abdominal cavity) a series of tubules that open into a common canal. This is a stage of the *pronephros*, transitory in man but found in many

* The term "excretory system" is used here to include only the kidneys. It is true that the lungs eliminate waste, but their chief function is respiratory and they are best described in that category. Also the skin eliminates much water and a little organic and inorganic material. It is more appropriately described, however, as an organ of special sense.

fishes and amphibians. In close relation with this structure is the genital gland, *gonad*, of indifferent sexual structure. The

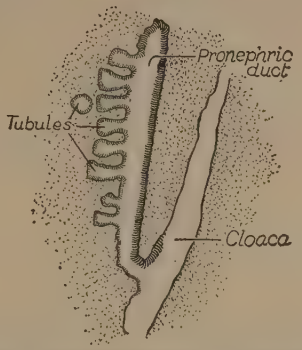

Fig. 351.—Diagram of longitudinal section of pronephric tubules and duct.

pronephric duct extends toward the tail end of the animal and opens into the *cloaca*, the dilated terminal of the intestinal tube (Fig. 351). The ending of each tubule shows a group of con-

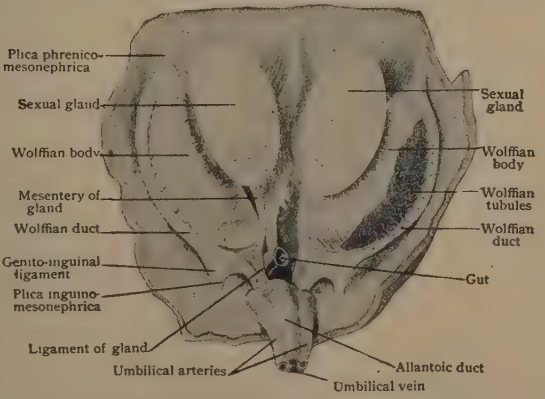

Fig. 352.—Mesonephric organs (wolffian bodies) and sexual glands of human embryo of about six weeks (17 mm. long); ×51 (modified from Kollmann).

voluted blood-vessels, the *glomerulus*, the typical unit of structure of the kidney in man. The next stage shows the formation of the *mesonephros* (Fig. 352) from the nephrotome, a structure lateral

to the myotome (Fig. 157), while some of the tubules of the pronephros are still in existence. The pronephric duct becomes the *mesonephric duct* which opens as did its predecessor into the cloaca (Fig. 353). Dorsal to this canal appear the müllerian ducts which play a prominent part in the formation of the generative apparatus. Many of the structures of the mesonephros persist as parts of the generative apparatus. Thus, in the male (Fig. 354) the mesonephric duct and tubules become the vas deferens and epididymis; in the female the change is more complete

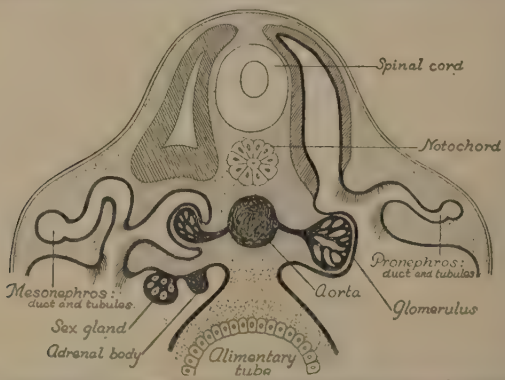

Fig. 353.—Diagram of cross section showing structures of pronephros (on right) and mesonephros (on left) (after Wiedersheim).

and the only remains are the epoöphoron and Gärtner's duct. The müllerian duct in the male disappears except for its upper extremity, which becomes a small appendage of the testis and a small vesicle in the lower end, which fuses into the prostatic portion of the male urethra. In the female the müllerian ducts form the fallopian tubes and, fusing together in their lower end, compose the uterus and vagina.

The pronephros and mesonephros are both urinary secretory organs. In some of the lower animals* the mesonephros attains considerable prominence in this respect; the pronephros is always a transitory organ. But these two types herald the appearance of the kidney. Their glomeruli, tubules, and ducts set the pattern around which the kidney as such is to be built.† In mam-

* Elasmobranchs and amphibians.

† Various anomalies may occur: the two kidneys may be fused at their lower poles, the *horseshoe kidney;* there may occur a malposition, the *misplaced kidney;* or it may not be securely attached, the *movable kidney.*

mals the development of the metanephros or functional kidney begins as a pouch-like growth from the wall of the mesonephric duct. In man this structure appears as early as the fourth week; the tube itself remains as the ureter and the dilated upper end as the pelvis of the kidney.

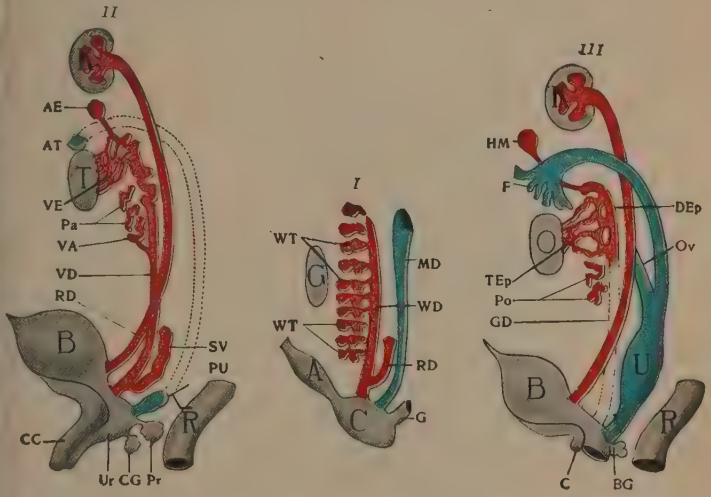

Fig. 354.—Diagrams illustrating differentiation of two sexes from indifferent type: I, *Indifferent: G*, sexual gland; *WD*, mesonephric duct; *WT*, groups of mesonephric tubules; *MD*, müllerian duct; *RD*, renal diverticulum; *C*, cloaca; *G*, gut; II, *Male: T*, testicle; *VE*, vasa efferentia; *VD*, vas deferens; *Pa*, paradidymis; *VA*, vas aberrans; *SV*, seminal vesicle; *AT*, appendix testis; *AE*, appendix epididymidis; *B*, bladder; *PU*, prostatic utricle; *Pr*, prostate; *Ur*, urethra; *CG*, Cowper's gland; *CC*, corpus cavernosum; *R*, rectum, *RD*, renal duct; *K*, kidney. III, *Female: O*, ovary; *OV*, oviduct; *F*, fimbria; *U*, uterus; *V*, vagina; *DEp*, duct of epoöphoron; *TEp*, tubules of epoöphoron; *PO*, paroöphoron; *HM*, hydatid of Morgagni; *GD*, Gärtner's duct; *BG*, Bartholin's gland; *C*, clitoris; *K*, kidney; *R*, rectum. (Modified from Wiedersheim.)

The **kidneys** are paired organs lying at the back of the abdominal cavity (Fig. 289) behind the peritoneum.* They are, therefore, without the peritoneal cavity. Embedded in a large amount of fat, they occupy a space about 10 cm. (4 inches) long,

* This retroperitoneal character of the kidney explains in part the surgical procedure in operations on the kidneys. The surgeon enters from behind, thus avoiding the peritoneal cavity.

5 cm. (2 inches) wide, and 2.5 cm. (1 inch) thick. Their weight is about 135 grams (4½ ounces). On examination (Fig. 355) they are seen to be bean-shaped with concavity toward the median line of the body. On this concave border there is a depression, the *hilum* of the kidney, which marks the entrance of vessels and nerves and the emergence of the renal pelvis. They are covered by a fibrous sheath of connective tissue, called the *capsule* of the kidney.

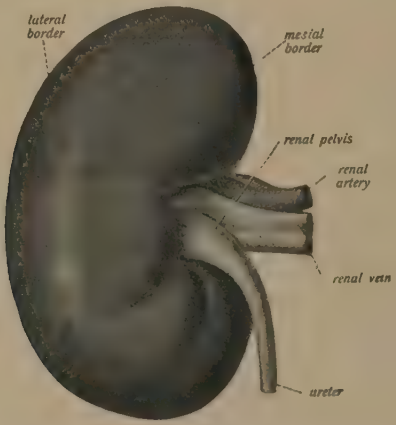

Fig. 355.—The left kidney seen from behind (Sobotta and McMurrich).

Internal Structure of the Kidney.—The unit of structure of the kidney is the uriniferous tubule (Fig. 356). This unit will be seen to embody the same plan of structure that was found in the pronephros and mesonephros. A tuft of capillaries (Fig. 357) called the *glomerulus* is surrounded by a capsule, *Bowman's capsule*, which is the beginning of the uriniferous tubule. Passing from Bowman's capsule there is a convoluted tubule, called the *proximal* or *first convoluted tubule*. This structure is of considerable length and terminates in a tube very much smaller, described as the *descending limb*, and *ascending limb* of the *loop of Henle*. From the ascending limb of the loop begins the *distal* or *second convoluted tubule* which connects with the main collecting tubule opening into the renal pelvis by a pouch-like elevation called the *papilla*. The appearance of the cut section of the

kidney and the different parts is due to the arrangement of the uriniferous tubule.

If a vertical section (Fig. 358) is made of a fresh kidney certain characteristic structures appear. There is an outer lighter and

Fig. 356.—Diagrammatic representation of the blood-supply and course of the uriniferous tubule: *J*, Interlobular blood-vessels derived from arches between cortex and medulla; *G*, glomeruli; *C*, proximal convoluted tubule; *D* and *A*, descending and ascending limbs of the loop of Henle; *CT*, collecting tubule; *P*, papilla and pelvis of the kidney. (Burton-Opitz.)

more solid portion called the *cortex*. In this portion lie the glomeruli and convoluted tubules. Internal to the cortex is the *medulla* of the kidney, made up of pyramid-shaped structures with radial striations coverging toward the pelvis of the kidney.

The pyramids and their striations are caused by the large number of collecting tubules draining the cortical portions. The chief vessels of distribution in the kidney pass at the margin or even within the pyramids; the tree-like arrangement of the capillaries with their glomeruli (Fig. 356) constitute the most interesting structure.

The openings of the papillæ provide for the flow of the urinary secretion into the channel of elimination. The upper end of the ureter is dilated into a basin-like cavity, the pelvis of the kidney.

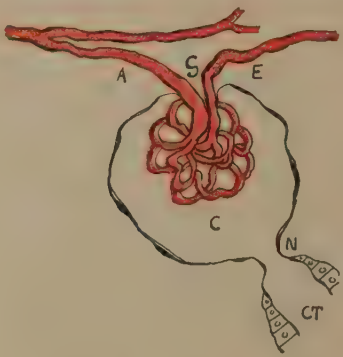

Fig. 357.—Glomerulus with the beginning segment of the uriniferous tubule: *G*, Glomerulus; *A* and *E*, afferent and efferent blood-vessels; *C*, capsule of Bowman; *N*, neck of uriniferous tubule; *CT*, proximal convoluted tubule. (Burton-Opitz.)

The pelvis has several divisions, called *calices*. Each pointed pyramid opens into a calix provided for it.

Vessels and Nerves of the Kidney.—In the pronephros and mesonephros the capillaries of the tubules are derived from the aorta; in the kidney a similar arrangement holds, and these two organs receive their vascular supply by the left and right renal arteries (Fig. 289). On entering the hilum of the kidney each renal artery breaks up into numerous branches to form more or less complete arches between the cortex and medulla. From these arches branches pass upward and downward (Fig. 356) to supply the structures of the organ. The venous return follows the arterial distribution and leaves the hilum of the kidney by

the renal veins that open into the inferior vena cava. The left renal vein receives from below as a tributary the left spermatic vein. The nerves to the kidney are derived from the solar and aortic plexuses of the autonomic system and from the last splanchnic nerve. These fibers are distributed freely to the muscular walls of the blood-vessels of the kidneys, making possible an effective control of the renal circulation. Figure 359 illustrates the intricate network of vessels in the kidney.

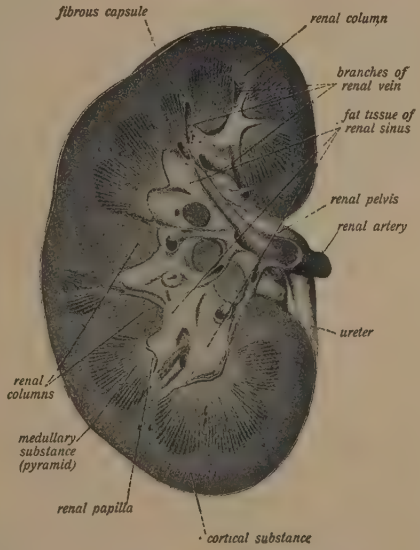

Fig. 358.—The kidney with its fibrous capsule, divided by a vertical section (Sobotta and McMurrich).

The **ureters** are the excretory ducts of the kidneys (Fig. 360). The pelvis, or upper portion of the ureter, has been described. The duct itself is about 25 to 30 cm. (10–12 inches) long and from 4 to 5 mm. in diameter, although at the entrance to the bladder, at the crossing of the iliac vessels, and at about 5 cm. (2 inches) below the hilum there are usually three constrictions which may reduce the diameter to 3 mm. The wall of the ureter has three coats or layers: an inner or mucous coat continuous with that of

the ureteral pelvis above and the bladder below, a middle or muscular coat arranged in two layers of longitudinal and circular fibers, and an outer or fibrous coat which carries the blood-vessels and nerves with which the tube is supplied.

The **bladder** is a hollow musculomembranous organ lying in the bony pelvis behind the symphysis pubis, in front of the rectum in



I II

Fig. 359.—Circulation in the kidney: I. Roentgenogram of the arterial distribution in a sheep's kidney made with a sodium bromid suspension of barium sulphate. II. Glomeruli with their efferent capillaries, as shown in a fine celluloid injection: Terminal portion of an arculate artery (*A*) breaking up into interlobular branches bearing clusters of glomeruli. The efferent glomeruli capillaries of cortical type (*B*) as well as those of medullary type (arteriolæ rectæ) (*C*) are clearly demonstrated (Hinman, Morison, and Lee-Brown).

the male, and in front of the anterior wall of the vagina and the neck of the uterus in the female. The capacity of the organ is variable, and it is proper to speak of its physiologic capacity and not of its anatomic capacity. The capacity of the adult bladder may be said to vary from 175 to 250 c.c. (6-9 fl. oz.) to 700 c.c. (24 fl. oz.), the latter figure representing the maximum

for the normal. In distention the bladder assumes an ovoid shape (Fig. 360) and when completely empty its walls are in contact.

The wall of the bladder has four coats: (1) An inner or mucous coat is continuous with that of the ureters and urethra. This coat is thrown into folds or *rugæ* when the organ is empty. (2) Beneath the mucous coat is one of loose areolar tissue permitting freedom of movement between the mucous and mus-

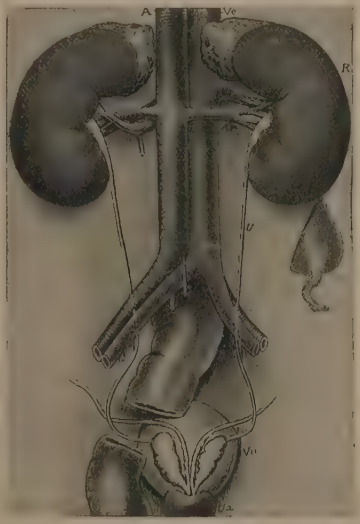

Fig. 360.—The kidneys, ureters, bladder, and their vessels viewed from behind: *R*, Right kidney; *U*, ureter; *A*, aorta; *Ar* right renal artery; *Ve*, vena cava inferior; *Vr*, right renal vein; *Vu*, bladder; *Ua*, commencement of urethra. (Campbell.)

cular layers so essential in an organ subject to such marked change in shape and size. (3) The muscular coat has three layers of muscular tissue arranged in an inner longitudinal, a middle circular, and an outer longitudinal. The circular fibers are especially well developed around the base of the bladder, affording a sphincter at the aperture into the urethra. (4) The fourth and final coat is of peritoneum which is reflected from the anterior abdominal wall on to the upper part of the organ, and in

the male swings from the bladder to the rectum and posterior aspect of the pelvic cavity. In the female the posterior reflection passes upward over the body of the uterus, forming the *vesico-uterine ligament.*

The **urethra** in the female is a narrow musculomembranous canal extending from the bladder to the vulva (page 468). It is about 4 cm. ($\frac{1}{2}$ inches) long. Its inner lining is of mucous membrane which is continuous with that of the bladder. A muscular layer surrounding a middle coat of loose areolar tissue containing a network of veins forms the wall of the passage. The short distance of the urethra in the female from the vulva accounts for the readiness with which infection may pass from the outside to the bladder. Cystitis (inflammation of the bladder) not infrequently occurs.

The urethra in the male is much longer and serves not only as a urinary canal but also as an important part of the seminal tract. Its length is about 20 cm. (8 inches). Passing from the bladder it traverses the prostate (page 472) forming the prostatic portion. The second part is the membranous urethra about 12 mm. ($\frac{1}{2}$ inch) in length. This becomes continuous with the third and last portion, the penile or spongy portion of the urethra.

How the Kidneys Secrete Urine.—The anatomy of the kidneys shows a liberal supply of blood, particularly to Bowman's capsule and the convoluted tubules. The pressure in the capillaries of the glomerulus is about 40 mm. Hg., while the pressure in Bowman's capsule is much less than that, probably at zero. Although the mechanical conditions are favorable for filtration of the waste products from the blood, it is known from numerous experiments that the removal of waste from the blood is due not only to filtration, diffusion, and osmosis, but very definitely also to specific secretory powers of the uriniferous tubule. Instead of it being a simple process it is exceedingly complex.[2] The water and inorganic salts of the urine are removed from the blood by the glomerulus; the organic constituents are taken out by the convoluted tubules.

When the function of the kidneys is impaired the excretory capacity of the skin is utilized in remedial measures that assist the elimination of waste.

The Composition of the Urine.—The kidneys secrete urine, a clear, amber-colored fluid with a normal specific gravity of 1.020. Its reaction is slightly acid, caused by the presence of

acid sodium phosphate. On standing it loses its transparency, becomes cloudy, and has a strong ammoniacal odor. This change is due to the decomposition of urea with the production of ammonium carbonate.

The composition of the normal urine shows five chief divisions:

1. *Water* forms the fluid portion of the urine and constitutes about 95 per cent. Its relative amount varies, due to the amount of water consumed, the temperature, and the humidity of the air. Normally the tissues of the body keep a certain concentration, and the excess of water taken in food and drink is continually removed by the kidneys.

2. *Inorganic substances* are sodium chlorid, and the sulphates and phosphates of sodium, potassium, calcium, and magnesium. These salts are derived from food that has not been utilized by the tissues, for example, sodium chlorid, or they are the products themselves of chemical activity in the cells, for example, the sulphates and phosphates.

3. *Organic substances* exist mainly as urea, although there are usually present creatin and uric acid. Urea is a waste substance formed in the liver from the end-products of protein metabolism. It comes mainly from the nitrogenous portion of the protein molecule of ingested food although some may be produced from tissue proteins. There are many differences of opinion regarding protein metabolism.* Excessive eating of protein food increases the urea in the urine. Other compounds are creatinin, hippuric acid, and aromatic oxyacids, *e. g.*, phenol, indoxyl, and skatoxyl.

The urine may also show among its organic constituents the waste substances from the nuclei of cells, known as nucleoprotein. Nucleoprotein gives rise to a group of substances, the *purin bases*, *e. g.*, uric acid, xanthin, hypoxanthin. These are eliminated by the kidney with difficulty.

Normally the urine contains minute traces of sugar and albumin.† When sugar is present in appreciable amounts it means either a temporary glycosuria due to excessive ingestion of sugar, or diabetes. In the latter the disease is not of the kidneys, but rather it represents an inability of the body to adequately burn

* Cathcart, E. P.: Protein Metabolism Physiological Reviews, April, 1925, pp. 225–243.

† Mathews (Physiological Chemistry, p. 938) says: "Normal urine does not contain protein." Wood, F. C. (Chemical and Microscopical Diagnosis, p. 495) says, however: "Normal urine contains small traces of serum albumin."

sugar due to disturbance of the pancreatic secretion or some other deficiency in the body. A temporary albuminuria may show after vigorous physical exercise or during adolescence. Usually, however, albumin in the urine in appreciable amounts means disease of the kidneys.

The urine contains indican if there is marked putrefaction of protein food in the large intestine.

4. *Coloring materials* are derived from the bile-pigments. The presence of bile in the blood in instances of obstruction to the flow of bile from the liver may be determined by its detection in the urine.

5. *Gases* -traces of carbon dioxid, nitrogen, and oxygen -are present in the urine.

6. *Abnormal Constituents.*—In diabetes sugar will appear in the urine; in certain forms of nephritis albumin will escape from the blood and also show in the urine. In inflammatory conditions in the kidney exudates from the kidney tubules will appear in the urine. These exudates are formed in the shape of the tubules, constituting *casts*. Their appearance in the urine is a sign of disturbance of the kidney epithelium. The casts are classified according to their origin, and the following varieties are recognized: hyaline, granular, fatty, pus, blood, and epithelial.

The mineral salts in the urine may precipitate in such large masses as to form stones, called *calculi*. Excessive acidity and alkalinity in the urine, deficient water content, or excessive amounts of the salt constituents in the urine favor calculus formation.

Pus or *blood* may be present. It may come from the kidney, bladder, or urethra.

Micturition.—The ureters are constantly conveying urine to the bladder as a result of a peristaltic wave traversing these tubes. When the bladder has filled with about 250 c.c. of urine nerve endings are stimulated and the bladder walls contract, forcing the urine out through the urethra. This is known as *micturition* or *voiding*. Variations from the normal in micturition occur.

Enuresis.—In the infant voiding occurs whenever the bladder is distended sufficiently to arouse a reflex stimulation. As the child grows older he is taught to inhibit the normal stimulus and to select the proper time and place for the act. In some children this education of the reflex is learned early; in others it is acquired late and with great difficulty. The child should gain control of

the act of micturition during the day by the second year, but involuntary micturition may occur up to the age of six or seven. If the act occurs at night in any regular fashion after the age of three it is known as *enuresis*. This may be due to improper training, irritation of the bladder, or to a nervous instability in the child.[3]

Incontinence of Urine.—In the adult voiding may take place in involuntary fashion. This occurs particularly in disease of the nervous system.

Retention of Urine.—Inability to void may be due to swelling of the urethra causing obstruction, nervous contraction of the urethra in highly emotional states, or to semicomatose conditions.

Suppression of the urine relates to the kidneys and not to the bladder. It represents a failure of the kidneys to secrete urine, and occurs in instances of acute inflammation of the kidneys.

Quantity of Urine.—The amount of urine excreted in twenty-four hours varies with the water ingested, the temperature and humidity, the factors influencing blood-pressure, osmotic pressure of the blood, and the foods or drugs taken. Feldman* quotes Schanjawski, who gives the number of micturitions and quantity voided as follows:

Age.	Number of micturitions, average.	Average quantity voided at each micturition, c.c.
14–30 days	13	34
1– 3 months	14	31
3– 6 months	20	31
6–12 months	16	44
1– 2 years	12	60
2– 3 years	10	88
3– 4 years	9	92
4– 5 years	7.5	90
5– 6 years	9.3	104
6– 7 years	7.1	154
7– 8 years	7.8	146
8– 9 years	7	191
9–10 years	7.3	262
10–11 years	7	248
11–12 years	7.5	224
12–13 years	8.3	262

Modifying Kidney Action.—The secretion of urine may be changed in numerous ways. The effect of ingestion of water, of temperature, and humidity have been mentioned. Increased kidney action is noted as follows:

* Feldman, W. M.: Antenatal and Postnatal Child Physiology, Longmans, Green & Co., New York, 1920, p. 508.

1. Increased blood-pressure. An increase in the flow of blood through the kidney increases the secretion of urine. Medically this is secured by the use of drugs, *e. g.*, digitalis or caffein. The diuretic effect of caffein may be noticed after drinking coffee.

2. Lowered osmotic pressure of the blood. Through the osmotic action of certain salts—*e. g.*, sodium sulphate, the acetates, citrates, and tartrates—water is drawn from the tissues and the quantity of blood is increased. Hence, the urine is increased.

3. Agents acting on the kidney. Various drugs are used to increase the action of the kidney cells, *e. g.*, caffein, calomel.

PRACTICAL EXERCISES

1. Examine a specimen of normal, fresh urine for color, transparency, and odor. Allow it to stand for twenty-four hours and note changes.

2. Test the specific gravity of a specimen.

3. To a specimen of normal urine add some glucose solution. Perform the following test: Fill a test-tube one-quarter full and add 5 c.c. of the Fehling copper solution and 5 c.c. of the Fehling alkaline solution. Boil for two minutes. Repeat the experiment with normal urine without the addition of glucose.

4. The urine may be tested for albumin, as follows: Place urine in narrow test-tube, and heat upper part to boiling. Add 1 to 2 drops of strong nitric acid. If no precipitate appears or if precipitate disappears on shaking, add 2 or 3 more drops of the acid. Albumin will show as a whitish flocculent precipitate. Be sure to add acid in excess if white precipitate forms at first. This may be calcium phosphate.

5. The urine may be tested for indoxyl (an aromatic body increased in certain putrefactive states in the intestine) by Obermayer's reagent.*

QUESTIONS

1. What facts in the comparative anatomy of the excretory system indicate a biologic relationship between man and the lower animals?

2. Why should a surgeon prefer the retroperitoneal route for an operation on the kidney?

3. Beginning at the glomerulus trace the course through the uriniferous tubule.

4. If a kidney stone (renal calculus) enters the ureter, what anatomic facts indicate that it might become lodged or would likely cause pain?

5. In addition to the kidneys what other organs serve to eliminate waste?

6. What waste products are difficult for the kidney to remove? What is their origin?

7. What is glycosuria? Albuminuria? Indicanuria? Hematuria?

8. In chronic disease of the kidneys the normal epithelium is in part destroyed and replaced with connective-tissue cells. For a "kidney remedy" to cure such disease what would it have to accomplish?

9. What are casts? Name the different varieties.

10. Explain the effect of exercise, temperature, humidity, and ingestion of water upon the secretion of urine.

* See Wood, F. C.: Chemical and Microscopical Diagnosis, D. Appleton Co., New York, 1911, p. 447.

REFERENCES FOR FURTHER STUDY

1. Wiedersheim, R.: Comparative Anatomy of Vertebrates, Macmillan Co., New York, 1907, pp. 441–496.
2. Burton-Opitz, R.: Text-book of Physiology, W. B. Saunders Co., Philadelphia, 1920, pp. 1064–1088.
3. Guthrie, L. G.: Functional Nervous Disorders in Childhood, Oxford Medical Publications, London, 1909, pp. 155–161.

CHAPTER XVII

THE REPRODUCTIVE SYSTEM

I. Development of the Reproductive System.
II. The Female Generative Organs:
  1. General Arrangement of the Internal Generative Organs.
  2. The Ovaries:
    Internal Structure of the Ovary.
    Corpus Luteum.
  3. The Fallopian Tubes.
  4. The Uterus:
    Internal Structure of the Uterus.
    Position and Ligaments of the Uterus.
  5. The Vagina.
  6. The Vulva.
III. Menstruation:
  1. Significance of Menstruation.
  2. Menstrual Disturbances.
IV. Menopause.
V. The Mammary Glands.
VI. The Male Generative Organs.

Development of the Reproductive System.—In the development of the pronephros and mesonephros the genital gland* is in close relationship with the tubules of these early organs. At this time there is no sex differentiation, but with modification of the genital structures and the transformation of the nephric elements the characteristics of the male and the female appear. While these changes are occurring within the abdomen differentiation is taking place in the tissues that give rise to the external genitalia, but up until the beginning of the third month there is no distinguishing indication of sex.

The common origin of the male and female organs of generation is indicated (Fig. 354) in the table on page 461.

* The appearance of the genital gland in the early weeks of embryonic life and its development from the cells laid down at that time is a significant fact for the student of heredity. The individual that matures from the embryo possesses the sex elements which will, on union with the sex elements of the opposite sex, determine the nature and possibilities of the offspring.

Indifferent embryonic type.	Male.	Female.
Genital gland	Testis	Ovary
Mesonephros	Epididymis	Epoöphoron
	Paradidymis	Paroöphoron
Mesonephric duct	Vas deferens	Disappears*
Müllerian duct	Appendix of testis	Fallopian tubes, uterus, and vagina

The external parts show a similar homology.

The Female Generative Organs.—The female organs of generation are divided into two groups: an internal, comprising ovaries, fallopian tubes, uterus, and vagina, and an external,

Fig. 361.—Sagittal section of the female pelvis, showing the relation of the pelvic viscera (Campbell).

often grouped under the name *vulva*, comprising mons veneris, labia, clitoris, hymen, and urethral and vulvovaginal glands.

General Arrangement of the Internal Generative Organs.—Before describing the generative organs of the female an explanation of the general plan of arrangement will be made. In Fig. 361 the *uterus* appears in its position behind the bladder and at the upper end of the *vagina*. The peritoneum of the anterior abdominal wall is carried over the bladder and then reflected on to the anterior wall of the uterus, continuing over that organ to pass

* At times this structure does not completely disappear in the female and persists as Gärtner's duct.

over its posterior surface and then on to the rectum. The *fallopian tubes* are attached to the upper part of the uterus and extend laterally toward the sides of the pelvic cavity. Clearly, therefore, this fold of peritoneum that covers the uterus must pass over the tubes, and this arrangement is shown in Fig. 362. The two layers of peritoneum thus formed by the covering over the tubes comprise the broad ligament of the uterus, and is a structure of considerable importance. To the posterior layer of the broad ligament the ovary is attached.

The *ovaries* are the genital glands in the female within which are developed and given off the maternal sex cells. The ovaries are ovoid in shape and measure about 37 mm. ($1\frac{1}{2}$ inches) in length, 18 mm. ($\frac{3}{4}$ inch) in width, and 8 mm. in thickness. They are

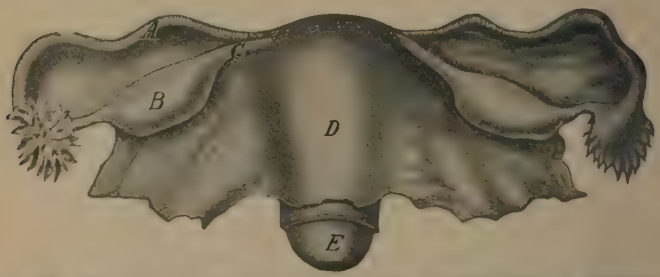

Fig. 362.—The broad ligament and contents, posterior view: *A*, Fallopian tube; *B*, ovary; *C*, ovarian ligament; *D*, uterus; *E*, cervix. (Campbell.)

attached at their anterior margin by a short thick band of tissue, the *mesovarium*,* to the posterior layer of the broad ligament, near the tubal extremity. They are held in place (Fig. 363) by three peritoneal folds that act as ligaments: (1) the *suspensory* ligament, really a continuation of the broad ligament, running to the sides of the pelvic cavity; (2) the *ovarian* ligament, a cord-like structure† within the posterior layer of the broad ligament, connecting the ovary with the uterus, and (3) the *mesovarium*.

Internal Structure of the Ovary: Examination of the substance of the ovary shows a number of vesicles called *graafian follicles*, embedded in a soft connective tissue composed of white

* Lying in the mesovarium are the epoöphoron and paroöphoron. They consist of a number of epithelial-lined closed tubes. These structures may give rise to cysts or other tumors.

† The ovarian ligament is a remnant of the mesonephros.

and yellow fibers (Fig. 364). Covering the ovary is a layer of epithelial cells called the germinal epithelium. From this layer tubes or columns of cells grow downward into the connective tissue forming the graafian follicles. It is estimated that about 36,000 follicles are formed by birth, although none mature until puberty. Lode calculated that during the reproductive period only 400 produced *ova.* Development of the graafian follicles begins with puberty and continues during the whole of the child-bearing period. In the undeveloped stage they are seen to consist of an outer coat of fibrous tissue within which is a layer of epithelial cells. At one side of the follicle surrounded by many

Fig. 363.—Female pelvic organs *in situ,* seen from above (Bardeleben).

epithelial cells (Fig. 364) is the *ovum* (Fig. 17), the germinal cell of the female. Further growth of the follicle with accompanying development of the ovum brings the follicle to the surface of the ovary, from which it ruptures when fully matured. The ovum now set free in the abdominal cavity passes into the fallopian tube and begins its descent toward the uterus. This process of development, maturation, and rupture is ovulation. It occurs normally every twenty-eight days from puberty to the menopause. The empty vesicle from which the ovum has escaped becomes filled at first with a blood-clot. Then the blood-clot is absorbed and its place is taken by cells having a yellow pigment. The structure so formed is called the *corpus luteum.*

Corpus Luteum: The size and character of this structure is somewhat variable. Some anatomists and physiologists assert

that it increases in size and remains large for six months if fertilization has occurred, but Piersol states that not infrequently large corpora lutea are found in virgins. Whatever its course, it seems to be the consensus of opinion that the corpus plays a part in the formation of an internal secretion to the body. The purpose or nature of this secretion is discussed in Chapter XVIII.

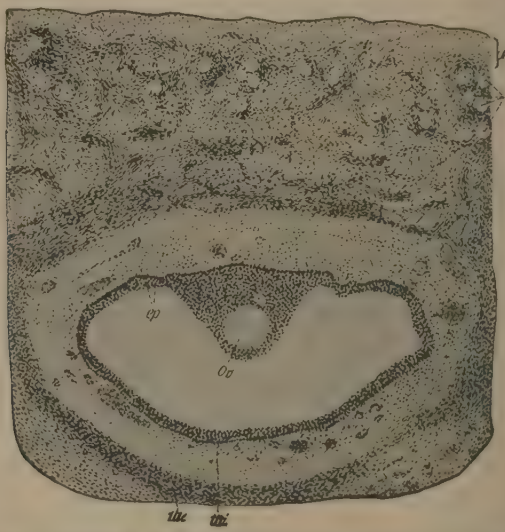

Fig. 364.—Transverse section through the cortex of a human ovary; × 50: *A*, Germinal epithelium; *ep*, follicular epithelium; *fp*, primordial follicles; *ov*, ovum; *the*, external sheath of the follicle; *thi*, internal sheath of the follicle with blood-vessels. (Sobotta and Huber, Atlas and Epitome of Human Histology.)

The *fallopian tubes* represent the upper ends of the müllerian ducts. The lower ends of the ducts fusing to produce the uterus, it is to be expected that the lumen of the tubes would be continuous with the uterus. Such is the case. The wall of the tube has a mucous, muscular, and serous layer. The mucous membrane covered with cilia is continuous with that of the uterus at the inner end and fuses with the peritoneum at its outer extremity. The muscular layer is not very thick and shows both circular and longitudinal arrangement of its fibers. The serous

layer is of peritoneum. The tubes, about 10 cm. (4 inches) long, lie between the two layers of the peritoneum, called in this area the broad ligament. At their extremities they present fringe-like margins, called *fimbriæ* (Fig. 362).

The fimbriated extremity of the tube is very movable, and at the time of rupture of the graafian follicle may bring its finger-like processess over the ovary to facilitate the entrance of the ovum into the tube. Just what the mechanism is that induces the ovum to enter the tube is a matter of speculation. Perhaps the cilia of the mucous membrane set up a current that tends to draw the ovum into the tube. If the ovum does not enter the tube it remains in the abdominal cavity to disintegrate and be absorbed.

The *uterus* is a hollow pear-shaped organ formed by the fusion of the lower ends of the müllerian ducts. At times the fusion is not complete and a partition may exist in the body of the uterus, or if the lack of fusion is more marked, two separate and distinct uteri may occur. This is not common. Extreme deformity may arise in which two vaginæ as well as two rudimentary uteri result from the imperfect development.

In the virgin state the organ lies in the pelvic cavity riding between the bladder and the rectum. It is about 7 cm. (3 inches) long, 5 cm. (2 inches) wide, and 2.5 cm. (1 inch) thick. During pregnancy it increases in size enormously, attaining a length of 55 cm. (14 inches). From an organ weighing ordinarily about 45 grams ($1\frac{1}{2}$ ounces) with a capacity of about 3 to 5 c.c. it increases to a weight of about 1 kilogram (2 pounds) and a capacity of 5000 c.c. or more. This great change in pregnancy depends upon the marked hypertrophy of the muscular coat of the organ.

The upper part of the uterus above the entrance of the tubes is called the *fundus;* the narrow constricted portion below, the *cervix*, part of which extends into the vagina, presenting the *external os* of the cervix. Between the cervix and fundus is the *body* of the uterus.

Internal Structure of the Uterus: The cavity of the uterus is triangular in shape, with the apex of the triangle pointed downward. This cavity communicates with the fallopian tubes at the upper part and with the vagina below. It is lined with mucous membrane which is continuous with that of the tubes and vagina. This membrane becomes ciliated near the orifices and shows numerous tube-like glands, the *uterine glands*. They are of small

size in the unimpregnated uterus, but enlarged and tortuous in the fecund organ. The mucous membrane in the upper part of the cervix is thrown into numerous folds and contains cilia and numerous glands that secrete a clear, viscid, alkaline mucus. The muscular layer of the uterus is the most prominent part. The fibers are of involuntary musculature and run in all directions. Between them are numerous blood-vessels, lymphatics, and nerves.

Position and Ligaments of the Uterus: The muscles of the pelvic floor (page 200) close the outlet of the pelvis (page 145). Upon this support the organs of the pelvic cavity rest and ride, supported in part by peritoneal bands that attach them to the pelvic walls. It is clear, therefore, that the uterus is not attached to the skeleton, but rides on a support furnished by more resilient

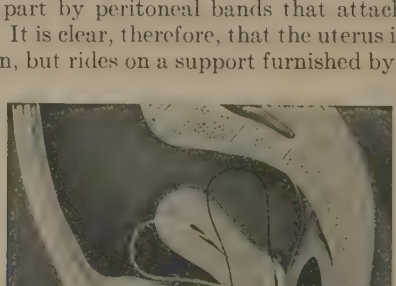

Fig. 365.—Normal position of the uterus: White outline, anteversion; black outline, retroversion. (Campbell.)

tissues. It is so freely movable that a full bladder pushes it backward and a distended rectum compresses it forward. In the supine position it will take a dorsal position, while in the prone position it will incline forward. A side reclining posture will permit it to dip to the same side. Although normally very movable, it has its range beyond which abnormalities occur. Normally the fundus will be inclined forward and the external os of the cervix directed downward and backward (Fig. 365). Abnormal variations of position are those in which the organ is turned too far forward, *anteversion;* in which the fundus is turned

backward, *retroversion;* and in which the organ descends, *prolapse,* due to weakness of the pelvic supports.

In addition to the support given by the muscles of the pelvic floor, three pairs of ligaments and two unpaired supports moor the organ to its position in the pelvic cavity: (1) The *broad* ligaments, mentioned several times in connection with tubes and ovaries, are broad folds of peritoneum enveloping uterus and tubes. These ligaments have two layers, the anterior one covering the front wall of the uterus, and the posterior one the back wall. Between these two leaves are numerous involuntary muscle-fibers derived from the uterus which assist in supporting that organ. (2) The *round* ligaments are remnants of the mesonephros and persist as two rounded fibrous cords between the two leaves of the broad ligament. They extend from the body of the uterus a little below the fallopian tubes toward the anterior abdominal wall and enter the internal abdominal ring. Passing through the inguinal canal they end in the tissues of the labia majora and mons veneris. They are homologous structures with the spermatic cord of the male. (3) The *uterosacral* ligaments are bands of connective tissue and muscle-fibers covered with peritoneum that run from the cervix and lower part of the body of the uterus backward to the sacrum. They pass on either side of the rectum. (4) The *anterior* ligament or *utero-vesical* is the anterior fold of peritoneum that covers the bladder and is reflected on to the uterus. (5) The *posterior* or *recto-vaginal* is the continuation of the same peritoneum on the posterior aspect of the organ. The cup-like cavity formed between the uterus and rectum is known as the culdesac of Douglas.

The *vagina* is a musculomembranous canal extending from the cervix to the vulva (Fig. 361). When collapsed it is flattened from before backward, with its anterior and posterior walls in contact leaving small recesses at the sides. The posterior wall is about $3\frac{1}{2}$ inches long; the anterior is shorter by $\frac{1}{2}$ inch. The walls of the vagina are composed of three layers—a mucous, muscular, and fibrous. The mucous layer is formed in curved transverse folds, *vaginal rugæ,* which are rather prominent in virgins, but which gradually disappear after repeated births. The muscular layer is especially well marked at the orifice; it increases throughout the canal during pregnancy. The fibrous layer invests the canal on its outer aspect and is continuous with the tissues of the urethral covering and the rectal investment.

The *vulva* comprises the external genitalia of the female. The *mons veneris* is an eminence in front of the symphysis pubis, composed of fat and connective tissue and, after puberty, covered with hair. The *labia majora* are two longitudinal lip-like folds of skin joined together above at the mons veneris and separated below toward the perineum.*

The *labia minora* are two small folds of epithelial covered tissue lying between the labia majora. Above they come together in the prepuce of the *clitoris* (Fig. 366), below they fuse with the hymen. The clitoris is homologous with the penis of the male. It is richly supplied with blood-vessels and nerves, and is covered with a fold of skin, the prepuce. The *hymen* is a fold of mucous membrane surrounding the vaginal orifice. It may extend entirely across and close the aperture, but this condition, called imperforate hymen, is not common. The *glands of Bartholin* are two round glands that open near the vulval orifice between the hymen and the labia minora; the *urethral glands* are small groups of tubular structures situated in the fibrous coat of the urethra. They open by ducts below and on either side of the urethral papilla.

Fig. 366.—Diagram of female external genitals (Dickinson).

Vessels and Nerves of the Generative Organs: The arteries of the uterus are the uterine from the internal iliac and the ovarian from the aorta. The vessels reach their destination by passing between the two leaves of the broad ligament. Veins follow a similar course. Autonomic nerve-fibers coming from the hypogastric plexus supply the various structures. The nerves to the ovary come from the renal plexus. The vulva is supplied by numerous vessels and a distinct plexus of veins enclosing the vaginal orifice. These

* The term "perineum" is applied to that part of the body between the vaginal orifice and anus. It really is part of the pelvic floor, as it is composed of muscles, connective tissue, and skin.

extend along the walls of the vagina. Most of the innervation is by autonomic fibers from the hypogastric plexus, but there are some fibers from the sacral nerves of the cerebrospinal system.

Menstruation.—At regular intervals during health, except in pregnancy and lactation, there is a discharge of blood, mucus, and epithelial cells from the uterine cavity. The duration of the discharge is four to five days on the average, although some women flow only three days, others six and seven. The amount of blood lost is about 4 to 6 ounces (120–180 c.c.). While regular in its occurrence, in some persons there is considerable irregularity. This is liable to be true during puberty until the function is well established. Eighty-six per cent. of cases are regular. The period usually comes every twenty-eight days. Next in frequency is the thirty-day type, then the twenty-day type, and least frequent is the irregular type.

Significance of Menstruation.—Menstruation is the preparation of the uterus for implantation of the ovum. It marks the development from girlhood to womanhood, and hence the ability to conceive. The age at which this change occurs varies with race, climate, heredity, and environment, whether urban or rural. The average age is between thirteen and fourteen years, although as early as ten and as late as seventeen may occur. Menstruation ceases at about the forty-fifth year.

Whether ovulation precedes or follows menstruation is not definitely known. One view, quite generally held today, maintains that menstruation is started by an internal secretion derived from the corpus luteum of the ovary. This view gains support from the fact that removal of the ovaries results in cessation of menstruation.

During pregnancy and, in most women, during lactation menstruation ceases. It may stop also during wasting diseases, such as pulmonary tuberculosis. That it is subject to nervous influence is shown in the amenorrhea (absence of menses) that occurs when there is fear of pregnancy that is not desired. Change in climate frequently causes a variation of the period until adjustment has been made to the new environment.

Menstrual Disturbances.—Menstruation is a natural physiologic function. This function may become deranged, but the disturbances at this period should be grouped under two headings, in which the physiologic disturbances are viewed as normal and natural.

Physiologic Disturbances: Several days before the flow there is usually a feeling of fatigue with frequently headache and some pain in the lumbar region of the spine. The nervous system is more irritable, the breasts are quite sensitive, and externally around the eyes a dark discoloration may appear. On the first day of the flow there is considerable congestion of the uterus with some distress.

Pathologic Disturbances: Marked irregularity, prolonged flow, and marked pain during the menstrual period are abnormal. Frequently there is great improvement in all the symptoms after the first pregnancy.

Fig. 367.—Sagittal section of breast: *A*, Gland substance; *B*, fatty tissue; *C*, lactiferous ducts. (Campbell.)

Menopause.—As a rule the menses cease to occur at forty-five, although instances much earlier and later are recorded. This change is sometimes called the "climacteric" because for the woman the period is quite critical. There are marked disturbances in the whole nervous system in addition to structural changes in the breasts, ovaries, uterus, and tubes.

The **mammary glands** are present in both sexes. Histologically, they are cutaneous organs, but physiologically their function entitles them to consideration in a description of the reproductive system of the female. The mammary glands or breasts are variable structures in size. They may appear as small swellings on either side of the sternum above the pectoralis major muscles. Each breast consists of twenty or more individual or separate glands, that open by independent ducts upon the surface of the *nipple*. The glandular tissue of the breast is arranged in lobes and is divided into numerous portions, the *lobules*, which, in turn, are composed of the secretory cells arranged in alveoli. The glandular elements (Fig. 367) are embedded in a varying amount of areolar and fatty tissue. The size of the breast is usually dependent upon the amount of fat present, and is in no way indicative of the func-

tional power of the gland. The breast is supplied by branches of the internal mammary artery which is a branch of the subclavian. The veins follow the arteries. The lymphatics of the breast are especially numerous and course mainly toward the axillary space. The gland is supplied by nerves from the thoracic portion of the autonomic system.

The breasts begin their development at puberty.* They are influenced by an internal secretion of the ovaries, for if the ovaries are removed before puberty the breasts do not develop, and if

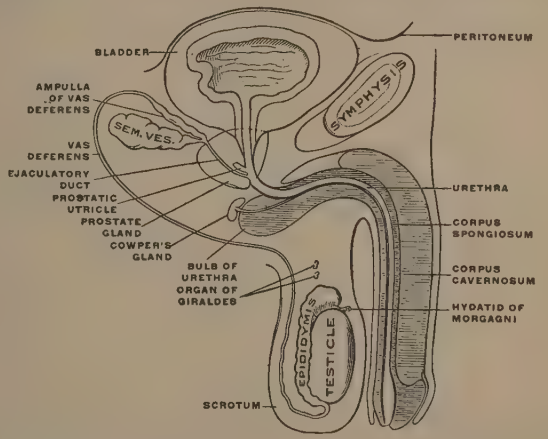

Fig. 368.—Diagrammatic representation of the male reproduction organs and their relations to the bladder and the urethra, lateral view (Toldt).

removed afterward the breasts atrophy. The increase in size of the mammary glands in pregnancy is due to a secretion coming from the fetus, as shown by Starling. The activity of the gland during the period of lactation is closely associated with nervous conditions indicating the relation of the autonomic system in the activity of this organ.

The Male Generative Organs.—These organs develop from the indifferent sex structures as given on page 461. There are the following chief parts (Fig. 368): testes, vas deferens, seminal vesicles, ejaculatory ducts, scrotum, spermatic cord, penis, urethra, prostate gland, and Cowper's gland.

* The increase in size of the breasts is only one of the profound changes that occur in adolescence.[1]

The *testes* are the male development of the indifferent genital glands. They migrate from their site of origin in the lumbar region and have passed through the abdominal wall usually by birth. Normally, therefore, they lie in the *scrotum* attached to the *spermatic cord* which carries the vas deferens, arteries, veins, lymphatics, and nerves. Surmounting the testis is the *epididymis*, a very much coiled tube that makes the connection between testis and vas deferens. The *vas deferens* is the canal leading from the epididymis into the abdominal cavity. It accompanies the spermatic cord, comprising part of the latter's structure. Leading from the scrotum it passes upward to the external inguinal opening, and on entering this aperture traverses the length of the inguinal canal to emerge at the internal orifice. From this point it swings inward and backward to reach the sides of the bladder along which it passes to terminate at the *seminal vesicles*. The seminal vesicles are two convoluted pouches lying on the outer side of each vas between the bladder and rectum. Their lower ends unite with the vas on each side to form the *ejaculatory ducts*.

Fig. 369.—Diagram of the flagellate spermatozoön (from Wilson, The Cell in Development and Inheritance).

Situated at the base of the bladder and completely surrounding the first portion of the urethra as it leads from the bladder is a mass of fibrous and muscular tissue, the *prostate*. This organ contains numerous glands that produce the prostatic fluid, an important part of the seminal secretion. The two ejaculatory ducts pass between the lobes of the gland to enter the urethra, which serves from this point outward as the seminal and urinary

canal. This canal proceeds forward in the tissues of the penis, and opens at the meatus on the under surface of the *glans* of the *penis*. The glans of the penis is a bulk-like extremity covered with mucous membrane over which is a reflection of skin called the *prepuce*. Cowper's glands, homologues of the glands of Bartholin, are two small bodies alongside the urethra, into which they empty. They give a secretion that forms part of the seminal fluid. The *seminal fluid* or *semen* is derived from the testes, prostate, and Cowper's glands. The germinal elements, called *spermatozoa* (Fig. 369), come from the testes, being continually secreted after puberty and stored in the seminal vesicles.

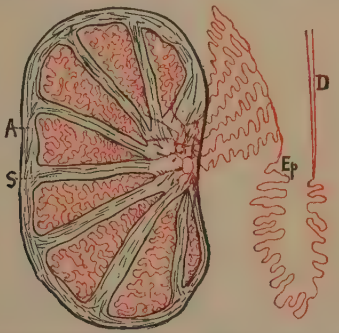

Fig. 370.—Diagram of testis showing tubules, epididymis, and vas deferens: *A*, tunic covering testis; *S*, partition dividing the gland; *Ep*, epididymis; *D*, vas deferens. (Burton-Opitz, "Physiology.")

Function of the Testes.—The testes produce the male reproductive cell and are analagous to the ovaries in the female. They are ovoid-shaped bodies enveloped by a fibrous tunic from which run partitions of fibrous tissue to divide the gland into compartments (Fig. 370). Within these areas are the reproductive cells arranged in tubules, known as *seminiferous tubules*. At puberty (about fifteen years in temperate climate) the tubules show the formation of large nucleated cells, the *spermatogonia*, into *spermatocytes*. The spermatocytes are larger cells with a more highly developed nucleus. From these arise the *spermatids*, which, in turn, become *spermatozoa*. This process is comparable to the maturation of the ovum (see page 36) and provides by these developmental changes for the essential reduction in the characteristic number of chromosomes.

With the formation of spermatozoa, their passage into the epidymis and vas deferens then occurs. In the latter tube they use their own motile power to reach the seminal vesicles, assisted somewhat by the peristaltic contraction of the vas.

The reproductive elements deposited in the vesicles are now ready to be discharged. In the discharge the seminal contents are joined by a secretion from the prostate and from Cowper's glands. An ejaculation may contain as many as 226,000,000 spermatozoa in one emission.

For description of the *interstitial* cells of the testes see the following chapter.

PRACTICAL EXERCISES

1. Dissect female cat or rabbit to expose the reproductive system. Note uterus, tubes, and ovaries. If pregnant cat can be secured, note the location of the fetuses. Explain the shape of the uterus as compared with the human.
2. Examine slides of the ovary showing graafian follicles.
3. A fertilized ovum may develop in the tube. This is called *ectopic gestation*. From your knowledge of anatomy and physiology what would be the danger of such occurrence?

QUESTIONS

1. Why may the female develop cysts or other tumors of the ovary?
2. Describe the ligamentous support of the uterus.
3. What is the corpus luteum?
4. What is the result on general health of total removal of the ovaries before the menopause?
5. What are anteversion, retroversion, and prolapse of the uterus?
6. What is the significance of menstruation? Where does it begin? When does it stop?
7. What is the menopause? How may it be produced artificially?
8. Enlargement or hypertrophy of the prostate not infrequently occurs in elderly men. What important structure would such condition compress? What would be the effect?

REFERENCES FOR FURTHER STUDY

1. Hall, G. S.: Adolescence, vol. i, D. Appleton & Co., New York, 1904, pp. 51–128.

CHAPTER XVIII

THE ENDOCRINE SYSTEM

I. The Nature of Internal Secretions.
II. The Organs of the Endocrine System.
III. The Thyroid.
IV. Function of the Thyroid.
V. The Parathyroids.
VI. Function of the Parathyroids.
VII. The Thymus.
VIII. Function of the Thymus.
IX. The Adrenals.
X. Function of the Adrenals.
XI. The Pituitary or Hypophysis.
XII. Function of the Pituitary.
XIII. The Germ Glands.
XIV. Function of the Germ Glands as Internal Secretory Organs.
XV. Other Organs.
The Pineal, Carotid, and Coccygeal Bodies.

The Nature of Internal Secretions.—Knowledge of secretions delivered to the blood and lymph has grown rapidly in recent years. Following the teaching of the *humoral theory*, in which four fluids of the body were considered as essential causes of life activities, there developed the notion of *nervous correlation*, in which the nervous system was supposed to play the rôle of correlating all the separate activities of the organism. While the nervous system is still considered as having important functions in correlation of parts, many of the activities of life are to be described today in terms of secretions produced by certain glands and distributed throughout the body via the blood and lymph channels.

Weil* defines an internal secretory gland as follows: "Glands conforming to a definite histologic type, with a structure peculiar to each gland; manufacturing specific chemical combinations and delivering these to the organism through the blood and lymph channels, producing by means of infinitesimal quantities of these specific substances certain definite effects upon the functions of other body cells, without furnishing material for cell building."

* Weil, A., The Internal Secretions (translated by J. Gutman). The Macmillan Co., New York, 1924, p. 12.

Claude Bernard first suggested the term "internal secretion." Other proposals have been made. Schaefer suggests *hormones* for those that accelerate activity, *chalones* for those that inhibit activity, and *autacoids* as the general term to include them both. Present usage favors the more indefinite term, *internal secretion.*

The Organs of the Endocrine System.—The organs* belonging to this group of structures that furnish an internal secretion to the body are the thyroid, parathyroids, thymus, adrenals, pituitary,

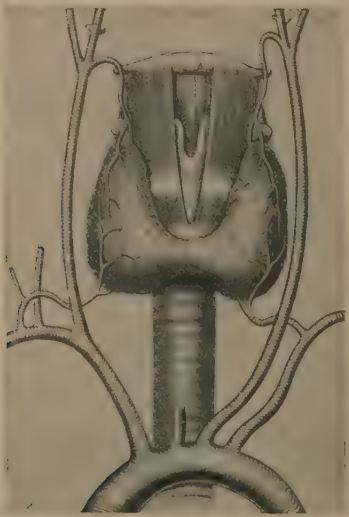

Fig. 371.—The arteries of the thyroid gland. Note the four arteries at the four angles of the gland. (Campbell.)

pineal gland, the pancreatic islands of Langerhans, testes, and ovaries. These glands (the last three give also an external secretion) instead of pouring their secretions into a canal or on to a surface, as is the common process in glandular activity, give their secretions directly into the blood. The significance of these secretions has only recently been appreciated and much of their physiology is as yet unknown.

The **thyroid gland** consists of two lateral lobes connected together with a narrow band of thyroid tissue called the *isthmus.*

* Gley also includes the liver, but glycogen given up by the liver is not a true internal secretion, since it furnishes building material for cells.

It lies in close relation to the anterior aspect of the trachea at its junction with the thyroid cartilage (Fig. 371). The lobes are broad below and taper to a point above. In a certain proportion of cases the isthmus is absent. Scattered along the front of the trachea as far down as the bronchi may be found small masses of thyroid tissue. These are called accessory thyroids.

The structure of the gland shows that a dense capsule of fibrous tissue invests the gland, from which partitions or septa lead into the body of the organ, dividing it into numerous lobules. The lobules are composed of epithelial cell masses corresponding to the acini of ordinary glands (Fig. 372). Within the acini there is the secretion of the epithelial cells, called *colloid.*[1] Apparently this material* is taken up by the lymphatic supply of the organ.

The vascular supply of the thyroid is peculiarly abundant. It comes from the external carotid and subclavian arteries.

The nerves are derived from the cervical portion of the autonomic.

Function of the Thyroid.—The thyroid gives a secretion into the blood that has profound effects upon growth and metabolism; it also acts co-operatively with other secretions. The active principle of the gland has been called *thyroxin* by Kendall, who isolated an acid-soluble, crystalline compound.

The thyroid influences growth. If the thyroid is removed in young dogs or other animals, retardation in growth occurs in a few weeks. Similar effects have been noted in children with congenital lack of the thyroid. Weil quotes the following tabulation:

GROWTH IN HEIGHT IN CONGENITAL LACK OF THYROID
(Kassowitz)

Age in years.	Height of myxedematous subject, cm.	Height of normal subject, cm.	Difference, cm.	Underheight, per cent.
$2\frac{1}{2}$	72.0	79.6	— 7.6	9.8
$4\frac{3}{4}$	80.5	98.0	—17.5	17.8
$5\frac{1}{4}$	82.0	101.0	—19.0	18.8
$7\frac{1}{2}$	83.0	114.0	—31.0	27.2
$10\frac{1}{2}$	91.5	130.0	—38.5	29.6
12	95.0	136.0	—41.0	30.1
20	116.0	166.0	—50.0	30.1

* Deficiency of the secretion causes *cretinism* in infancy and *myxedema* in adult life. Excessive secretion causes *exophthalmic goiter.* The thyroid function is closely connected with puberty and, in the female, with menstruation and pregnancy.

The relationship between congenital lack of thyroid and *cretinism* has been known. The value of thyroid extract in treatment of cretins is well established.

Secretion of the thyroid stimulates cell metabolism in general, but its chief influence is in protein metabolism. In instances of lessened function of the gland, as in myxedema, the nitrogen metabolism is lowered 50 per cent. If thyroidless animals are fed with thyroid extract, the nitrogen output increases.

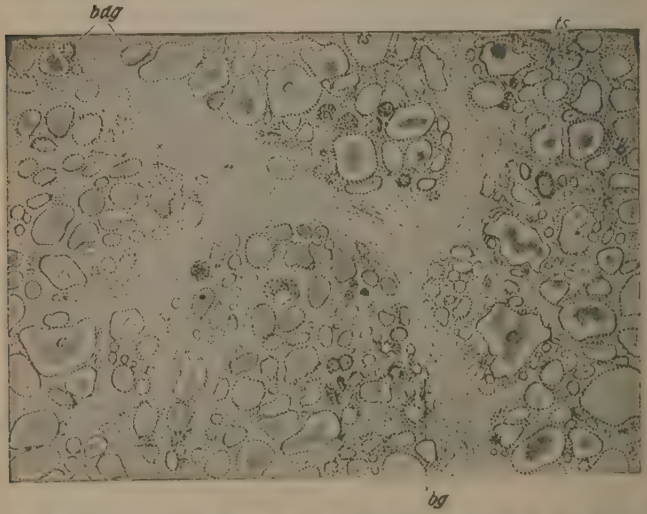

Fig. 372.—Portion of a cross-section of thyroid gland of a man; × 30: *bdg*, Interstitial connective tissue; *bg*, blood-vessel; *c*, colloid substance; *ls*, gland alveoli. (Sobotta and Huber, Atlas and Epitome of Human Histology.)

Thyroxin influences the blood-picture. Administration of thyroid extract increases the blood-picture in red cells 15 per cent. or more. In Basedow's disease, characterized by excessive activity of the thyroid, there is an increase in the number of white cells, producing a lymphocytosis.

The **parathyroids** are four small epithelial structures placed usually near the posterior aspect of the lateral thyroid masses (Fig. 373). They are only about 6 mm. in diameter. The cells of the parathyroids produce a secretion that is concerned with

the elimination of toxic substances formed during the metabolic processes of the body. On removal of these organs these toxic

Fig. 373.—Posterior thyroid region: *A*, Inferior thyroid artery; *B*, recurrent laryngeal nerve; *C*, superior thyroid artery; *D*, parathyroids. (Campbell.)

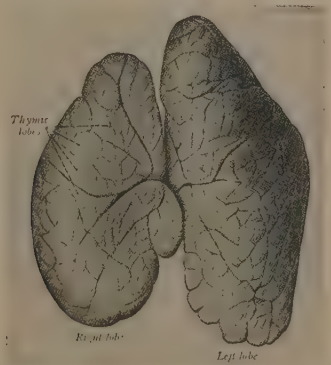

Fig. 374.—The thymus gland of a two-year-old child seen from in front (Sobotta and McMurrich).

substances accumulate, resulting in a condition known as *tetany*, characterized by muscular tremors and spasms, loss of muscle tone, and the finer co-ordinations of the body.

Function of the Parathyroids.—The secretion of the parathyroids indirectly favors coagulation of the blood through its hormone effect upon calcium metabolism. Deficiencies of the secretion are noted in softening effects on bone and teeth structures. Experimental tetany produced in animals by removal of the parathyroids is marked by overirritability of the sensory and motor nerves.

The **thymus** is situated at the base of the heart between the two lungs and behind the sternum. It comprises two flattened lobes that diverge below. It arises as a growth from a pouch of the pharynx and attains its greatest size by the beginning of puberty. In infants its average weight is about 12 grams, and at

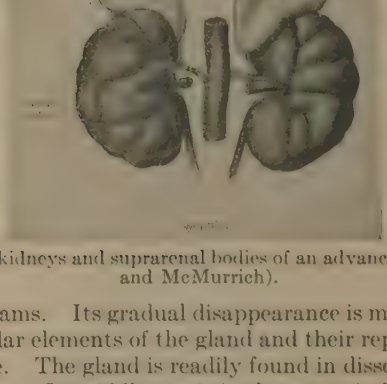

Fig. 375. –The kidneys and suprarenal bodies of an advanced fetus (Sobotta and McMurrich).

puberty 35 grams. Its gradual disappearance is marked by a loss of the glandular elements of the gland and their replacement with adipose tissue. The gland is readily found in dissection until the twentieth year. In middle age it is almost entirely replaced and exists as only a fibrous cord.

The structure of the thymus resembles a lymphoid organ. It has a capsule from which septa pass into the gland, dividing it into lobes (Fig. 374). The lobes show a dense outer portion; of much looser structure is the medulla. The cortex is composed of closely packed lymphocytes. The medulla shows many white cells not so closely assembled and occasionally little groups of epithelial-like masses called the *corpuscles of Hassall*.

Its disappearance after puberty suggests its influence in the development of the sex characteristics of the individual. It is

liberally supplied by vessels and lymphatics. The nerves come from the autonomic and the tenth cranial (vagus).

Function of the Thymus.—The thymus acts in calcium metabolism probably by promoting assimilation of calcium salts. During childhood it is the organ of growth of bones, and at puberty atrophy and decreased functioning begin. It is believed that the germ glands arising to functioning levels at this time



Fig. 376.—Section of suprarenal cortex of dog (Böhm, Davidoff, and Huber).

exert a restraining influence upon the thymus. Removal of the thymus in adults is without influence upon growth in height.

The **adrenals** or **suprarenal capsules** are a pair of cocked-hat-shaped glands capping the upper ends of the kidneys (Figs. 360, 375). They are somewhat variable in size; sometimes their length may be 6 to 7 cm. (3 inches) and their breadth 3 or 4 cm. ($1\frac{1}{2}$ inches). They weigh only about 7 grams. The internal structure (Fig. 376) shows an outer or cortical portion in which epithelial cell masses are arranged in columns heading toward the capsule of the gland. Between the columns are septa of connective tissue. The epithelial cells of the cortex are derived from the mesoderm and come from that part in approximation with the genital gland. The inner part of the adrenals is called

the medulla, composed of coarsely granular epithelial cells. This portion of the gland is derived from the same structures that produce the tissue of the autonomic system. Developmentally the close relation of this organ to the nervous system is thus shown, and corroborates the evidence that is available from its functional activity.[2]

These glands are liberally supplied with vessels and nerves. The fibers from the solar and renal plexuses of the autonomic system are especially numerous, this characteristic inducing some anatomists to classify this gland as an accessory organ of the nervous system.

Function of the Adrenals.—The medulla of the adrenal gives an internal secretion that functions in maintaining a state of partial constriction or tonus of the blood-vessels. Its secretion is greatly increased in emotional states due to the excitation through the autonomic system.[3] The active principle of the gland is called *adrenin*. It may be obtained from the adrenals of animals; the name *adrenalin* is applied to the commercial product so obtained. Administered, it causes a rise in blood-pressure. Within one-half hour injection of adrenalin increases the total number of white-cells to 22,000, but removal of the spleen prevents this. Its action in this case would seem to be a mere driving of the cells out of the spleen rather than stimulating their production. Adrenalin increases the rapidity and force of the heart, accelerates the velocity of the heart's contraction, and increases the irritability of the heart muscle. Probably associated with the pituitary and thyroid, it acts to keep smooth muscle in tone. The vessels of the mucous membrane are sensitive to adrenalin and constrict under its influence. There is evidence that the cortex of the gland is associated with growth and sexual development. Disease of the adrenals results in a condition known as *Addison's disease*, characterized by muscular weakness, tremors, convulsions, low blood-pressure, and bronzing of the skin.

The cortex of the adrenals yields the substance *cholin*. Its action upon the heart is opposite to the action of adrenalin. According to Weil,* "it acts on the inhibitory fibers of the vagus and, therefore, slows the rate of the beat; it diminishes the size of the heart's contractions, decreases its conductivity, and decreases its receptivity for stimuli." Cholin is also a product of other glands: spleen, pancreas, liver, muscles, kidneys, and lungs.

* Weil, A., Loc. cit., p. 64.

The **pituitary gland** or **hypophysis** (Fig. 227) is composed of two lobes: an anterior one derived as an outgrowth from the roof of the oral cavity, the posterior coming from the base of the brain. The anterior portion shows elements that denote its pharyngeal heredity; the posterior part is an outgrowth from the midbrain. There is a middle portion, but functionally this is associated, as a rule, with the posterior lobe. The gland increases in size until about the thirtieth year, and weighs then about 5 grains. It lies in a saddle-like depression, sella turcica, of the sphenoid bone and is covered with dura mater.

Examination of its internal structure shows that the anterior lobe is highly granular and composed of masses of epithelial cells of two kinds—*chief* and *chromophil* cells. These cells are arranged in acini richly supplied with capillaries. Within some of the acini is a substance called *colloid*, resembling in this respect the thyroid gland. In the adult the posterior lobe has lost most of the elements that identify it as of nervous origin. Its substance is mainly formed of connective-tissue fibers that suggest a similarity with the connective tissue of the brain and cord, but without having any distinct features of nerve tissue. The anterior lobe gives its secretion directly into the blood-stream. The posterior lobe secretes its substances into the third ventricle of the brain.

Function of the Pituitary.—The anterior lobe influences growth in height.[4] Giantism and dwarfism are expressions of the hyper- and hypofunction respectively of this lobe. Giantism is followed frequently by acromegaly, a condition of enlargement of the bones of the hands and feet especially. It should be remembered that the pituitary is not alone in the endocrine effect upon growth. The germ glands and thymus also play important parts, although the interrelations are not clear. Weil suggests the following diagram as a schematic representation of the action of the internal secretions on growth in height:

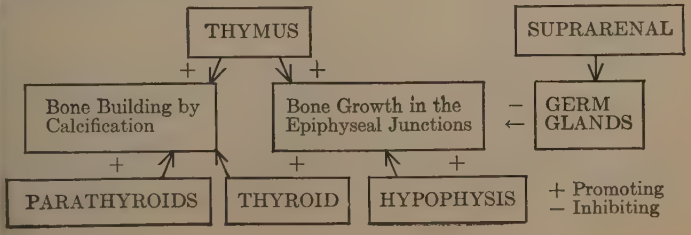

The pituitary functions in pregnancy and labor. Toward the end of pregnancy the anterior lobe is increased in size about two and one-half times, and its cells multiplied and so altered at this time that they have been called pregnancy cells. Extract of the anterior and the posterior lobe as well has a strong stimulating effect on uterine contractions.

The extract of the posterior lobe is marketed under the name *pituitrin*. It increases the rate of the heart's contractions, but decreases the force of each systole. It acts directly upon the heart muscle and not upon the endings. Pituitrin causes increased peristalsis of the intestine. It is a powerful stimulant to the uterine muscle. It has been used in labor, but its effects are so pronounced that its use in this respect is not generally approved. Extirpation of the whole pituitary is fatal.[5]

The Germ Glands. —The anatomy and physiology of the germ glands are described in previous chapters with respect to the rôle of the ovum in maturation and fertilization, and the function of spermatogenesis. The function of these glands as endocrine structures will be considered in this chapter.

Function of the Germ Glands as Internal Secretory Organs.—Brown-Séquard laid the foundation for endocrinology when he injected himself with testicular extract and reported improved strength and other evidences of regenerated power and function. After a great many trials with the hand dynamometer over a ten-day period he found strength of grip to range from 32 to 37 kilos, with an average of 34½. On May 15, 1889 he gave himself an injection of a water-extract of guinea-pig testicles. Dynamometer values rose immediately to an average of 41 and reached a maximum of 44 kilos. This strength persisted up to three years later, when he demonstrated his experiment before the Paris Academy. His work was corroborated by Zoth and Pregi.[6]

This work of Brown-Sèquard was the basis of the experiments by Steinach. Working with rats and other animals he increased strength and power to do muscular work. Elderly men have reported that after the Steinach operation they are better able to endure long marches, stair climbing, and other tests demanding strength. There has not been, however, any general acceptance of the claims of Steinach for "rejuvenation" of the aged.

These and other experiments have laid the foundation for the understanding of the interstitial cells of the testes and the significance of their function. Removal of the testes is marked by

definite changes in the body, characterized by the eunuchoid state. In castrated male dogs the number of red cells of the blood is reduced and the hemoglobin content of the blood falls. The glands of both sexes co-operate in fashioning the form of the body and are doubtless responsible for the secondary sex characters. In the female the changes at the menopause are to be ascribed to failure of an internal secretion, and at the menstrual period many of the physical and mental phenomena are indications of hormone action.

Other Organs.—Since the recent discoveries of endocrine function internal secretions have been attributed to almost every organ in the body. More has been claimed at times than the facts warranted. Three glands, whose functions are unknown still, will be described briefly. They are the *pineal gland*, the *carotid body*, and the *coccygeal body*.

The *pineal gland* is the homologue of the pineal eye of reptiles, but in man exists as a small organ at the roof of the interbrain, above the thalamus (Fig. 227). It is shaped like a cone and is about 8 to 10 mm. in length. It attains its maximum growth early and loses its secretory function in adult life. Very little is known regarding its function in the animal organism, although M'Cord found that it had a stimulating influence on growth. Its internal structure shows a connective-tissue network within which are epithelial cells, and occasionally concretions of calcium carbonate and phosphate, called *brain-sand*.

The *carotid body** is a small gland, ovoid in shape, placed on the upper end of the carotid artery. It shows on section a very large number of nerve-cells, and numerous epithelial cells that stain a yellow color with chromic acid salts. The presence of chromaffin cells, the large number of nerve-fibers, and its close resemblance to an autonomic ganglion suggests its relationship to the autonomic system. Its exact function is not known.

The *coccygeal body*† (gland of Luschka) has no known function, but is probably connected with that stage of development in which the tail was a prominent factor. It is found in front of the tip of the coccyx. This gland is not uncommonly the seat of

* The carotid and coccygeal bodies have been grouped with the ductless glands, although they are not true glands in the sense of the term as used with the thyroid and similar structures. It may be that their functional position will at some time be determined, allowing a more accurate classification.

† Ibid.

neoplastic growth at times malignant in character. The gland has a capsule from which fibers of connective tissue invade the substance of the organ to divide masses of epithelial cells. Numerous arterial branches ramify through the structure. The function of the coccygeal body is not known.

PRACTICAL EXERCISES

1. Extracts of the endocrine organs may be used to supply deficiencies in the body. Thus thyroid extract is exceedingly valuable in cretinism. The use for growth conditions of thymus, pituitary, and suprarenal extracts has not been as yet adequately established. Examine these substances.

2. Pituitary extract (pituitrin) is used for its power to cause contraction of smooth muscle. Where is smooth muscle situated in the body? Examine some pituitrin.

3. The action of the extract of the adrenals (adrenalin) is to cause an increase in blood-pressure. This can readily be shown on experimental animals.

QUESTIONS

1. Describe the thyroid gland. What is colloid?
2. Where is the thymus situated? When does it disappear?
3. What is adrenin?
4. Describe the adrenals. Have they anything specific to do with kidney action in the secretion of urine?
5. It has been suggested that the improved growth and health after removal of the adenoids is due to a relation between the adenoids and the pituitary gland. What relation is there?
6. What is "insulin"?
7. Persistence of the thymus is seen in *infantilism*, a condition of infant characteristics in adult life. What would this indicate with regard to its function?
8. Describe the characteristic function of each one of the internal secretory glands.

REFERENCES FOR FURTHER STUDY

1. McClendon, J. F.: The World's Supply of Iodine, Science, September 8, 1922; Are Iodides Foods? Science, April 7, 1922.

2. Elliott: Amer. Jour. Phys., 1912, xliv, p. 409. Crile, G. W.: The Kinetic Drive; Its Phenomena and its Control, Jour. Amer. Med. Assoc., December 18, 1915, p. 2129.

3. Cannon, W. B.: Bodily Changes in Pain, Hunger, Fear, and Rage, D. Appleton & Co., 1915.

4. Cushing, H.: Disorders of the Pituitary Gland, Jour. Amer. Med. Assoc., June 18, 1921, p. 1721.

5. MacCallum, W. G.: A Text-book of Pathology, W. B. Saunders Co., Philadelphia, 1922, p. 898.

6. Weil, A.: The Internal Secretions, The Macmillan Co., New York, 1924, pp. 141–211.

CHAPTER XIX

ORGANS OF GENERAL AND SPECIAL SENSE

I. Classification of the General and Special Senses.
II. The General Senses:
    Touch Sensation in Children.
III. The Skin and Its Appendages:
    1. The Layers of the Skin.
    2. Nerve Endings in the Skin.
    3. The Hair.
    4. The Nails.
    5. The Glands:
        Sebaceous.
        Sweat.
        Ceruminous.
        Ciliary.
IV. The Sense of Smell.
V. The Sense of Taste.
VI. The Sense of Sight.
VII. The Eye:
    1. The Outer Parts of the Eye.
    2. Structure of the Eye.
    3. The Muscles of the Eye.
    4. How the Eye Sees.
    5. Defects in the Eye.
    6. Defects in the Optic Tract.
    7. Defects in the Brain.
VIII. The Senses of Hearing and Equilibrium.
IX. The External Ear.
X. The Middle Ear.
XI. The Internal Ear:
    1. Two Parts of the Internal Ear.
    2. How the Ear Hears.
    3. The Semicircular Canals.

Classification of the General and Special Senses.—The simple unicellular animal so often referred to in these pages (Fig. 2) receives stimuli from its surrounding environment. These forces that stimulate it act directly upon its limiting membrane. The development of multicellularity did not greatly disturb that essential fact. Although in man the distribution of receptors to the viscera gave the sense of pain, and in a limited way the senses of touch and temperature to organs of the entoderm, still it is in the ectoderm that the sense organs are conspicuously placed. So while pain, temperature, and touch must be described in

relation to viscera as well as body surfaces, it is the latter that form the distinctive site for the location of these senses. Smell, taste, sight, hearing, equilibrium, touch, temperature, and pain are conspicuously related to the ectoderm; appetite, hunger, thirst, and pain are located in viscera or parts, and may be referred to the body surface that is in nerve connection with the deeper parts concerned. A simple tabulation* of the general and special senses could be made as follows:

General senses	Appetite	Pain
	Hunger	Temperature
	Thirst	Touch
Special senses	Smell	
	Taste	
	Sight	
	Hearing	
	Equilibrium	

The General Senses.—*Appetite* is closely associated with the senses of taste and smell, with the appearance of food, and with a gastric component that is somewhat variable. Technically it may be considered as a pleasurable mental state arising in excitation of the senses of taste and smell.

Hunger is more directly related to the stomach than appetite. Common manifestations of hunger are due to the contractions of the empty stomach. Usually the sensation is referred to the epigastrium.

Thirst is felt in the mouth and pharynx. With loss of water from the blood the nerves in the oral and pharyngeal regions are stimulated. Thus in hemorrhage thirst may be a cardinal symptom. The sensation of thirst may be temporarily relieved by applying small amounts of water to the mucous membrane of the mouth and pharynx, but the effect is only momentary. Taking of water into the stomach, from which organ it may enter the blood, gives effective relief.

It will be seen that appetite, hunger, and thirst are related to certain viscera or parts. In character their manifestations are frequently more diffuse, general, and less clearly recognized than the senses of pain, temperature, and touch.

* Sherrington (The Integrative Action of the Nervous System, Yale University Press, 1906) offers a classification of the senses under two headings: somatic and visceral. Under the former he places touch and pressure, pain, heat and cold, general chemical sensibility, vision, hearing, muscle sense, and equilibrium. Under the latter are the senses concerned with digestion, circulation, sexual sensation, visceral pain, and others.

Pain is probably derived from stimulation of specific receptors very widely distributed. This view is sustained by the fact that pain may be lost and touch remain, as in syringomyelia. Pain in the viscera is aroused by distention and cutting is hardly felt, whereas in the skin cutting is extremely painful. Pain in the surface of the body may indicate visceral disease due to the distribution of autonomic and spinal nerves to the body wall and viscera from the same segments of the cord.



Fig. 377.—Cold and hot spots from the anterior surface of the forearm: *a*, Cold spots. *b*, Hot spots. The dark parts are the most sensitive; the hatched, the medium; the dotted, the feebly, and the vacant spaces, the non-sensitive. (Landois and Stirling.)

Temperature is probably excited by receptors of two distinct types. Heat and cold spots (Fig. 377) have been mapped out on the body surfaces, mucous membranes of the mouth, nose, anus, and auditory canal.

Touch or pressure gives information of a more varied kind than that received in pain or temperature. It may include impressions of size, shape, smoothness, hardness, or wetness. The touch sense is located in receptors (Figs. 206, 207) quite generally distributed and yet greatly increased in certain areas. Tactile acuity is measured by recording the minimal distance at which the two separated points of a caliper may be distinguished. This

is known as discriminating touch, for which Burton-Opitz* gives the following:

	Millimeters.
Tip of tongue	1.1
Palm of the last phalanx of the finger	2.2
Palm of the second phalanx of the finger	4.4
Tip of the nose	6.6
Back of the second phalanx	11.1
Back of the hand	29.8
Forearm	39.6
Sternum	44.0
Region along spine	54.0
Middle of the back	67.0

Tactile sensibility in children increases from childhood up to puberty. It then tends to decrease. This greater sensitivity in childhood is due to a greater number of tactile corpuscles per unit area of skin and to a more delicate and thinner skin. With growth in size of the individual the skin increases its area, but the number of corpuscles remains constant from birth.

The **skin and its appendages,** hair, nails, and glands, are derived from the ectoderm. The deeper part of the skin and the fascia beneath the skin come from the mesoderm, although some of the supplementary structures of the skin, *e. g.*, the muscles (arrectores pilorum) and glands, are ectodermal in origin. This origin emphasizes the functional characteristics of the skin: it is essentially protective to the surface of the body; it serves as an outlying sense organ for certain mechanisms of the nervous system; its glands have two functions, one to oil the surface of the body and the other to help in the maintenance of the water content and the heat regulation of the body.

The Layers of the Skin.—The skin is composed of two layers: an outer one, the *epidermis*, and an inner, the *derma*. The epidermis is composed entirely of epithelial cells which are arranged in two main layers or strata. The *stratum corneum* is the outer layer of cells, horny in character and variable in thickness in different parts of the body. The outermost cells of the stratum are dead and represent an exfoliative process in the growth of the epidermis, similar to the shedding of the skin as seen in certain reptiles, and the loss of the hard covering as seen in the lobster. The *stratum germinativum* or *malpighian layer* of the epidermis is the lower portion next to the derma, and rests upon the prolongations (papillæ) of the derma (Fig. 378).

* Burton-Opitz, R.: A Text-book of Physiology, W. B. Saunders Co., Philadelphia, 1920, p. 738.

The derma is the vascular and connective-tissue layer of the skin. The epidermis is without blood-vessels, but the derma is liberally supplied. From the derma nutritive substances diffuse to the outer layer Except for a few scattered areas the derma is thrown into folds called papillæ, which account for the ridges

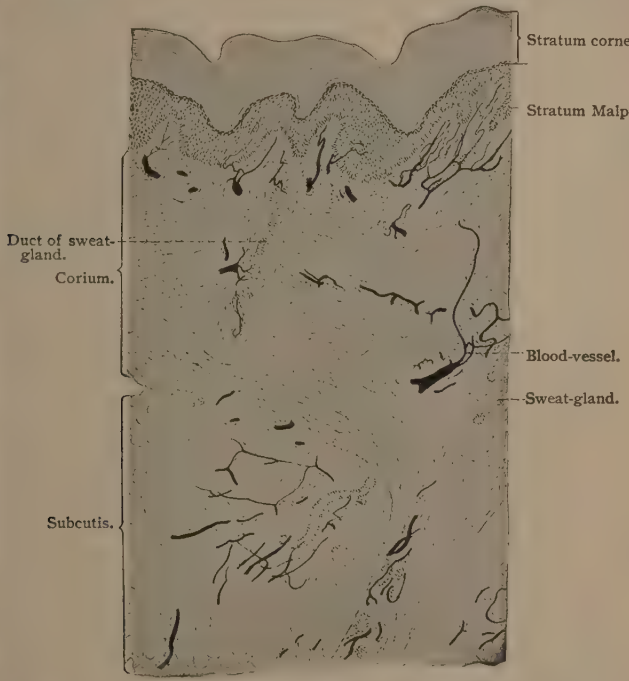

Fig. 378.—Cross-section of skin of child, with blood-vessels injected; × 30 (Böhm, Davidoff, and Huber).

on the surface of the skin, particularly on the palms of the hands. The deeper parts of the derma fuse with the subcutaneous fascia and holds in reticulated masses globules of fat. It is in this stratum that the roots of hairs are embedded and the body of the cutaneous glands are found.

The color of the skin is due to the pigment present in the deeper cells (malpighian layer) of the epidermis modified by the

amount of blood suffusing the area. In death, when the blood is not coursing through the cutaneous capillaries, the skin appears in the white person as a pale and pallid structure. In the negro and other colored races the amount of pigment is relatively large and may be present even in the outermost cells of the epidermal layer.*

Nerve Endings in the Skin.—The skin is liberally supplied with sensory endings of the cerebrospinal nervous system. They terminate in highly specialized endings, called *corpuscles*, in the papillæ of the derma, or in the deeper parts of the dermal layer. The structure of these endings has been described in the chapter on the Nervous System, and is only mentioned here. They are: (1) *Meissner's corpuscles* (Fig. 379) located in the papillæ and especially numerous in the tactile pads of the hands and feet; (2) *Pacinian corpuscles*, located in the deeper parts of the derma usually; (3) *end bulbs of Krause*, very sensitive endings, located near the epidermis. They are present also in the conjunctiva of the eyelid, the lips, mucous membrane of the mouth, and other parts of high sensibility; (4) *end organs of Ruffini* are located in the subcutaneous part of the derma and exist as large receptors probably concerned with the deeper pressure sensations. In addition to the sensory endings there are the terminations of the vasomotor nerves in the blood-vessels of the derma.

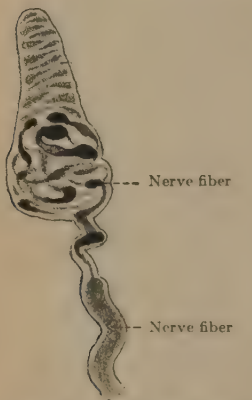

Fig. 379.—Meissner's corpuscle from man; × 750 (Böhm, Davidoff, and Huber).

The *hair* is of epidermal origin. It is distributed over almost the entire body, being absent from only a few areas, *e. g.*, the flexor surfaces of the hands and feet, the extensor surfaces of the distal phalanges of the fingers and toes. The hair grows from a pit-like depression of the skin, called the *hair-follicle* (Fig. 380).

* Pigmentation in the skin normally increases with age. There are more blond children than blond adults. This change in pigmentation occurs largely during puberty.

That part of the hair lying in the follicle is called the *root*, and that portion above the surface of the skin is known as the *shaft*. Examination of the internal structure of a hair shows that it is composed of cells that have coalesced in three well-defined layers, the *cuticle*, *cortex*, and *medulla* (the last division is sometimes absent). The root of the hair is the vital part of the hair. The

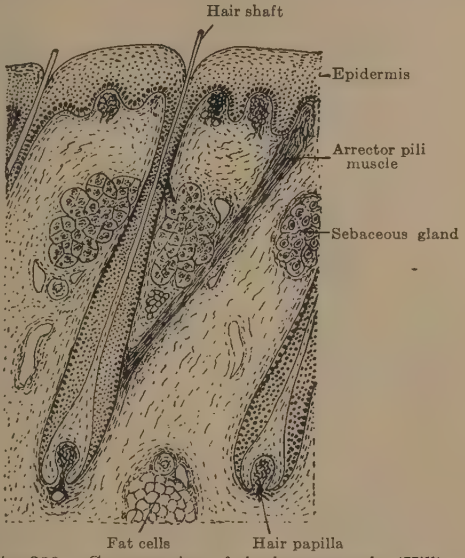

Fig. 380.—Cross-section of the human scalp (Hill).

cells of the shaft are lifeless, those of the root account for its growth, color, and vitality. The root ending of the hair swells out into a bulbous termination that caps a vascular projection of the derma. This fact indicates clearly the capillary distribution to the root of the hair, and lays a scientific basis for the interpretation that is to be made of the claims for hair tonics and restorers.

The follicles of the hair are placed obliquely in the skin so that the hair tends to lie flat on the surface of the body. Connected with each follicle is a small involuntary muscle, arrector pilorum, which on contraction will pull the follicle into a vertical position and make the hair stand straight or "on end." This erection of

the follicle thrusts it outward and gives the characteristic eminences on the skin known as "gooseflesh."

The *nails* are structures similar to hair in their origin and general characteristics. They correspond to the claws and hoofs of other animals. They present a convex outer surface and an underlying concavity that rests upon and is adherent to the derma, forming the *matrix* of the nail (Fig. 381). The matrix of the nail which is concerned with the growth of the nail is observed externally as the crescentic area, called the *lunula*, a white, half-moon-shaped area at the base of the nail. Distal to the lunula or matrix the pinkish portion of the nail plate is merely attached to the underlying skin tissue. Growth of the nail occurs only at the matrix, and is accomplished by proliferation of the cells forming the germinative layer of the root. Injury to the nail

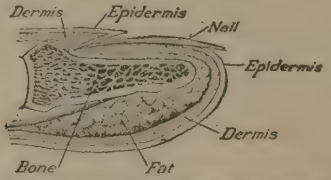

Fig. 381.—Section of nail and parts beneath (from Williams, Healthful Living, published by The Macmillan Company).

following infection or by violence may result in complete loss of the nail. It will be restored, however, if the cells of the matrix are left intact.

The *glands* of the skin are the sebaceous, sweat, ceruminous, ciliary, and mammary glands. The mammary glands have been described in connection with the organs of generation.

The sebaceous glands are closely associated with the hair-follicles,* although they occur in non-follicular areas also. They arise as prolongations downward of the epidermis, retaining a duct opening in the cavity surrounding the hair and directly continuous with the skin surface. They present an alveolar arrangement of epithelial cells that secrete an oily substance, *sebum*. The *vernix caseosa* of the newborn child is the product of the sebaceous glands acting during the last three months of intra-uterine life. The vernix is especially abundant in the folds and creases of the body.

* Modified sebaceous glands are meibomian glands of the eyelid opening along the lid margins near the lashes.

The sweat-glands (Fig. 382) are simple convoluted tubules present in all of the cutaneous surface of the body. They consist of a coiled duct that leads from a tortuous tube located in the deeper stratum of the derma. The duct opens upon the surface of the skin by an orifice called the pore, that can often be seen by the unaided eye. Contrary to popular belief, the pores do not open or close; although the hygienic advice which uses the pores as the argument may be good and wholesome. The tortuously

Fig. 382.—Coiled end of a sweat-gland, epidermis not shown: *a*, The coil; *b*, the duct; *c*, network of capillaries. The gland and capillary network are shown separated and combined to indicate how completely the organ is supplied with blood. (From Williams, Healthful Living, published by The Macmillan Company.)

wound tube, the body of the gland, is liberally supplied with capillaries which have a rich innervation of vasomotor nerves. The cells of the gland itself are abundantly supplied with nerves from the autonomic system, resulting with the capillary innervation in a ready and effective control of the perspiratory activity of the individual. The relation of emotional states to the secretion of sweat is explained in the nerve supply afforded the glands. Either or both sets of nerves may act to produce perspiration. The sweat-glands may be stimulated to activity even when the skin is pallid, or they may be inhibited in their activity, showing an absence of perspiration so characteristic of fever.

The ceruminous glands are modified sweat-glands located in the external auditory meatus. They give a rather copious waxy secretion called *cerumen*, which, while very oily, contains, in addition, a large amount of pigment. This wax protects the drum membrane from dust, and possibly by its peculiar odor it protects against insects entering the canal.

The ciliary glands of the eyelid are modified sweat-glands giving a secretion to the conjunctival sac.

The Sense of Smell.—The organ of the sense of smell has already been described (page 365). In addition to serving as an entrance for air to the respiratory tract, the nasal passages have important functions related to the sense of smell. The upper parts of the middle and superior turbinate bones contain in their mucous membranes the receptors of the olfactory nerve, and it is from the excitation of these olfactory endings that the sense of smell is derived. Conditions—*e. g.*, a cold—that interfere with this area may deprive the individual of the power to distinguish odors. It is an interesting fact that the chewing of certain foods increases the odor of the food. This is not due to any olfactory power that resides in the mouth, but rather is due to the fact that mastication and heat sets free the volatile oils of the food, rendering their escape to the olfactory area of the nose easier.

The Sense of Taste.—The mucous membrane of the tongue is the seat of the taste-buds that serve to receive and distinguish between flavors. In children the taste-buds cover almost the entire dorsal surface of the tongue, the cheeks, and the pharynx, but in the adult they have largely disappeared from the tip of the tongue and cheeks and in part from the pharynx. The sense of taste is more acute in childhood, and some children may show an extremely sensitive reaction to certain tastes and odors.[1] Sensations of taste are very numerous. Many of them are dependent upon olfactory co-operation. They may be grouped, however, into four classes: sweet, bitter, sour, and salty. Sweet is distributed mainly to the tip of the tongue. Bitter is located at the base near the circumvallate papillæ (see page 398). Sour is perceived most readily in the central portions of the lateral aspects, and salty in front of these regions.

The Sense of Sight.—Light rays may affect animals in two ways: in simple organisms it is observed that there is a tendency for them to orient themselves with reference to the intensity and direction of the light rays.[2] This is known as *heliotropism* or

phototaxis. Among the higher animals there is the power to distinguish objects in the environment by means of a special apparatus—the *eye*. In invertebrates this is not much more than

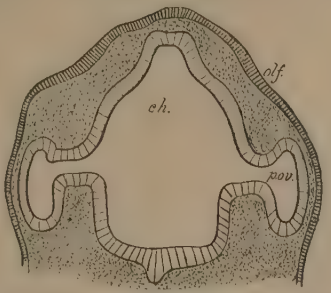

Fig. 383.—Part of a section through the head of an early human embryo, showing the connection of the primary optic vesicles with the forebrain (His): *olf*, Olfactory area; *ch.*, part of forebrain which gives rise to cerebral hemispheres; *p.o.v.*, primary optic vesicles.

a pigment spot, developed among the superficial cells of the ectoderm; in vertebrates it arises as an outgrowth of the forepart

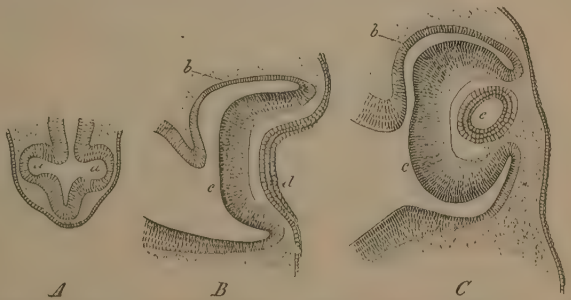

Fig. 384.—Three successive stages of development of the eye, showing formation of secondary optic cup and crystalline lens in human embryos of 4 mm. (*A*), 6 mm. (*B*), and 8 mm. (*C*) (Tourneux): *a*, *a*, Primitive optic vesicles; *b*, external layer of secondary optic cup (future pigment layer of retina); *c*, inner layer of cup (retina proper); *d*, lens pit (thickened and depressed ectoderm); *e*, lens vesicle.

of the brain. The eye itself represents a highly specialized receptor for light rays. It responds to them in such fashion that impulses are started from eye to the brain, resulting in vision.

The Eye.—This begins in man as an outgrowth of the forepart of the brain in a structure known as the *primary optic vesicle* (Fig. 383). The vesicle extends outward until it comes in contact with the ectoderm, at which point there occurs proliferation of the cells of both ectodermic layer and vesicle. Later there results invagination of the optic vesicle, further differentiation of the ectoderm, and growth of the mesodermic layer to form certain essential structures of the eye (Fig. 384).

The Outer Parts of the Eye.—The eyes are situated in the orbital fossæ of the skull, protected in front by the eyelids. The lids are composed of muscle attached to cartilaginous plates which give form and firmness to the lid. They are covered externally by skin. The eyes are moistened by the secretion of the *lacrimal*

Fig. 385.—Lacrimal apparatus (Campbell).

glands, one with each eye. The lacrimal gland lies at the outer and upper portion of the orbital opening. The secretion from the gland spreads over the front of the eye completely bathing the anterior surface, washing away any dirt, and keeping the surface moist. The direction of the flow of the secretion is toward the mesial corner of the eye, where the excess is drained into the *nasal duct* by two small openings at the inner angles of the lids (Fig. 385). The lining of the lid is mucous membrane which is reflected from the lids on to the front of the eye, forming in the recesses of the lid a sac known as the *conjunctival sac*. The

edges of the lids are covered by short hairs, the ones on the upper lids being longer. The inner margins of the lids are equipped with glands, the *meibomian glands*, which secrete an oily liquid, preventing the overflow of the tears from the conjunctival sac (except in instances when the secretion is greatly increased), and serving to keep the lids from sticking together.

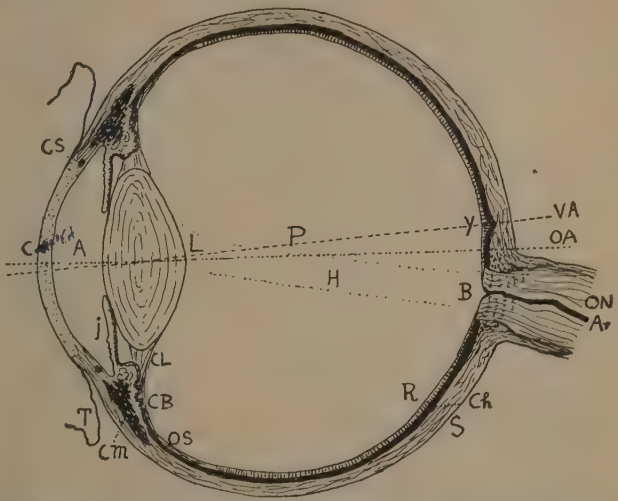

Fig. 386.—Diagram of a horizontal section through the human eye: *C*, cornea; *A*, anterior cavity which includes part in front of iris, the anterior chamber, and part behind iris and in front of lens, the posterior chamber; *P*, posterior cavity; *L*, lens; *J*, iris; *T*, conjunctival sac; *CL*, ciliary ligament; *CB*, ciliary body; *CM*, ciliary muscle; *OS*, ora serrata; *CS*, canal of Schlemm; *R*, retina; *Ch*, choroid; *S*, sclera; *ON*, optic nerve; *A*, retinal artery; *B*, blind spot; *Y*, yellow spot; *OA*, optical axis; *VA*, visual axis; *H*, hyaloid canal. (Burton-Opitz.)

Structure of the Eye.—The eyeball is a globular organ (Fig. 386) composed of three coats and divided into two cavities by an apparatus for controlling and refracting the light rays, namely, the ciliary body, lens, and iris. The anterior cavity is divided into anterior and posterior chambers by the iris. The outer coat of the eyeball is the *sclera*, composed of tough fibrous tissue that gives form to the eyeball. This coat serves for the attachment of the muscles of the eye. It is continued in front by a highly

modified coat of connective tissue, the *cornea*, which is transparent, and hence allows light rays to readily pass through it. The middle coat is the *choroid*, which is composed largely of blood-vessels (Fig. 387). Anteriorly this coat merges into the *ciliary body*, which is composed of muscle-fibers and vascular spaces. Attached to the ciliary body is the *suspensory ligament*

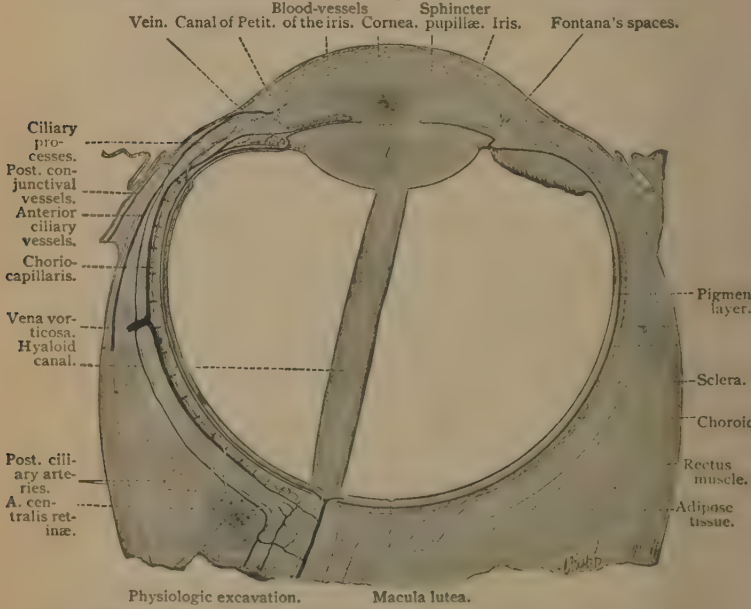

Fig. 387.—Schematic diagram of the eye: *l*, lens. (After Leber and Flemming.)

which supports the *lens*,* a highly crystalline body, and the muscles of the *iris*, which form the diaphragm controlling the amount of light admitted to the eye. The muscles of the iris contain a varying amount of pigment. With the onset of puberty the iris begins to lose its depth and purity of color, and streaks and spots appear. The muscles of the iris are arranged in circular and radial fashion. Contraction of the circular ones constrict

* Cataract of the eye is an opaqueness of the lens, corrected by removal of the lens.

the pupil, while contraction of the radial ones dilate the pupil. The inner coat of the eye is the *retina*,* composed of the highly specialized endings of the optic nerve. This coat possesses several layers of cells (Fig. 388) which connect with the terminal fibers of the optic nerve in the deeper parts of this lining. From this coat the fibers of the optic nerve converge toward a common center, leaving the eyeball as a definite nerve (Fig. 389). After leaving the orbit the nerves cross at the optic *chiasma* and spread backward through radiations of the optic fibers to the calcarine area of the brain (see page 268). The anterior

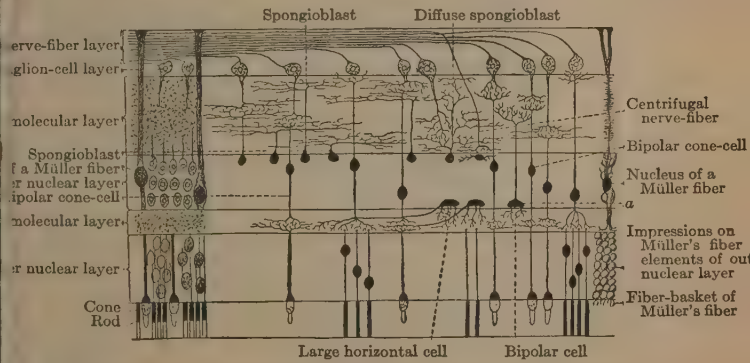

Fig. 388.—Schematic diagram of the retina according to Ramóny Cajal. The line *a*, after passing through Müller's fiber, crosses a bipolar rod-cell, then two bipolar cone-cells, and finally ends in the body of a bipolar cone-cell. (Böhm, Davidoff, and Huber.)

cavity of the eye is filled with a lymph-like fluid called the *aqueous humor*. The posterior one is much larger and contains the *vitreous humor*, a fluid of heavier consistency, more like jelly. Passing from the optic nerve to the posterior part of the lens is a small canal, called the *hyaloid canal*. It is the remains of an artery present during fetal development of the eye.

The *retina* is the receptor of the optic nerve. As a highly specialized receptor it is arranged in eight layers (Fig. 388). The first layer shows the terminal filaments of the optic nerve

* Near the posterior pole of the eye the cells of the retina are greatly increased in number, making an area known as the *macula lutea*. In the center of the macula the cells are reduced in number, leaving only those of pronounced visual power. This point is the *fovea centralis*, or point of most acute vision.

ending in ganglion cells. In the seventh layer are located the rods and cones. These may be considered the essential elements of the receptor. There are several theories of visual perception, but the ones that employ an explanation based upon chemical changes in the rods and cones appear most acceptable. Such views consider the presence of a phototropic substance in the rods and cones as the starting-point. This substance is known as

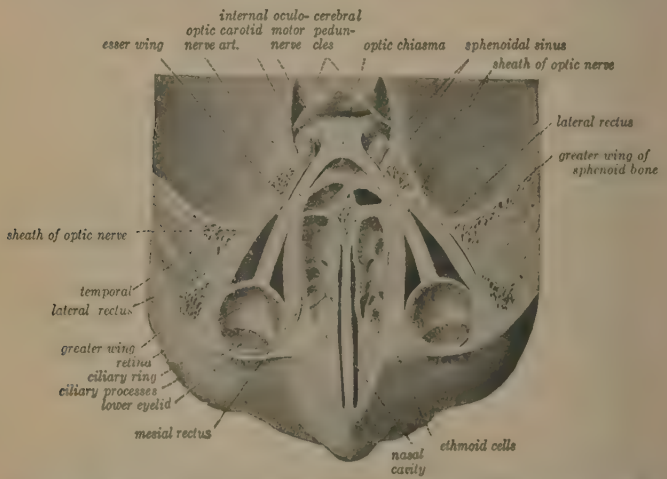

Fig. 389.—A horizontal section of both orbits. The section has been carried somewhat obliquely posteriorly, in order to show the entire length of both optic nerves (Sobotta and McMurrich).

visual purple. The rods and cones apparently play different rôles in dim light and in white light, but all variations seem to be interpreted in terms of varying amounts of visual purple in the rods and cones. The various theories of *color vision* also assume the presence of a phototropic substance in the rods and cones. *Color blindness* would, in such view, be due to lack of such material or of certain portions of it.

The Muscles of the Eye.—There are six muscles of the eyeball that serve to move the eyes in different directions. These six, described in detail in Chapter VII, are (Fig. 390) four straight ones and two oblique: superior rectus, MEDIAL rectus, inferior rectus, lateral rectus, superior oblique, and inferior oblique.

The four recti muscles pull the eyeball in the direction indicated, *e. g.*, the superior one pulls the eyeball upward, the lateral pulls it to the side, etc. The action of the oblique muscles is conditioned by the fact that the superior one pulls through a pulley, and hence gives a twisting movement to the eyeball, and the inferior one arises near the anterior margin of the orbit, and hence gets the opposite effect without the intervention of a pulley arrangement. It is not to be understood that in eye movement these muscles work singly. Their action is very highly co-ordinated, even to the extent that in simple up-and-down movements of the eye there is co-operative effort of not only the obliques but also of the lateral and mesial recti.

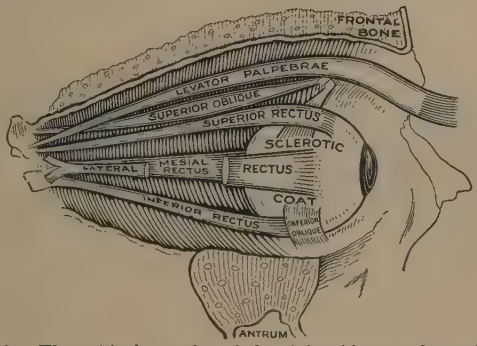

Fig. 390.—The orbital muscles of the right side seen from the side.

How the Eye Sees.—In the structure of the inner coat of the eye it was learned that the fibers connected with the cells of the retina come together at a common center and leave the eyeball as the optic nerve. At the spot where the fibers of the optic nerve leave the eyeball the retina is absent, and hence at this area of the retina there is an inability to see due to the fact that the power of reacting to light rays is located in the retina. The fact of the *blind spot*, as it is called, can be demonstrated by the following experiment: Place the left hand over the left eye and with the right eye look steadily at the cross in Fig. 391. Hold the book at a distance of about 8 inches from the eye. Still looking steadily at the cross, move the book nearer the eye until the white dot disappears. Then move it still nearer until the white dot appears again. Find the place at which the dot disappears from

vision for the right eye, then close the right eye and look steadily at the white dot with the left eye. Note that the cross is not seen. Move the book nearer or farther away and observe that it appears.

This simple experiment of demonstrating the blind spot illustrates not only this particular anatomic fact of the eye, but shows also the way in which rays of light give rise to what is called vision. When the rays of light from the dot fell upon the retina the dot was observed; when they fell upon the blind spot the dot was not there so far as visual senses were concerned. Therefore, vision is dependent upon light rays falling upon sensitive portions of the retina. When the cells of the retina are stimulated, impulses from this sensory receptor are then carried to the brain, and the person sees. Defects in vision may be due to (1) defects in the eye, (2) defects in the optic tract, or (3) defects in the brain.

Fig. 391.—Diagram to demonstrate presence of blind spot in the visual field. Fix the cross with the right eye; bring figure closer to eye until the white dot appears (Helmholtz).

Defects in the Eye.—At a distance of 20 feet or over rays of light come to a focus on the retina without any adjustment on the part of the eye. When objects nearer than 20 feet are observed the light rays are focussed by the accommodative action of the lens. When the light rays are brought to an exact focus on the retina, whether by accommodation or not, the eye is said to be *emmetropic*. *Emmetropia* means normal vision. When the light rays do not focus on the retina either because of structural defects or failure to make the proper accommodation, then the eye is said to be *ametropic*. *Ametropia* means abnormal vision. The optical defects of the eye constituting ametropia are:

1. Astigmatism, due to imperfect curvature of the cornea.
2. Presbyopia, due to diminished elasticity of the lens.
3. Myopia, and
4. Hyperopia, due to a lengthened or shortened eyeball.

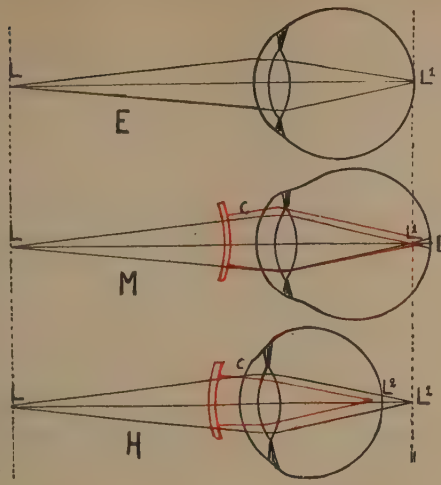

Fig. 392.—Diagram to illustrate the refraction in emmetropia and ametropia: *E*, Emmetropic eye in which luminous point *L* is brought to a precise focus upon the retina, L^1; *M*, myopic eye in which *L* is focalized in front of the retina, L^1; *H*, hypermetropic eye in which *L* is focalized in L^1 "behind" the retina. In *M* the use of a concave lens forces L^1 backward upon the retina, L^2, correcting the myopia, whereas in *H* the use of a convex lens forces L^1 forward upon the retina, L^2. (Burton-Opitz.)

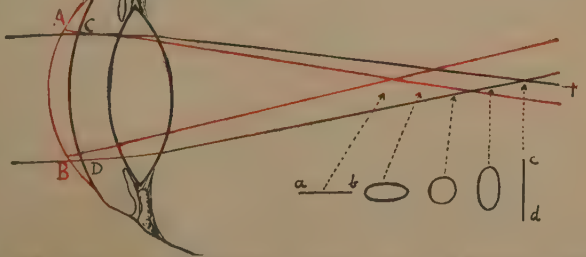

Fig. 393.—Diagram to illustrate the cornea of the rays in "with the rule" astigmatism: *AB*, Being the plane of greater curvature, its rays are brought to a focus nearer the lens than those traversing plane *CD* (Burton-Opitz).

The diagrams in Fig. 392 illustrate how the image falls in front of the retina in the myopic eye, behind the retina in the hyperopic eye, and Fig. 393 shows also the imperfect image resulting from astigmatism.

Defects in the Optic Tract.—The optic nerve of one side (see page 268) distributes fibers to half of each eye, so that each optic

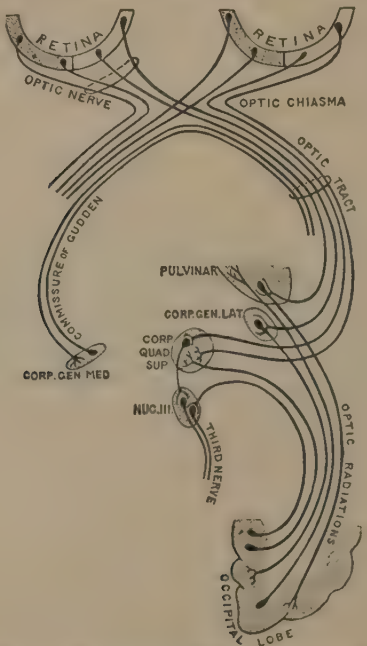

Fig. 394.—Diagram of the principal components of the optic apparatus (Cunningham).

tract is made up of fibers from the corresponding halves of each retina (Fig. 394). Any compression of the right optic tract, for example, behind the chiasma will produce loss of vision of the right half of each eye. Such a condition is known as *homonymous hemianopsia*. The completeness of the defect will depend upon the extent of the pressure and the number of fibers involved. If the lesion affect the chiasma then the fibers from the nasal side

f the eye will be involved and the hemianopsia will be heteronyous. In the former case the visionary defect will affect the nasal field; in this latter type it is the bitemporal field that is involved. If the lesion occur in front of the chiasma, then the defect would be restricted to the one eye. Pressure on the nerve may result from hemorrhage, tumor, or inflammatory exudate.

Defects in the Brain.—Immediately behind the chiasma the optic nerves enter the thalamus and form connections with the external geniculate body (Fig. 394) from which relay station the tract continues on as the optic radiation to the occipital lobe of the brain. Defects of vision may arise from injury to the deeper tracts or from disturbance in the visual area of the occipital lobes. Such injury or disturbance may come from hemorrhage, tumor, or inflammatory exudate.

The Senses of Hearing and Equilibrium.—The auditory organ performs a dual function—that of hearing and equilibrium. At first in the origin of the auditory organ, as in fishes, it is found close to the surface of the body, and is thus readily accessible to sound waves from without. In the higher animals it gradually assumes a deeper position comparable to that type seen in man in which accessory chambers and mechanisms have been developed to convey the ether vibrations to the auditory cells.

The first appearance of the auditory organ in the human embryo is a thickening of the ectoderm on the lateral walls of the brain area. This is followed by an invagination of the thickened cells with the subsequent formation of a pit, and then a sac, which loses its connection for a time with the surface of the body. The sac structures become developed into an upper and lower portion by a medial construction giving rise to two new parts, called the *utriculus* and *sacculus*. From the former develops the semicircular canals; from the latter arise the structures of the internal ear, **the organ of hearing.**

The other parts of the ear—the external ear, the canal, the middle ear, the eustachian tube—are concerned in conducting functions merely. The auditory nerve itself is distributed to the semicircular canals through its vestibular division, and the internal ear through its cochlear division. In description of the ear the anatomic division of external, middle, and internal ear will be followed.

The External Ear.—This is composed mainly of cartilage. Its convolutions are arranged to direct the sound waves toward the

opening, the *external auditory meatus*. The lower animals show instances of marked development of the upper portion of the ear producing a more effective sound-gathering apparatus. In lower animals also the muscles of the ear or *pinna* are quite extensively developed; in man they are present as small bands of tissue that for most individuals are functionless. The *external auditory*

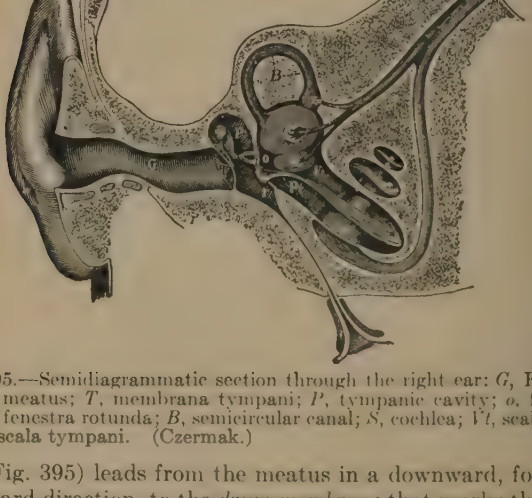

Fig. 395.—Semidiagrammatic section through the right ear: *G*, External auditory meatus; *T*, membrana tympani; *P*, tympanic cavity; *o*, fenestra ovalis; *r*, fenestra rotunda; *B*, semicircular canal; *S*, cochlea; *Vt*, scala vestibuli; *Pt*, scala tympani. (Czermak.)

canal (Fig. 395) leads from the meatus in a downward, forward, and inward direction, to the *drum membrane* that marks the limit of the canal. In length the canal is about 1 inch on its superior posterior surface and about $1\frac{3}{8}$ inches on its anterior wall. This disparity is due to the obliquity at which the drum membrane is stretched across the canal.

The canal is cartilaginous and membranous for the first third of its distance; the remaining portion is bony.* The lining membrane of the canal is skin, which possesses numerous fine hairs and many sebaceous glands on its outer cartilaginous portion. Along the entire length of the upper wall the skin shows many ceruminous glands which produce cerumen or ear wax.

* In the newborn child the outer part of the canal is cartilaginous. The inner part is fibrous, with a beginning ring of bone at the drum membrane. The fibrous portion becomes bone by the end of the first year and increases in amount until it forms two-thirds of the canal at puberty.

The Middle Ear.—There are three important parts to the middle ear: the *tympanic cavity*, the *mastoid cells*, and the *eustachian tube*. The tympanic cavity is the second section of the conducting apparatus. It lies within the temporal bone and contains three small bones, the *malleus*, the *incus*, and the *stapes*. The first is attached to the drum membrane, the last fits into an oval opening (fenestra ovalis) on the mesial wall, and the incus is articulated between the other two. On the mesial wall is another opening, the round window (fenestra rotundum). It is covered by membrane. It serves as an outlet for the vibrations that have been started at the oval opening. The cavity is lined with mucous membrane which is continuous with that of the eustachian tube.

Above and somewhat posterior to the cavity is the opening into the mastoid cells. The entrance is called the *antrum*, which is a small foyer leading to the open spaces in the mastoid process of the temporal bone. The significance of the mastoid cells is clearly not one of audition. They are significant because of the liability of infection of this cancellous bone tissue by extension of disease from the tympanic cavity.

The eustachian tube leads from the middle ear to the nasopharynx. For part of its distance it lies in bone and for part its wall is composed of cartilage and membrane. In the adult it is about 37 mm. ($1\frac{1}{2}$ inches) in length and its diameter at the smallest portion is about 3 mm. It is lined with mucous membrane which is continuous with that of the tympanic cavity and the pharynx. Its surface cells are of a ciliated columnar type with numerous goblet-cells distributed along its course. The tube serves for the transmission of air, and hence is the medium for the equalization of pressure maintaining the same pressure in the middle ear that exists on the outside of the drum membrane.

The Internal Ear.—The external and middle ear are concerned merely with the conduction to the internal ear of sound waves initiated in the ether. The folds and curves of the pinna collect these waves and direct them into the external auditory meatus, from which point they are carried through the canal until they strike upon the drum membrane. The vibration of this membrane sets in motion the bony ossicles, the malleus, incus, and stapes, and the last one is so placed on the wall of the internal ear that the vibration at this point marks the stimulus which will ultimately arouse the receptor cells of the internal ear to activity.

Two Parts of the Internal Ear.—The internal ear comprises two parts, one concerned with equilibrium, the other with hearing. The latter function is secured through a complicated apparatus arranged in a spiral-shaped cavity, the *cochlea*. This cavity in the temporal bone is filled with lymph called *perilymph*, and in this lymph floats a *membranous cochlea* which is a duplication of the bony structure. Finally, within the membranous cochlea is lymph, called *endolymph*. The cells concerned

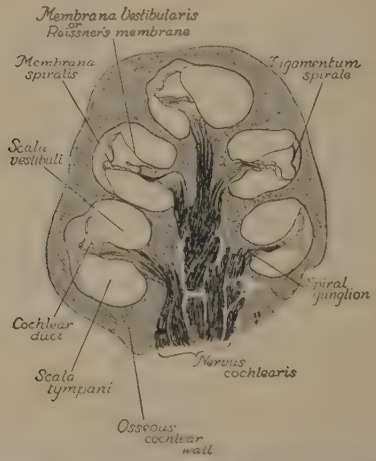

Fig. 396.—Diagram of the cochlea showing five sections of the canal (modified after Sobotta and Huber).

with the reception of the sound waves are arranged in a group, called the *organ of Corti*. A section of the cochlea will show (Fig. 396) five openings of the bony cochlea because the spiral tube is coiled two and a half times upon itself. In the spiral core of the bony cochlea is to be noted a process of bone to which the membranous cochlea is attached. A larger view of one section (Fig. 397) shows three main divisions, two large ones containing perilymph, and known as the *scala vestibuli* and the *scala tympani*, and a small one containing endolymph, called the *cochlear canal*.

The membranous cochlea begins near the opening for the stapes, the *fenestra ovalis*, and ends after a spiral turn of two and a half times. Its conspicuous part is the organ of Corti, the real

Fig. 397.—Diagram of a transverse section of the cochlea: *Sc. V*, Scala vestibuli; *Sc*, scala tympani; *C*, *Chl*, cochlear canal; *Gg.sp.*, spiral ganglion; *n.aud.* auditory nerve; *m.R*, membrane of Reissner; *m.b.* basilar membrane; *Org.C*, organ of Corti; *m.t.* tectorial membrane. (After Foster.)

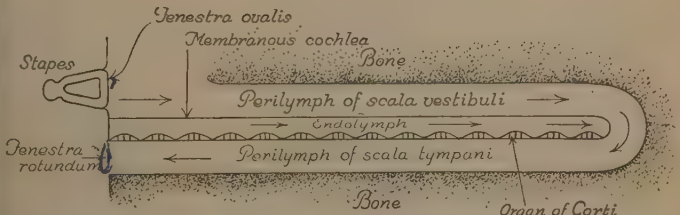

Fig. 398.—Diagram of the bony and membranous cochlea straightened out to show relations of perilymph and endolymph to the organ of Corti.

organ of hearing. This consists of groups of cells containing cilia on their free margin. Over them projects an arm-like process, the *membrana tectoria*. Separating the scala vestibuli from the cochlear canal is *Reissner's membrane*. The cochlear division of the auditory nerve reaches the organ of Corti through the internal auditory canal.

How the Ear Hears (Fig. 398).—The stimulation of the organ of Corti is brought about by the vibration that is communicated to

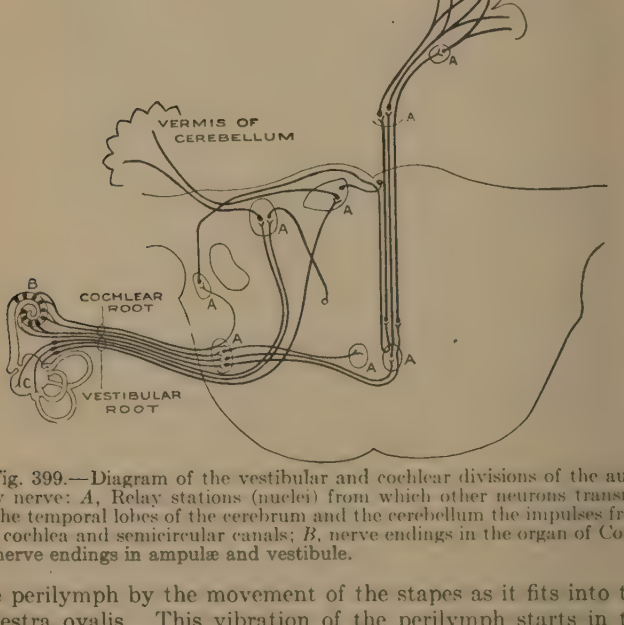

Fig. 399.—Diagram of the vestibular and cochlear divisions of the auditory nerve: *A*, Relay stations (nuclei) from which other neurons transmit to the temporal lobes of the cerebrum and the cerebellum the impulses from the cochlea and semicircular canals; *B*, nerve endings in the organ of Corti; *C*, nerve endings in ampulæ and vestibule.

the perilymph by the movement of the stapes as it fits into the fenestra ovalis. This vibration of the perilymph starts in the scala vestibuli and continues over that course to descend over the scala tympani. The fenestra rotundum permits the vibratory movement to expend itself, and hence prevents any back vibrations that would disturb the course of those coming in at the fenestra ovalis. The cochlear canal is separated from the scala vestibuli by only a thin sheet of tissue—Reissner's membrane.

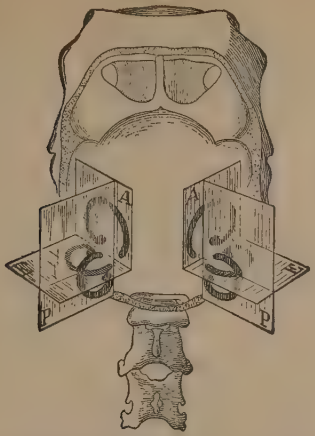

Fig. 400.—Figure showing the position of the three semicircular canals in the skull of the pigeon (Ewald).

Fig. 401.—Reconstruction of left membranous labyrinth of human embryo of ten weeks, lateral aspect (Streeter).

Hence any movement of the perilymph is easily communicated to the endolymph. Vibration of the endolymph sets in motion the membrana tectoria, causing it to move up and down upon the hair-like processes of the organ of Corti. Apparently it is this



Fig. 402.—To illustrate the illusion of subdivided space (Burton-Opitz).



Fig. 403.—To illustrate the overestimation of vertical lines (Burton-Opitz).

movement that stimulates the receptor cells of the auditory nerve, giving rise to impulses that are then relayed to the brain.

The pathway to the temporal lobes of the brain shows several synapses in its course (Fig. 399). Impulses started on the left side in the left internal ear are taken to the right side of the brain. Study of the accompanying figure will indicate the course of the

fibers that pass from the semicircular canals to the cerebellum, which is very vitally concerned with equilibrium.

The Semicircular Canals.—There are three canals—superior, posterior, and horizontal ones. They are perpendicular to one

Fig. 404.—Zöllner's lines (Burton-Opitz).

another (Fig. 400). The canals are developments from the utricle, and near the utricle each canal shows a bulbous-like swelling, the *ampulla* (Fig. 401). The ampullæ show numerous ridges on their inner surfaces, composed of cells of varying height and bearing hair-like processes on their free margins. The

Fig. 405.—Müller-Lyer figures to show illusion in space perception. The lines *A* and *B* are of the same length (Burton-Opitz).

cavity of the canals is filled with endolymph, and the movement of the endolymph in the ampullæ is the principal factor in arousing impulses for the vestibular division of the auditory nerve. Any movement of the head causes a movement of the

endolymph in the ampullæ, and hence a stimulus that is conveyed to the cerebellum, co-ordinating doubtless with impulses from the muscles which give the muscle sense.

PRACTICAL EXERCISES

1. Examine the skin of the palm, forearm, and face. Note distinguishing characteristics.
2. Cross the index- and middle fingers of one hand and roll a shot or small pea between these crossed finger tips. Explain the sensation.
3. Examine a hair under high and low powers of the microscope.
4. It has been stated that "seeing is essentially a process of reasoning in accordance with past experience." With this in mind explain the optical illusions in Figs. 402–405.
5. Examine an ox eye, and note the cornea, iris, and sclera. Make a coronal section. Examine the retina.
6. Use a Vision Chart* and examine the visual acuity of students in the class.
7. The eye adjusts for seeing near and far objects. To see near objects the lens becomes more convex by contraction of the ciliary muscle which releases the tension of the suspensory ligament, allowing the elastic lens to bulge. This act is known as accommodation. Draw diagrams showing the effect on light rays of accommodation.

QUESTIONS

1. What is a receptor of the nervous system? Name several.
3. Describe the skin and its appendages.
3. Does a wart come from handling toads?[3]
4. Explain the loss of pigment in the hair.[4]
5. In what two ways do light rays affect animals? Do both ways act in man? Explain.
6. Describe the structure of the eye.
7. What is cataract of the eye?
8. Explain the anatomy of the ear with reference to the statement that cold in the head may result in mastoiditis.

REFERENCES FOR FURTHER STUDY

1. Guthrie, L. G.: Functional Nervous Disorders in Childhood, Oxford Univ. Press, 1909, pp. 24–37.
2. Loeb, J.: Forced Movements, Tropisms, and Animal Conduct, J. B. Lippincott Co., Philadelphia, 1918, pp. 47–112.
3. Williams, J. F.: Healthful Living, The Macmillan Co., New York, 1919, p. 28.
4. Burton-Opitz, R.: Text-book of Physiology, W. B. Saunders Co., Philadelphia, 1920, pp. 893, 894.

* Charts, 33 x 12 inches, may be secured for 14 cents in stamps from the Eye sight Conservation Council, Inc., Times Bldg., New York City.

GLOSSARY

A

Ab-do'men. The part of the body between the thorax and pelvis.
Ab-dom'i-nal. Pertaining to the abdomen.
Ab-du'cent. The sixth cranial nerve.
Ab'scess. A localized collection of pus in any part of the body, usually due to injury or infection from bacteria.
Ac-e-tab'u-lum. Cup-shaped cavity in the innominate bone receiving the head of the femur.
Ac-i-do'sis. Increased acidity of the blood.
A'ci-nus. A group of cells forming a small lobule of a compound gland.
Ac-quired'. Obtained after birth; not congenital.
Ac-ro-meg'a-ly. A disease marked by enlargement of the tissues of the face, hands, and feet.
A-cro-mi-o-cla-vic'u-lar. Pertaining to the acromion and clavicle.
A-cro'mi-on. A roughened process of the spine of the scapula, forming the point of the shoulder.
Ad'di-son's dis-ease'. Tuberculous disease of suprarenal glands with anemia of the blood, and brownish discoloration of the skin.
Ad-duc'tor bre'vis. One of the adductor muscles in the mesial portion of the thigh.
Ad-duc'tor lon'gus. One of the adductor muscles in the mesial portion of the thigh.
Ad-duc'tor mag'nus. One of the adductor muscles in the mesial portion of the thigh.
Ad-duc'tor tu'ber-cle. A roughened process of bone on the mesial condyle of the femur, giving attachment to the adductor magnus.
Ad'e-nase. A ferment found in the spleen, pancreas, and liver.
Ad-e-ni'tis. Inflammatory enlargement of a lymph-node.
Ad'e-noid. 1. Resembling a gland. 2. Used to name a mass of lymphoid tissue in the naso-pharynx.
Ad'i-pose. Fatty.
Ad-o-les'cence. Period of youth between 12–14 to 21–23 in girls and 13–15 to 23–25 in boys.
Ad-re'nal. A gland of internal secretion capping the upper end of the kidney; also called suprarenal.
Ad-re'na-lin. An extract from the adrenal gland, acting to constrict blood-vessels, to control hemorrhage and to raise blood-pressure.
Af'fer-ent. Conducting inwards to a part or organ, as afferent nerves that carry impulses to the spinal cord or brain.
Al-bu-mi-nu'ri-a. Presence of albumin in the urine.
Al'co-hol. A colorless, volatile, inflammable liquid, C_2H_5OH.
Al-i-men'ta-ry. Serving as food; alimentary canal: food passageway.
Al-lan-to'ic. Pertaining to the allantois.
Al-lan'tois. A membranous receptable for the excretory apparatus during the early period of embryonic life.

Al-ve'o-lus, (pl. alveoli). A little hollow or small depression.
A-me'boid movements. Changes of shape peculiar to amebae.
A-men-or-rhe'a. Absence, or abnormal stoppage, of the menses.
Am-e-tro'pi-a. Imperfect refractive powers of the eye.
Am-e-trop'ic. Pertaining to ametropia; abnormal vision.
Am-i-to'sis. Direct cell division in which there are no preliminary changes in the nucleus.
Am'ni-on. Innermost fetal membrane, with the bag of waters.
Am-phi-ar-thro'sis. A movable joint with limited motion.
Am-phib'i-ans. A class of animals living both on land and in water, i.e., the frog.
Am'pli-tude. Largeness; scope; range.
Am-pul'la. Flask-like dilatation; i.e., the dilated end of the semi-circular canal of the ear.
Am-y-lo-lyt'ic. Effecting the digestion of starch.
Am-y-lop'sin. One of the pancreatic ferments.
A-nab'o-lism. The process of food-assimilation into the cells.
A'nal. Relating to the distal end and outlet of rectum.
A-nal'o-gous. Corresponding in function.
An-a-phy-lax'is. A condition of sensitiveness to a drug or protein following ingestion or injection of the particular substance.
A-nas-to-mo'sis. The union of one vessel with another belonging to a different arterial division.
A-ne'mi-a. Decrease in hemoglobin in cells, resulting in deficient quality of blood.
An-es-the'si-a. Loss of feeling or sensation.
An-es'the-tize. The act of inducing anesthesia.
An-ter'i-or com'mis-sure. A band of fibres crossing from one side of the spinal cord to the other, in front.
An-te-ro-pos-te'ri-or. Extending from before backward.
An-te-ver'sion. A forward displacement of an organ, usually used in relation to the uterus.
An-thro-pol'o-gy. The science of mankind in general.
An'-ti-body. A chemical protective substance in the plasma.
An-ti-sep'tic. Tending to prevent the growth of bacteria; used generally in such strength that will produce this effect without irritating the cells of the body.
An-ti-tox'in. Any one of certain chemical compounds in the blood that has the power of neutralizing a toxin; commonly employed to designate diphtheria anti-toxin.
An'trum. A cavity in a bone.
An'trum of High'more. A cavity in the bone of the upper jaw.
A'nus. The distal end and outlet of rectum.
A-or'ta. The great artery springing from the left ventricle.
A-or'tic sem-i-lu'nar valves. Valves of half-moon shape between the left ventricle of the heart and opening of the aorta.
Ap'er-ture. An open space or gap.
A-pha'si-a. Defect or loss of power of expression by speech, writing or signs.
Ap-ne'a. The cessation of respiration.
Ap-o-neu-ro'sis. A thick, strong, tendinous membrane which may cover or serve as the attachment of muscles.
Ap-o-neu-rot'ic. Pertaining to aponeurosis.
Ap'o-plex-y. A sudden loss of consciousness, sensation and voluntary motion, usually caused by the rupture of a cerebral artery.
Ap-pen-dic'u-lar. Referring to the appendages of the skeleton: arms and legs.

Aq'ue-duct of Syl'vi-us. A canal connecting third and fourth ventricles of the brain.

A'que-ous. Watery.

A-rach'noid. 1. Like a spider's web. 2. A thin membrane between the dura and pia mater of the spinal cord and brain.

A-re'o-lar tissue. A variety of connective tissue.

Ar'gi-nase. A ferment in the liver that splits up a protein arginin, $C_6H_{14}N_4O_2$.

Ar-te'ri-ole. The smallest division of the artery before termination into the capillary.

Ar'te-ry An efferent blood-vessel.

Ar-tic'u-lar. Pertaining to a joint.

Ar-tic-u-la'tion. A joint or arthrosis formed by bones, characterized by smooth surfaces.

As-phyx'i-a. Apparent death due to deficiency of oxygen and excess of carbon dioxid in the blood.

As-so-ci-a'tion. 1. Union or bond. 2. Used to describe neurons that connect afferent with efferent units.

Asth-mat'ic. Pertaining to asthma.

As-tig'ma-tism. Imperfect curvature of the cornea.

As-trag'a-lus. One of the bones of the tarsus of the foot, articulating with the tibia and fibula.

A-tax'i-a. Failure of muscular coordination.

At'las. First cervical vertebra.

At-ri-o-ven-tric'u-lar. Pertaining to the auricle and ventricle.

At-ri-o-ven-tric'u-lar bundle. A band of nerve fibres passing from the opening of the superior cava in the wall between the left and right side of the heart to the end in the papillary muscles of the ventricles. Also called the Bundle of His.

At'ro-phy. Diminution of size.

Au'di-to-ry me-a'tus. The opening or passage-way of the ear.

Au'ri-cle. 1. The upper chamber on either side of the heart. 2. The flap of the ear.

Au-ric'u-lar fi-bril-la'tion. A disorganized and irregular action of the heart characterized by the systole of the auricles unrelated to the ventricles.

Au'ta-coid. Any internal secretion.

Au-to-ma-tic'i-ty. The quality of inherent power to act.

Au-to-nom'ic. Having the power of self-direction.

Ax'i-al. Referring to that part of the skeleton comprised by spine, thorax, skull: the central body of the skeleton.

Ax'il-la-ry. Pertaining to the armpit.

Ax'on. A long process of the nerve cell that forms a distinct branch.

Az'y-gos. Any unpaired part.

B

Ba-bin'ski's reflex. A well-known reflex elicited by stimulation of the sole of the foot.

Bar'tho-lin's glands. Two round glands in either side of the vaginal orifice. Named after the Danish physician, Kaspar Bartholin.

Ba'sal me-tab'o-lism. The chemical changes in cells uninfluenced by exercise or food.

Bas'i-lar. Pertaining to the base; basilar artery: located at the base of the brain.

Ba'so-phil. A white cell of the blood which takes a basic or alkaline stain and shows blue granulations.

Bi'ceps. Having two heads; a muscle of the arm.
Bi-cip'i-tal. Referring to the biceps.
Bi-cus'pid. 1. Having two cusps or two pointed processes. 2. Used especially to describe the crown of a tooth.
Bi'ped. Having two feet.
Blad'der. The membranous sac which contains the urine.
Blood pres'sure. The force of the blood within the arterial vessels.
Bo'lus. A rounded mass.
Bow'man's capsule. The invaginated portion of the beginning of the uriniferous tubule. Named after Sir W. Bowman, English surgeon.
Bra-chi-a'lis an-ti'cus. A muscle of the arm (brachium) on the anterior aspect.
Bran'chi-al. Pertaining to gills.
Bron'chi-ole. A minute division of a bronchus.
Bron'chus, (pl. bronchi). Either one of the two main branches of the trachea.
Bundle of His. Same as the artrioventricular bundle.
Bur'sa. A sac or pouch.
Bur'sal. Pertaining to a bursa.
Bur-si'tis. Inflammation of a bursa.
But'tock. The gluteal prominence or a lateral half of the same.

C

Cal-ca'ne-o-cu'boid. Pertaining to the calcaneum and cuboid.
Cal-ca'ne-o-scaph'oid. Pertaining to the calcaneum and scaphoid.
Cal-ca're-ous. Containing lime.
Cal'cu-lus, (pl. calculi). A stone-like concretion in any organ.
Ca'lyx, (pl. calices). A cup-like division of the pelvis of the kidney.
Cal'lus. The osseous material by which union between ends of a fractured bone is effected.
Cal'o-rie. Amount of heat required to raise one kilogram of water from 15 to 16 degrees centigrade.
Can'cel-lous. Having a spongy structure.
Cap'il-la-ry. The smallest division of the vascular system.
Cap-i-tel'lum. The rounded eminence on the humerus for the articulation of the radius.
Cap'su-lar. Pertaining to a capsule.
Cap'sule. A fibrous membrane enclosing a part or organ such as the capsular ligament of a joint or the capsule of the kidney.
Ca'put me-du'sae. A circle of dilated veins surrounding the umbilicus.
Car-bo-hy'drate. A compound containing carbon combined with hydrogen and oxygen.
Car'bon di-ox'id. CO_2, a gas formed by two parts oxygen to one part carbon.
Car'di-a. The upper orifice of the stomach.
Car'di-ac. Pertaining to the heart.
Car'di-ac cen'ter. A group of nerve cells located in the medulla, controlling the action of the heart.
Car'di-ac cy'cle. A term used to describe a series of events in the action of the heart occurring between two successive systoles.
Car'di-ac plex'us. A mass of nerve tissue and nerve cells located on the great vessels leaving the heart.
Ca'ri-es. Decay of animal tissue.
Ca-rot'id. Either one of the two main right and left arteries of the neck.
Car'pus. The wrist, comprised of eight bones.

Car'til-age. The white elastic substance attached to articular bone-surfaces, or to the ends of bones.

Cast. A structure formed in the lumen of a kidney tubule that results from inflammatory condition of the kidney cells.

Cat'a-ract. An opacity of the crystalline lens of the eye.

Cat'e-go-ry. Classification.

Cath'o-dal. Pertaining to the negative electrode or pole of an electric circuit.

Ca'val. Pertaining to the large vein that enters the heart, either the superior or the inferior cava.

Ce'li-ac. Pertaining to one of the large abdominal regions of the aorta.

Cel-lu-li'tis. Inflammation of cellular tissue.

Cel'lu-lose. An inert substance constituting the chief part of plants.

Cen'tro-some. A small body within the cytoplasm which takes a part in cell division.

Cer-e-bel'lum. A division of the brain located at the base of the skull.

Cer'e-bral. Pertaining to the cerebrum.

Cer-e-bro-spi'nal. Pertaining to the brain and spinal cord.

Cer'e-brum. The anterior and larger part of the brain.

Ce-ru'men. Ear-wax.

Cer'vi-cal. Pertaining to the neck.

Cer'vix. A neck or constricted portion of an organ.

Cha'lone. An autacoid that inhibits cellular activity.

Chey'ne-Stokes breathing. A form of breathing marked by a gradual increase in the number of respirations, followed by gradual decrease. Described first by two English physicians, Doctors Cheyne and Stokes.

Chi-as'ma An intersection.

Chlo'ro-form. A volatile liquid, $CHCl_3$; anesthetic.

Chlo-ro'sis. Condition in which the hemoglobin is reduced in amount, the number of red cells being normal.

Chor'dæ ten-din'e-æ. The tendinous strings joining the papillary muscles of the heart with the valves.

Cho-re'ic. Pertaining to chorea.

Cho'roid. The middle coat of the eyeball.

Chro'ma-tin. Substance within the nucleus that stains deeply with basic stains.

Chro'mo-phil. Any easily stainable structure.

Chro'mo-some. One of the small bodies into which the chromatin of a cell-nucleus divides at the time of the mitotic division of the cell.

Cil'i-a-ry. 1. Pertaining to or like the eyelashes. 2. Used to name a body in the eye to which the lens is attached.

Cil'i-at-ed. Provided with waving hair-like processes.

Circle of Willis. An anastomosis of blood-vessels at the base of the brain.

Cir'cu-la-to-ry. Pertaining to the circulation.

Cir-cum-val'late. Surrounded by a ridge or elevation, as certain papillae of the tongue.

Clav'i-cle. A bone of the shoulder girdle shaped like a Roman key.

Cleft pal'ate. An abnormal condition of the palate at birth, due to failure of the mouth roof to completely close.

Cli-mac-ter'ic. The turn of life, especially the menopause.

Clit'o-ris. A small organ in the upper part of the vulva.

Clo-a'ca. A common tube for intestinal, urinary, and generative secretions present in lower animals and early embryonic stages of man.

Co-ag-u-la'tion. Formation of a clot.

Co-a-les'cence. Act or state of fusion.

Coc-cyg'e-al. Pertaining to the small bone below the sacrum.

Coc-cyg'e-us. A muscle of the pelvic floor.

Coc'cyx. Small bone below the sacrum.
Coch'le-a. Spiral cavity of the internal ear.
Coch'le-ar canal. The cavity of the cochlea.
Col-lat'er-al. A lateral communication branching from an axon.
Col'le's fracture. A fracture of the lower end of the radius with backward displacement of the lower fragment. Named after G. Colle, an Italian physician.
Col'loid. A gelatinous substance diffusing very slowly or not at all through animal or vegetable membrane.
Co'lon. The large part of the intestine which extends from the cecum to the rectum.
Co-lum'nar. Like a column.
Com-mis'su-ral. Pertaining to a connecting band or union of tissue.
Con-cen'tric. Pertaining to the center.
Con'dyle. A rounded swelling at an articular extremity.
Con'flu-ent. Running together; becoming merged in one.
Con-gen'i-tal. Existing at or before birth.
Con-junc-ti'val. Pertaining to a sac or mucous membrane which lines the inner surface of the eyelids.
Co'nus. A cone.
Con-vo-lu'tion. A torturous or coiled structure.
Co-or-di-na'tion. The act of regulating and combining so as to give harmonious results.
Cor-a-co-brach-i-a'lis. A muscle extending from the coracoid process to the shaft of the humerus.
Cor'a-coid. 1. Like a crow's beak. 2. A process of the scapula.
Co'ri-um. The layer of skin containing blood vessels, nerves and sometimes lymphoid cells.
Cor'ne-a. The transparent anterior part of the eye.
Cor'nu (pl. cor'nu-a). A horn-shaped structure.
Cor'o-nal. Having a crown or wreath-like structure.
Cor'o-na-ry. 1. Encircling in the manner of a crown. 2. The name of the intrinsic arteries of the heart.
Cor'o-na-ry si'nus. A large vein of the heart which receives numerous small veins from the heart muscle.
Cor'o-noid. Resembling the beak of a crow, as the coronoid process of the jaw and of the ulna.
Cor'pus cal-lo'sum. The great commissure of the cerebrum.
Cor'pus lu'te-um. A yellow mass in the ovary remaining after the discharge of an ovum.
Cor'tex. Outer layer or segment.
Cos'tal. Pertaining to a rib; costal cartilages: cartilages which prolong the ribs anteriorly.
Cra'ni-um. The part of the skull containing the brain.
Cre'a-tin. A chemical substance found in muscle.
Cre-at'i-nin. A protein substance formed from creatin by elimination of water. It occurs naturally in muscle tissue and urine.
Cre-mas'ter. The muscle by which the testicle is supported.
Cre'tin-ism. Improper development due to the absence of the thyroid secretion.
Cru'ci-al. Formed like a cross.
Crus, (pl. crura). A leg-like structure.
Crus-ta'ce-a. A class of hard-shelled animals, including lobsters, crabs, wood-lice, water-fleas, etc.
Crypt. A hidden recess or chamber, applied to glands, tubes, and cavities.
Crys'tal-line. Resembling a crystal; crystalline lens: the lens of the eye.
Cu'boid. Bone on the lateral aspect of the foot.

Cu-boi'dal. Shaped like a cube.
Cu-ne'i-form. 1. Wedge-shaped. 2. A bone of the wrist and three bones of the foot
Cus'pid. A canine tooth. A pointed projection.
Cu'ti-cle. The outer layer of the skin; epidermis.
Cys'tic. Relating to the gall or urinary bladder.
Cys-ti'tis. Inflammation of the bladder.
Cy'to-plasm. The protoplasm of the cells exclusive of the nucleus.

D

De-am-i-niz'ing. Liberation of ammonia from an amid.
De-cus-sa'tion. The point of crossing.
Def-e-ca'tion. Discharge of the feces.
De-gen-er-a'tion. Alteration of tissue from a higher to a lower form.
Deg-lu-ti'tion. The process of swallowing.
Del'toid. A muscle on the shoulder shaped like the Greek letter Delta.
Dem'i-lune. Small crescentic groups of granular deeply staining cells in the alveoli of mucous glands.
Den'drite. A branching protoplasmic process from a nerve-cell.
Den-drit'ic. Tree-like in appearance or form.
Den'tin. The chief substance of the tooth, forming the body, neck, and roots.
Den'tin-al tu'bules. The tubular structures of teeth.
Den-ti'tion. 1. The process of cutting the teeth. 2. Kind, number and arrangement of the teeth.
Der'ma. The skin.
De-ter'min-ers. Chromosome influences which determine the development of any particular character.
Di-a-be'tes. A disease characterized by the inability of the individual to burn sugar and by the appearance of sugar in the urine.
Di-al'y-sis. The separation of crystalloids and colloids in solution by means of their unequal diffusion through certain natural or artificial membranes.
Di'a-phragm. A muscular partition between the thorax and abdomen.
Di-aph'y-sis. The shaft or main part of a bone.
Di-ar-rhe'a. An abnormally frequent and profuse discharge of feces from the bowels.
Di-ar-thro'sis. A joint characterized by mobility in any direction.
Di-as'tole. The relaxation of the heart; opposed to systole.
Dif-fu'sion. A process whereby the particles of substances forming a solution tend to become uniformly mingled.
Dip'lo-ë. Soft, spongy bone tissue between the two tables of the skull.
Di-ver-tic'u-lum. A cecum: pouch or sac.
Dom'in-ant. The stronger of mutally antagonistic parental characters.
Dor-sa'lis pe'dis. An artery on the dorsal aspect of the foot.
Duct. A tube or passage-way.
Duc'tus ar-ter-i-o'sus. Fetal blood-vessel which joins the aorta and pulmonary artery.
Duc'tus ve-no'sus. An embryonic vessel that shunts arterial blood into the inferior vena cava.
Du-o-de'num. The first part of the small intestine below the stomach, so-called because its length is about twelve fingers' breadth.
Du'ra ma'ter. The outermost membrane of the brain and spinal cord.
Dy-na-mom'e-ter. An instrument for testing muscular force.
Dys-pha'gi-a. A difficulty in swallowing.
Dysp-ne'a. Labored or difficult breathing.

E

Ec-cen'tric. Away from the center.
Ec'to-derm. Outer primitive layer of the embryo.
E-dem'a. Swelling due to effusion into connective tissue.
E-den'tu-lous. Without teeth.
Ef-fec'tors. The specialized endings on the terminal arborizations of nerve-cells.
Ef'fer-ent. Conveying outward or discharging, as nerve-cells that carry impulses from the spinal cord and brain.
Ef-fu'sion. Escape of a fluid into a part.
E-jac'u-la-to-ry duct. Duct which conveys semen to the urethra.
E-las-mo-bran'chi-i. A class of fishes of which the shark is an example.
E-lec-tro-car'di-o-gram. A graphic representation of the electrical variation of the heart's action.
E-lec-tro-car'di-og-ra-phy. The process of recording the electric current emanating from heart muscle.
Em'bol-us. A clot which obstructs a blood-vessel.
Em-bry-ol'o-gy. The science that describes the development of the individual from the egg stage to birth.
Em-bry'o-nal. Pertaining to an embryo.
Em-me-tro'pi-a. Perfect visual refraction.
Em-me-trop'ic. Having normal vision.
Em-py-e'ma. Pus in the chest between the two layers of the pleura.
E-mul-si-fi-ca'tion. The process of dividing fat in a solution into minute particles.
E-nam'el. The white investment of the crown of a tooth.
En-ceph'al-o-cele. Protrusion of the brain through the skull.
End bulbs of Krauss. Receptors of afferent nerves.
En-do-car-di'tis. Inflammation of the lining membrane of the heart and particularly of the valves.
En-do-car'dium. Lining membrane of the heart.
En-do-chon'dral. Pertaining to the formation of bone from cartilage.
En'do-crine. Applied to organs whose function is to secrete into the blood or lymph a substance which plays an important part in metabolism, growth and development.
En'do-lymph. The fluid within the inner ear.
End organs of Ruf-fi'ni. Receptors of afferent nerves.
En-dos'te-um. Lining membrane of a hollow bone.
En-do-the'li-um. Cell of mesodermic origin, lining the walls of the heart chamber, the lymph- and blood-vessels.
En'e-ma, (pl. enemata). A liquid preparation injected into the rectum.
En'si-form. 1. Shaped like a sword. 2. The lower section of the sternum.
En-ter-o-ki'nase. An enzyme of the small intestine.
En'to-derm. The inner layer of the primitive embryo.
En-u-re'sis. Involuntary discharge of urine.
En'zyme. A chemical ferment formed in the body. See "Ferment."
E-o-sin'o-phil. A white blood-cell which takes an acid stain and shows red granulations.
Ep-e-the'li-al. Pertaining to the covering of the skin and mucous membranes consisting of cells of varying form.
Ep-i-der'mis. The outermost layer of the skin.
Ep-i-did'y-mis. A torturous and twisting tube leading from the testicle.
Ep-i-gas'tri-um. Abdominal surface in front of the stomach.
Ep-i-glot'tis. Cartilaginous lid of larynx.
Ep-i-neu'ri-um. The outer connective tissue of a nerve-trunk.

Ep-i-phys'e-al cartilage. Strip of cartilage between the epiphysis and main portion of the bone.
Ep-iph'y-sis. The end of a long bone.
Ep-i-plo'ic ap-pen'dages. Tabs of fat covered with peritoneum attached to the colon.
Ep-o-öph'o-ron. A rudimentary organ lying in the broad ligament of the uterus.
E-qui-lib'ri-um. A state of balance.
E-rec'tor spi'nae. Paired muscles in the back.
E-rep'sin. A ferment of the small intestine.
E-ryth'ro-cyte. Red blood corpuscle.
E-so-phag'e-al. Pertaining to the esophagus.
E-soph'a-gus. The gullet; a musculo-membranous canal extending from the pharynx to the stomach.
E'ther. A volatile, inflammable liquid $(C_2H_5)_2O$, used as a solvent of fats and chiefly as an anesthetic.
Eth'moid. 1. A small bone forming the upper wall of the nasal passage-way. 2. The term also refers to a sinus in this bone.
Eth-moi'dal. Pertaining to the ethmoid.
Eup-ne'a. Easy or normal respiration.
Eu-sta'chi-an tube. Canal leading from the middle ear to the pharynx.
E-vac-u-a'tion. A process of emptying.
E-ver'sion. A turning out, or inside out.
Ex-cre'ta. Excretions or excremental matter.
Ex'cre-to-ry. Pertaining to excretion.
Ex-oph-thal'mic goiter. Disease characterized by protrusion of the eyes, rapid heart, loss of weight and enlargement of the thyroid.
Ex-pi-ra'tion. The process of removing air from the lungs.
Ex-ten'sor bre'vis pol'li-cis. A small extensor muscle of the thumb.
Ex-ten'sor car'pi ra-di-a'lis bre'vi-or. A short extensor of the carpal bone on the radial side of the hand.
Ex-ten'sor car'pi ul-na'ris. An extensor of the carpal bone on the ulnar side of the arm.
Ex-ten'sor com-mu'nis dig-i-to'rum. The common extensor of the fingers.
Ex-ten'sor in'di-cis. The extensor of the index finger.
Ex-ten'sor lon'gus dig-i-to'rum. The long extensor of the toes.
Ex-ten'sor lon'gus hal-lu'cis. The long extensor of the great toe.
Ex-ten'sor lon'gus pol'li-cis. The long extensor of the thumb.
Ex-ten'sor min'i-mi dig'i-ti. The extensor of the little finger.
Ex-ten'sor os'sis met-a-car'pi pol'li-cis. The extensor of the metacarpal bone of the thumb.
Ex-ter'nal in-ter-cos'tals. Small muscles between the ribs, external to another set: the internal intercostals.
Ex-ter'nal ob-lique'. A large muscle on the lateral aspect of the abdomen.
Ex-ter'nal os. The external opening of the cervix.
Ex-tir-pa'tion. The process of removal or cutting out of a part of the body.
Ex-trav'a-sa-tion. The escape of any fluid from its proper vessel into the tissues.
Ex'u-date. A discharge of fluid.

F

Fal'ci-form. 1. Shaped like a sickle. 2. Falciform ligament: the broad ligament of the liver.
Fal-lo'pi-an tubes. Tubes serving to convey the ovum from the ovary to the uterus. Named after Fallopio, a physican of Modena.

Falx cer'e-bri. A sickle-shaped portion of the dura mater between the two hemispheres of the brain.
Fas'ci-a. A band of connective tissue covering and supporting or binding parts together.
Fat'ty acid. Any one of the series of saturated acids having the general formula, $C_nH_{2n}O_2$.
Fem'o-ral. Pertaining to the femur.
Fe'mur. The thigh bone.
Fe-nes'tra o-va'lis. An oval opening in the mesial wall of the middle ear.
Fe-nes'tra ro-tun'da. Round opening in the mesial wall of the middle ear.
Fer'ment. A substance which causes physical or chemical change in other substances without entering into the reaction.
Fer-til-i-za'tion. Impregnation; fecundation.
Fe'tus. Embryonic development after end of third month.
Fi'bril. A minute fiber.
Fi'brin. A whitish fibrous material produced from fibrinogen of the blood by action of thrombin in the process of clotting.
Fi-brin'o-gen. A protein substance in the blood which is changed to fibrin.
Fil'a-ment. A delicate fibre or thread.
Fil'i-form. 1. Shaped like a thread. 2. Filiform papillae: minute papillae of the tongue, tipped by slender processes.
Fim'bri-a. A fringe; the fringe-like ending of the Fallopian tubes.
Fis'sure of Ro-lan'do. The cleft between the parietal and frontal lobes. Named after L. Rolando, Italian anatomist.
Fis'sure of Syl'vi-us. The cleft which separates the frontal and parietal lobes from the temporal. Named after Sylvius, the Latin name of Jacques DuBois, a French physician.
Flex'or car'pi ra-di-a'lis. A flexor of the carpal bones on the radial side of the arm.
Flex'or car'pi ul-na'ris. Flexor of the carpal bone on the ulnar side of the arm.
Flex'or lon'gus dig-i-to'rum. The long flexor of the toes.
Flex'or lon'gus hal-lu'cis. The long flexor of the great toe.
Flex'or lon'gus pol'li-cis. The long flexor of the thumb.
Flex'or pro-fun'dus dig-i-to'rum. The deep flexor of the fingers.
Flex'or sub-li'mus dig-i-to'rum. The superficial flexor of the fingers.
Fol'li-cle. A very small excretory or secretory sac or gland.
Fon-ta-nel'. An unossified space of the skull of an infant.
Fo-ra'men. A hole or opening.
Fo-ra'men of Ma-gen'die. Orifice in the pia, covering the roof of the fourth ventricle. Named after Francois Magendie, a French physician.
Fo-ra'men mag'num. An opening in the occipital bone of the skull through which the spinal cord passes.
Fo-ra'mi-na of Lusch'ka. Two orifices in the pia, covering the roof of the fourth ventricle.
For-mal'de-hyde. A gaseous compound H·CHO, formed by the partial combustion of methyl alcohol.
For'ma-lin. An aqueous solution of formaldehyde.
Fos'sa. A pit or depression.
Fos'sa o-va'lis. A depression in the wall between the two auricles of the heart.
Fo've-a cen-tra'lis. Pit in the middle of the macula lutea which is the most sensitive portion of the retina.
Fre'num. A connecting fold of membrane supporting or restraining a part, as the frenum of the tongue.
Fron'tal. Pertaining to the front.
Fun'dus. The bottom or base of a hollow organ.

Fun'gi-form. Shaped like a fungus or mushroom.
Fu-nic'u-lus. A bundle of fibres such as the bundle of which large nerves are composed.

G

Gall-blad'der. The pear-shaped reservoir for the bile on the under surface of the bladder.
Gal-va-nom'e-ter. Instrument for measuring galvanic electricity.
Gan'gli-on (pl. ganglia). A group of nerve cells massed together as a center to control different functions.
Gan'gli-on-ic. Pertaining to a ganglion.
Gärt'ner's duct. A small tubule of the female generative tract. Named after G. Gärtner, the German anatomist.
Gas'tric. Pertaining to the stomach.
Gas-troc-ne'mi-us. The large muscle of the calf of the leg.
Gas-tro-du-o-de-nal'is. An artery of the stomach and duodenum.
Gas-tro-ep-i-plo'i-ca si-nis'tra. An artery of the left end of the stomach.
Gas-tro-he-pat'ic. Pertaining to the stomach and liver.
Gen'i-to-u'rin-a-ry. Pertaining to the genital and urinary organs.
Ge'nu val'gum. Knock-knee.
Ge'nu va'rum. Bow-leg.
Ger'mi-nal. Pertaining to a germ cell or an early stage of an embryo.
Gla-bel'la. The smooth prominence of the forehead just between the eyebrows.
Gla-di'o-lus. The middle section of the sternum.
Gle'noid. A smooth and shallow cavity of the scapula.
Glob'ule. A small spherical particle of matter.
Glob'u-lin. A protein.
Glo-mer'u-lus. A small coiled mass of capillaries contained in Bowman's capsule of the kidney.
Glos-so-pha-ryn'ge-al. Pertaining to the tongue and pharynx.
Glot'tis. The opening of the pharynx into the larynx.
Glu-te'us max'i-mus. A large extensor muscle of the hip joint.
Glu-te'us me'di-us. An extensor muscle of the hip joint.
Glu-te'us min'i-mus. A small extensor muscle of the hip joint.
Glu-te'al. Pertaining to the buttocks.
Glyc'er-in. A sweet colorless, odorless liquid $C_3H_5(OH)_3$. This substance is hygroscopic, *i.e.*, takes up water.
Gly'co-gen. A substance derived from the digestion of starches and sugars.
Gly-co-gen'ic. Pertaining to glycogen.
Gly-co-su'ri-a. Abnormally high proportion of sugar in the urine.
Gon'ad. A reproductive organ.
Graaf'i-an fol'lic-le. Any one of the small spherical ovarian bodies, each of which contains an ovum.
Grac'i-lis. An adductor muscle on the mesial aspect of the thigh.
Gran'u-la-tion. Formation of grain-like prominences on the surface of a raw wound.
Gray matter. Nerve tissue of the brain and spinal cord which contains mainly nerve cells.
Guan'ase. A ferment found in the thymus, adrenals, and pancreas.

H

Hare-lip. A congenital deformity of the upper lip, often associated with cleft palate. It rarely involves the lower lip.
Has'sall's cor'pus-cle. Small bodies in the thymus. Named after A. S. Hassall, the English physician.

Haus'tra. Partial partitions in the colon giving a valve-like effect.
Ha-ver'sian. Pertains to the arrangement of bone in concentric form. Named after Clopton Havers, an English physician.
He-li-ot'ro-pism. Movement of cells under influence of light.
Hem'a-tin. An iron compound present in the hemoglobin of the blood.
He-mo-glo'bin. Iron-protein compound in red blood cells, giving coloring to blood.
He-mol'y-sis. Destruction of red blood cells by a foreign substance called a hemolysin.
He-mo-lyt'ic. Referring to hemolysis.
He'mo-lyze. The process of hemolysis.
He-mo-phil'i-a. Strong tendency to bleeding; usually hereditary.
He-mo-phil'i-ac. A person affected with hemophilia.
Hem'or-rhage. A discharge of blood. Commonly used to denote a severe condition.
He-pat'ic. Pertaining to the liver.
He-pat'ic flex'ure. The turn of the ascending colon to the left which takes place at the under surface of the liver.
Hep-a-to-du-o-de'nal. Pertaining to the liver and duodenum.
Hep-a-to-gas'tric. Pertaining to the liver and stomach.
He-red'i-ty. The biological transmission of the physical and psychical characters of parents to their offsprings.
Her'ni-a. A protrusion of a part or organ through the walls of its cavity.
Hi'lum. A depression at the entrance and exit of vessels, nerves, and ducts into a gland.
Ho-mo-ge'ne-ous. Of uniform quality. Opposed to heterogeneous.
Ho-mol'o-gous. Corresponding in structure.
Ho-mon'y-mous hem-i-an-op'si-a. Blindness in one-half of the field on the same sides of the two eyes.
Ho'mo sa'pi-ens. Intelligent man.
Hor'mone. An autacoid that stimulates activity of the cells.
Hu'me-rus. The bone between the shoulder and elbow.
Hu'mor-al. Refers to the theory based upon the idea of humors in the body.
Hy'a-line. Smooth, glassy-like cartilage.
Hy'a-loid. Like glass; a structure in the eye.
Hy-dro-ceph'a-lus. Fluid effusion within the ventricles of the brain.
Hy'dro-gen i'on con-cen-tra'tion. The varying amount of hydrogen-ions in the blood, described in terms of its concentration. The hydrogen-ion concentration is represented usually by P_H value of some number.
Hy-drol'y-sis. A chemical change in a substance in which water is taken up in the reaction.
Hy'men. A thin membrane completely or partially covering the vaginal orifice.
Hy-per-e'mi-a. Excess of blood in any part of the body.
Hy-per-es-the'si-a. Excessive sensitiveness of the skin.
Hy-per-func'tion. Function of a part beyond its normal range.
Hy-per-gly-ce'mi-a. Excess of sugar in the blood.
Hy-per-o'pi-a. Far-sightedness.
Hy-per-to'nic. 1. Pertaining to an excessive tonicity of a muscle. 2. Also pertaining to a solution with an osmotic pressure greater than the plasma.
Hy-per'tro-phy. Enlargement of an organ or part.
Hy-po-der-moc'ly-sis. Injection of a salt solution into subcutaneous tissue.
Hy-po-func'tion. Function of a part below the normal range.
Hy-po-gas'tric. 1. Pertaining to the lower middle abdominal region. 2. An artery of the fetal circulation.

Hy-po-glos'sal. 1. Situated under the tongue. 2. The name given to a muscle of the tongue and the twelfth cranial nerve.
Hy-poph'y-sis. The pituitary gland.
Hy-po-to'nic. Diminished tonicity or tension; refers to a muscle, or to the osmotic pressure of a fluid that is lower than the plasma.
Hy-po-xan'thin. A nitrogenous substance derived from the nuclei of cells.

I

Ic-ter'ic. Pertaining to jaundice.
Il-e-o-ce'cal. Pertaining to the ileum and cecum.
Il'e-um. The last division of the small intestine.
I-li'a-cus. A muscle of the pelvis and hip joint.
Il-i-o-fem'o-ral. Pertaining to the ilium and femur.
I-li-o-lum'bar. Pertaining to the iliac and lumbar regions.
Il-i-o-pec-tin'e-al. Pertaining to the ilium and the os pubis.
Il'i-um. One of the bones of the os innominatum.
Im-mu'ni-ty. A theory that explains the freedom from certain diseases.
Im-mun'ize. The process of rendering immune.
Im-plan-ta'tion. Process of transferring.
In-cis'ion. A cut or wound.
In-ci'sor. Any one of the four front teeth of either jaw.
In-con'ti-nence. Inability to restrain natural discharges.
In'cus. Anvil-shaped; the middle of the three small bones of the middle ear.
In-dox'yl. An oily substance, C_8H_7NO found in urine.
In'fan-tile. Pertaining to infants.
In-fer'i-or me-sen-ter'ic. An arterial division of the abdominal aorta.
In-fer'i-or ve'na ca'va. The large vein carrying blood from the lower extremities.
In-flam-ma'tion. An abnormal condition characterized by congestion of blood vessels and exudation of serum.
In-fra-gle'noid. A process below the glenoid cavity of the scapula.
In-fra-or'bit-al. Beneath the orbit; refers usually to an opening in the superior maxillary bone for the emergence of nerves and blood-vessels.
In-fra-spi-na'tus. A muscle of the scapula located below the spine.
In-fra-spi'nous. Below the spine of the scapula.
In-fun-dib'u-lum. 1. A funnel-shaped structure. 2. Several parts of the body are so described, as the terminal division of the lungs, the calyces of the kidney, and certain structures of the brain.
In'gui-nal canal. A canal about one and a half inches long above Poupart's ligament that transmits the spermatic cord in the male and the round ligament in the female.
In-her'i-ted. Congenital; opposed to acquired.
In-hib'i-to-ry. Pertaining to inhibition; i. e., an inhibitory nerve impulse suppresses the action of a part.
In-ner-va'tion. Distribution of the nerves to a part and also the excitation of nerves.
In-nom'i-nate. Without a name. Parts that resemble nothing in nature were often called innominate by the older anatomists.
In si'tu. In its natural or normal place.
In-spi-ra'tion. Inhalation.
In'su-lin. A chemical substance derived from the sheep's pancreas and used for the treatment of diabetes.
In-ter-au-ric'u-lar. Situated between the auricles.
In-ter-con'dy-lar. Between two condyles.
In-ter-met-a-tar'sal. Between the metatarsal bones.

In-ter'nal in-ter-cos'tals. Between the ribs.
In-ter-os'se-ous. Situated between bones.
In-ter-sti'ti-al. Pertaining to places between cells within tissues.
In-ter-tro-chan-ter'ic lines. Two ridges around the base of the neck of the femur.
In-ter-ven-tric'u-lar. Situated between the ventricles.
In-ter-ver'te-bral. Situated between the vertebrae.
In-tes'tine. Membranous tube extending from the stomach to the anus. The first, longer and narrower portion is the small; the other is the large intestine.
In-tra-ab-dom'i-nal. Within the abdomen.
In-tra-cra'ni-al. Within the skull.
In-tra-mem'bra-nous. Within membrane. Refers particularly to a variety of bone formation.
In u'ter-o. Within the womb or uterus.
In-vag-i-na'tion. The process of folding in a portion of the wall of a part.
In-vert'ase. Ferment obtainable from the intestine and from yeast.
I'ris. A muscle of the eye. This part forms the colored portion of the eye.
Is'chi-um. The lower portion of the os innominatum.
Is'lands of Lan'ger-hans. Small groups or islands of cells within the pancreas.
Is'land of Reil. The central lobe of the cerebrum, located within the Sylvian fissure. Named after J. C. Reil, a Dutch physician.
I-so-ton'ic. Having the same osmotic pressure as the plasma.

J

Je-ju'num. Second portion of small intestine, between the duodenum and the ileum.
Ju'gu-lar. Pertaining to the neck; referring especially to the jugular veins: great veins in the neck conveying most of the blood from the head.

K

Ka-tab'o-lism. Process of removal of waste material in the cells; the process of breaking down of chemical compounds.
Kid'ney. Either one of two glandular bodies in the lumbar region which secrete the urine.
Kil'o-gram. A measure of weight being 1000 grams equal to approximately 2.2 pounds.
Ky-pho'sis. Hunch-back.

L

La'bium, (pl. labia). A lip.
La'bi-a ma-jo'ra. The large folds on either side of the vaginal orifice.
La'bi-a mi-no'ra. The small folds on either side of the vaginal orifice.
Lab'y-rinth. The internal ear.
Lac'ri-mal. 1. Pertaining to tears. 2. Refers also to the organs that produce tears, i. e., lacrimal bone, duct, or gland.
Lac-ri-ma'tion. Process of crying.
Lac'tase. A pancreatic ferment splitting lactose into glucose and galactose.
Lac-ta'tion. The secretion of milk by the mammary glands.
Lac'te-al. Small lymphatic vessels of the small intestine which convey lymph to the thoracic duct.
Lac'tic acid. Chemical compound resulting from fermentation.
La-cu'na. A small hollow or depression.

Lamb-doid'al. 1. Shaped like the Greek letter Lambda. 2 Pertaining to the suture between the occipital and parietal bones of the skull.
La-ryn-go-phar'ynx. The lower portion of the pharynx.
Lar'ynx. 1. Air-passage between the pharynx and trachea. 2. Also the site of the vocal cords.
La-tis'si-mus dor'si. The broadest muscle of the back.
Leu'co-cyte. A colorless ameboid mass, i. e., white blood corpuscles.
Leu-co-cy-to'sis. An increase in the number of leucocytes.
Leu-co-pe'ni-a. A decrease in the number of leucocytes.
Le-va'tor a'ni. A muscle of the pelvic floor.
Le-va'tor sca'pu-lae. A muscle of the scapula.
Lie'ber-kühn's glands. Tubular intestinal glands. Named after the German anatomist, Lieberkühn.
Lig'a-ment. A tough band connecting bones or supporting viscera.
Lig-a-men'tum nu'chae. Tough band at the nape of the neck, extending from the occipit to the seventh cervical vertebra.
Lig-a-men'tum sub-fla'vum. Yellowish ligament between the laminae of vertebrae.
Li'ne-a al'ba. A median, tendinous line on the abdomen, marking the union of the tendons of the external obliques.
Li'ne-a as'per-a. A rough longitudinal line on the back of the femur.
Lin'gual. Pertaining to the tongue.
Li'pase. A fat ferment of the liver.
Lip-o-lyt'ic. Splitting up of fats, i. e., lipase is lipolytic.
Liv'er. A glandular organ which secretes bile.
Lob'u-la-tion. Formed into lobules, i. e., into small lobes.
Lob'ule. A small lobe.
Lo-co-mo'tor a-tax'i-a. 1. Degeneration of posterior columns of the spinal cord. 2. A disease of the nervous system, involving the spinal cord and characterized by disturbances of gait, loss of reflexes, and difficulty in motor coordination.
Lor-do'sis. An increase in the lumbar curve.
Lum'bar. The region of the lower back, corresponding to the lower five vertebrae of the spine.
Lum-bo-sac'ral. Pertaining to the lumbar and sacral regions.
Lu'men. A transverse section of the clear spaces within tubes, such as respiratory or digestive tracts.
Lu'nule, (pl. **lunula**). The whitish cresent on the (finger) nail.
Lymph. The fluid contained in the lymphatic vessels, composed mainly of blood plasma.
Lym-phan-gi'tis. Inflammation of a lymphatic vessel
Lym-phat'ic. Pertaining to lymph or a lymphatic vessel.
Lymph-node. A nodule of lymphoid tissue found in the course of lymphatic vessels.
Lym'pho-cyte. White blood corpuscle.
Lym-pho-cy-to'sis. Increase of lymphocytes over normal number.
Lym'phoid. Resembling a lymphatic gland or cell.

M

Mac'ro-cyte. A red blood-corpuscle of largest type; not found in normal blood.
Ma'cu-la lu'te-a. The area of clearest vision at the center of the retina.
Ma'lar. Pertaining to the cheek.
Ma-lig'nant. Virulent and tending to become worse.
Mal-le'o-lus. The rounded projection on each bone of the leg at the ankle.

Mal'le-us. 1. Mallet-shaped. 2. The first of the three bones of the middle ear.

Mal-pigh'i-an. Pertaining to a number of structures described by Marcello Malphigia, an Italian anatomist.

Mam'mal. An animal of the vertebrate class, including man, that nourishes it young with milk.

Mam'ma-ry. Pertaining to the mammae or breasts.

Man'di-ble. The lower jaw-bone.

Man-dib'u-lar. Pertaining to the mandible.

Ma-nu'bri-um. The uppermost piece of the sternum.

Mar-gin-a'tion. A distinct peculiarity marking a margin.

Mar'row. Fatty material in bone cavity containing blood and blood-cells.

Mas-sage'. System of stroking and kneeding the body.

Mas-se'ter. A muscle of the lower jaw, used in chewing.

Mas'toid. 1. Resembling a nipple or breast. 2. Refers to a process of the temple bone.

Mat-u-ra'tion. 1. Development; stage or process of becoming mature. 2. Used specifically to describe the maturing of the egg-cell.

Max-il'la (pl. **maxillae**). A jaw-bone, particularly the upper.

Meck'el's di-ver-tic'u-lum. A blind pouch occasionally present, connected with the lower part of the ileum. Named after J. F. Meckel, a German anatomist.

Me-di-as-ti'num. The space in the chest between the plural sacs of the lungs.

Me-di-o-tar'sal. Pertaining to the center of the tarsus.

Me-dul'la. The lowest part of the brain, containing numerous nerve centers.

Med'ul-lat-ed. Having a sheath of soft, white, fatty material.

Meg-a-ce-phal'ic. Having a large cranial capacity in excess of the mean.

Meg'a-lo-blast. A giant nucleated blood-corpuscle.

Mei-bo'mi-an. Pertaining to glands of the eyelids. Discovered by Henrick Meibom, a German physician.

Meiss'ner's cor'pus-cle. Small tactile mass in the skin of the palmar surfaces of the fingers and toes. Described by Professor George Meissner, Göttingen.

Mem-bra'na tec-to'ri-a. A membrane in the organ of Corti of the internal ear.

Mem'bra-nous. Pertaining to a thin layer of tissue which covers a surface or divides an organ.

Mem'bra-nous coch'le-a. The membrane of the cochlea of the inner ear.

Me-nin'ges, (sing. **meninx**). The three membranes of the brain and cord: the dura, pia, and arachnoid.

Men-in-gi'tis. Inflammation of the membranes of the brain and cord.

Me-nin'go-cele. Hernial protrusion of meninges.

Men'o-pause. Period when menstruation ceases.

Men-stru-a'tion. The periodic discharge of blood and bloody fluid from the uterus.

Mes-en-ter'ic. 1. Pertaining to the mesentery. 2. An artery of the abdominal aorta.

Mes'en-ter-y. Membranous fold attaching intestine to abdominal wall.

Mes-o-ap-pen'dix. The peritoneal fold which connects the appendix to the cecum.

Mes'o-derm. The middle layer of the primitive embryo.

Mes-o-neph'ric duct. Pertaining to the Wolffian body or mesonephros.

Mes-o-neph'ros. An early stage in the development of the excretory tract.

Mes-o-the'li-um. Part of the mesoderm in which serous cavities and muscles are developed.

Mes-o-va'ri-um. Peritoneal fold which holds the ovary in place.
Met-a-bol'ic. Pertaining to the processes of metabolism.
Me-tab'o-lism. Process of assimilation of energy materials (food) into the protoplasm of the cell and the removal of the waste resultant from cell activity.
Met-a-car'pus. That part of the hand between the wrist and the phalanges which is composed of five bones.
Met-a-mor'pho-sis. A passing from one form or shape into another.
Me-top'ic. Pertaining to the region of the forehead.
Mi'cro-blast. Same as microcyte.
Mi-cro-ce-phal'ic. Having a small head.
Mi-cro-ceph'a-lus. A condition of the head in which the cranial cavity is smaller than the median.
Mi'cro-cyte. An undersized red blood-corpuscle.
Mi'cron (pl. micra). One micron equals $\frac{1}{1000}$ millimeter.
Mi'cro-scope. Instrument which magnifies minute objects for visual inspection.
Mic-tu-ri'tion. The passage of urine from the bladder.
Mil'li-met-er. One-thousandth part of a meter.
Mi-to'sis. Indirect cell division.
Mi'tral. 1. Shaped somewhat like a miter. 2. Specifically, a valve between the left ventricle and the left auricle.
Mne-mon'ics. Cultivation of the memory.
Mo'lar. A tooth with broad crown and large roots.
Mol-lus'ca. A class of invertebrate animals, including cuttlefish, snails, and bivalves.
Mon-o-nu'cle-ar. Having but one nucleus.
Mon-o-sac'cha-rid. A simple sugar not decomposable into simpler units by hydrolysis.
Mons Ve'ner-is. A rounded prominence in front of the pubes of a woman.
Mül-le'ri-an duct. Ducts that give rise to the fallopian tubes. Named after Johannes Müller, a German anatomist.
Mul-ti-cel-lu-lar'i-ty. Consisting of many cells.
Mur'mur. An abnormal sound of the heart or lungs.
Mus'cle sense. The sense which functions in connection with muscular action, giving information regarding the position of the body or parts.
Mus-cu-lo-mem'bra-nous. Pertaining to muscle and membrane.
Mus-cu-lo-spi'ral. A groove on the posterior aspect of the humerus, containing a nerve of the same name.
My'e-lin. A soft, white, fatty material forming the substance of the medullary sheath of nerve-fibres.
My'e-lo-cyte. A marrow-cell.
My'e-lo-plax. A multinuclear giant-cell of bone-marrow.
My-o-car'di-um. The muscular substance of the heart.
My-o'pi-a. Near-sightedness.
My'o-tome. The mesial portion of the somite that develops from the mesoderm.
Myx-e-de'ma. A disease due to failure of the thyroid gland and characterized by dullness of intellect, slow speech, and coarse skin and hair.

N

Na'res. The nostrils or nasal openings.
Nat'u-ral se-lec'tion. Survival of the fittest.
Ner'vous cor-re-la'tion. Coordination of bodily functions through nerve-impulses.
Neu'ral. Pertaining to nerves.

Neu-ri-lem'ma. The sheath of a nerve-fibre.
Neu-rog'li-a. The framework and connective tissue of the spinal cord and brain.
Neu'ron. A nerve-cell with all its processes
Neu'tral-ize. The process of rendering neutral or without distinctive characteristic.
Neu'tro-phil. A structure whose granules take both acid and basic stains.
Nip'ple. The small protuberance of the breast.
Nis'sl body. Darkly staining mass within the cytoplasm.
Ni'tro-gen e-qui-lib'ri-um. A condition in which the excretion of nitrogen exactly equals the intake of nitrogen.
Nodes of Ran'vi-er. Nodes produced by constriction on medullated nerve-fibres at an interval of about one millimeter. Named after Louis Ranvier, French histologist.
Node of Ta-wa'ra. A small mass of nerve cells located at the opening of the superior vena cava.
Norm. A rule or authoritative standard.
Nor'mo-blast. A nucleated red blood-corpuscle of ordinary size.
Nu'cle-us. A small body within the protoplasm of cells; the vital part of the cell. Also a group of nerve-cells in the brain, as the nucleus of Goll, Red nucleus, etc.
Nu'cle-us cu-ne-a'tus. A group of nerve-cells in the medulla.
Nu'cle-us gra'ci-lis. A group of nerve-cells in the medulla.
Nu-cle'o-lus. A rounded body within the nucleus.
Nu'tri-ent. Furnishing or conveying nourishment.

O

O-bes'i-ty. Fatness.
Ob'tu-ra-tor fo-ra'men. An opening in the pelvis between the os pubis and ischium.
Oc-cip'i-tal. Pertaining to the back of the head.
Oc-cip-i-to-fron-ta'lis. A muscle extending from the occiput to the brow.
Oc-cip-i-to-men'tal. A diameter of the skull, extending from the middle of the jaw to the occiput.
Oc-u-lo-mo'tor. Pertaining to eye movements, especially describing the third cranial nerve.
O-don'to-blast. One of the connective tissue cells by which dentin is developed.
O-don'toid. 1. Meaning like a tooth. 2. A small process on the body of the second vertebra.
O-le-cra'non. Curved process of the ulna at the elbow.
Ol-fac'to-ry. Pertaining to the sense of smell.
O-men'tum. A fold of the peritoneum forming an apron over the intestines.
Op-son'ic index. The ratio between the number of bacteria destroyed through the action of leucocytes in normal blood serum and the number destroyed in that serum to which opsonin has been added.
Op'so-nin. Antibodies conditioning the power of the leucocyte to attack bacteria.
Op'tic fo-ra'men. An opening in the skull for the passage of the optic nerve.
O'ral. Pertaining to the mouth.
Or-bi-cu-la'ris o'ris. A muscle surrounding the mouth.
Or-bi-cu-la'ris pal-pe-bra'rum. The muscle surrounding the eye.
Or'bit. Bony socket that contains the eye.
Or'bit-al. Pertaining to the orbit.

Organ of Cor'ti. A complex membranous structure in the cochlea, the organ of hearing. Named after Corti, an Italian anatomist.
O-ro-phar'ynx. Part of the pharynx below the nasopharynx.
Os cal'cis. Heel bone.
Os in-nom-i-na'tum. The bone without a name, forming half of the pelvis. See "innominate."
Os mag'num. The third bone in the second row of the carpus.
Os-mo'sis. The passage of a fluid through a membrane.
Os-mot'ic. Pertaining to osmosis.
Os pu'bis. The anterior part of the os innominatum.
Os-si-fi-ca'tion. Formation of bone.
Os'te-o-blast. A bone-forming cell.
Os'te-o-clast. A bone-destroying cell.
O-va'ri-an. Pertaining to an ovary.
O'va-ry. The female sexual gland in which the ova are formed.
O-vip'a-rous. Laying or producing eggs.
O-vu-la'tion. The formation of eggs in the ovary; also the discharge of eggs.
O'vum. Egg; female reproductive cell.
Ox'y-gen-ate. To impregnate or combine with oxygen; to oxidize.
Ox-y-he-mo-glo'bin. Combination of oxygen with the hemoglobin of the red cells.

P

Pa-cin'i-an cor'pus-cle. Receptors in the skin of the hands, feet, and other parts of the body. Named after Filippo Pacini, Italian physician.
Pal'a-tine. Pertaining to the palate.
Pal'mar. Pertaining to the palm.
Pal-ma'ris lon'gus. A muscle of the forearm, ending in the fascia of the palm.
Pal-pa'tion. The act of feeling with the hand.
Pan'cre-as. A large, elongated gland below the stomach and in relation with the spleen and the duodenum.
Pa-pil'la. 1. A vascular process of connective tissue extending into and nourishing a root of a hair or developing tooth. 2. One of the many projections of the dermis into the epidermis.
Pa-pil'la of Va'ter. The common opening of the bile duct and the pancreatic duct. Named after A. Vater, a German anatomist.
Pap'il-la-ry. Pertaining to a papilla; the nipple-shaped muscular projections on the inner surface of the ventricle of the heart.
Pa-ral'y-sis. Loss of power of voluntary motion.
Par-a-me'ci-um. A well-known protozoan characterized by the presence of cilia.
Par'a-site. A plant or animal living upon a living organism.
Pa-ra-si'tic. Like a parasite.
Pa-ra-sym-pa-thet'ic. The middle portion of the autonomic nervous system.
Par'e-sis. General paralysis.
Pa-ri'e-tal. 1. Pertaining to the walls of a cavity. 2. The name of two bones of the skull.
Pa-ri-e-to-oc-cip'i-tal. Pertaining to the parietal and occipital bones.
Pa-rot'id. A gland on either side of the head situated near the ear.
Par-o-ti'tis. Inflammation of the parotid gland.
Pa-tel'la. The knee-cap.
Pa-tel'lar. Pertaining to the patella.
Pec-to-ra'lis ma'jor. A large muscle of the chest.
Pec-to-ra'lis mi'nor. A small muscle of the chest.

Ped'i-cle. The process which connects the lamina of a vertebra with the centrum.
Pe-dic-u-lo'sis. Lousiness.
Pe-dun'cle. A stem or supporting part.
Pel'vis. A basin; specifically the bony pelvis and the pelvis of the kidney.
Pen'dant. Something which hangs.
Pe'nis. Male organ of copulation.
Pep'sin. A ferment of the gastric juice.
Pep'tone. A protein formed by the action of pepsin.
Per-fo-ra'tion. The act of making an aperture or hole.
Per-i-car'di-al. Relating to the membranous bag which contains the heart.
Per-i-car-di'tis. Inflammation of the pericardium.
Per-i-car'di-um. Membranous bag containing the heart.
Per-i-chon'dri-um. The membrane which covers the surface of a cartilage.
Per'i-lymph. The lymph of the inner ear outside of the organ of Corti.
Per-i-ne'um. Space between the vaginal orifice and anus.
Per-i-neu'ri-um. The sheath or funiculus of nerve-fibres.
Per-i-os'te-um. Covering membrane of bone.
Per-i-stal'sis. A rhythmical contraction of a hollow organ.
Per-i-stal'tic. Pertaining to peristalsis.
Per-i-to-ne'al. Pertaining to the peritoneum.
Per-i-to-ne'al fluid. Serous fluid of the abdominal and pelvic cavities.
Per-i-to-ne'um. Serous membrane lining the walls of the abdominal and pelvic cavities.
Per-o-ne'al. 1. Near the fibula; specifically, muscles on the lateral aspect of the leg. 2. Nerves and arteries of the same region.
Per-o-ne'us bre'vis. A muscle on the lateral aspect of the leg.
Pey'er's Patch. Large groups of lymphoid cells in the wall of the small intestine, especially in the ileum. Named after Johann Peyer, a Swiss anatomist.
Phag'o-cyte. Any leucocyte that ingests and destroys waste and harmful material, i.e., bacteria.
Phag-o-cy-to'sis. Destruction of bacteria.
Pha-lan'ges (sing. phalanx). Bones of the fingers and toes.
Pha-ryn'ge-al ton'sil. A mass of lymphoid tissue at the back of the pharynx, more commonly known as adenoids.
Phe'nol. Carbolic acid or any of its homologues.
Pho-to-tax'is. Movement of cells under influence of light.
Phren'ic. Pertaining to the diaphragm.
Phre-nol'o-gy. Study of the faculties and qualities of mind from the shape of the skull.
Phy-lo-ge-net'ic. Pertaining to the development of a species, signifying racial rather than individual characteristics.
Phys-i-o-chem'i-cal. Denoting physical and chemical qualities.
Phys-i-o-ther'a-pist. One who treats others by the use of physical appliances, massage, etc.
Pi'a ma'ter. The innermost membrane of the brain and spinal cord.
Pillars of the fau'ces. Two musculo-membranous bands on either side of the opening from the mouth into the pharynx between which rest the tonsils.
Pi'ne-al. A small, reddish cone-shaped gland on the under surface of the brain, and connected with the third ventricle.
Pin'na. The auricle of the ear.
Pi-pet'. A tube for small quantities of liquid.
Pis'i-form. Small bone in ulnar side of wrist in proximal row.
Pi-tu'i-ta-ry. A small, reddish organ in a depression of the sphenoid bone and attached to the brain by a pedicle.

Pi-tu'i-trin. The secretion of the pituitary gland.
Pla-cen'ta. The organ within the uterus which establishes a communication between mother and child.
Plan'tar. Pertaining to the sole of the foot.
Plas'ma. The fluid portion of the blood.
Pleu'ra. Serous membrane covering the lungs and lining the chest cavity.
Pleu'ral. Pertaining to the pleura.
Pleu'ri-sy. Inflammation of the pleura.
Plex'us. A network of veins or nerves.
Plex'us of Auer'bach. A collection of autonomic nerve cells and fibres between the longitudinal and circular muscular layers of the intestines. Named after Leopold Auerbach, a German physician.
Plex'us of Meiss'ner. A plexus of autonomic nerve-fibers lying between the muscular and mucous coats of the intestine. Named after Professor Georg Meissner of Göttingen.
Pneu-mo-gas'tric. The tenth cranial nerve. Also called the vagus.
Pneu-mo-tho'rax. Gas or air in the pleural cavity.
Poi'ki-lo-cyte. A malformed blood-corpuscle.
Pol-y-chro-ma-to-phil'ic. Referring to the ability of cells to take stains of several kinds.
Pol-y-mor-pho-nu'cle-ar. Having nuclei of many forms.
Pons Va-ro'li-i. A portion of the brain in front of the medulla and connected with the cerebellum and cerebrum.
Pop-li-te'al. Pertaining to the back part of the leg behind the knee-joint. Refers to numerous structures in this region.
Por'tal. 1. A gate or opening. 2. Refers to numerous structures such as portal veins, etc.
Pos-ter'i-or com'mis-sure. A band of fibres crossing from one side of the spinal cord to the other, in the back.
Pos-ter-o-lat'er-al. Situated back and at the side.
Pos-ter-o-me'di-an. Situated back and toward the middle.
Pou-part's (poo-parz') lig'a-ment. The thickened lower border of the aponeurosis of the external oblique muscle, extending from the anterior superior spine of the ilium to the spine of the os pubis. Named after F. Poupart, a French anatomist.
Pre-hen'sile. Adapted for seizing or grasping.
Pre-pa-tel'lar. In front of the patella.
Pre'puce. The fore skin of the penis.
Pres-by-o'-pi-a. Diminished elasticity of the lens due to advance in age.
Proc'ess. A projecting point.
Prog'na-thism. Projection of the jaw.
Pro'lapse. Falling down of an internal part of the body.
Pro-na'tor quad-ra'tus. A muscle of the forearm.
Pro-na'tor ra'dii te'res. A muscle of the upper part of the forearm.
Pro-neph'ros. An early stage of the excretory system.
Pro-nu'cle-us. Nucleus of the egg-element (female pronucleus) or of the sperm-element (male pronucleus) after the coalition of the spermatozoön with the ovum.
Pros'tate. A gland surrounding the neck of the bladder and urethra in the male.
Pro'tein. A complex chemical containing nitrogen; one of the three principal substances of foods.
Pro'to-plasm. The essential substance of cells.
Pro-tu'ber-ance. A projecting eminence.
Prox'i-mal. Nearest the trunk, center, or median line.
Pso'as mag'nus. 1. A muscle extending from the lumbar spine across the pelvis to the femur. 2. The tenderloin of animals.

Psy'chic. Pertaining to the mind.
Pty'a-lin. A ferment found in saliva.
Pu'ber-ty. The age at which the generative power becomes established.
Pu-den'dal. Pertaining to the external genitalia.
Pul'mo-na-ry ar'te-ry. The large vessel extending from the right ventricle to the lungs and carrying venous blood.
Pul'mo-na-ry sem-i-lu'nar valves. Half-moon shaped valves between the right ventricle and pulmonary artery.
Pul'mo-na-ry veins. Blood-vessels extending from the lungs to the left auricle and carrying arterial blood.
Pulse. The beat of the heart transmitted throughout the arterial system and felt at numerous places where the arteries are near the surface.
Pu'rin bases. Complex chemical compounds derived from nuclei of cells.
Pur'kin-je's cells. Large branched cells of the cerebellar cortex. Named after J. E. Purkinje, Bohemian physiologist.
Pus. A liquid inflammation-product made up of cells, dead bacteria, and a thin fluid.
Py-lo'rus. The opening from the stomach into the intestines.
Py-or-rhe'a al-ve-o-la'ris. A condition of the teeth marked by retraction of gums, accumulation of pus, and finally looseness of the teeth.
Py-ram'i-dal. Shaped like a pyramid.
Py-rex'i-a. Elevation of temperature.
Py-ri-for'mis. A muscle on the posterior part of the hip joint.

Q

Quad-ra'tus lum-bo'rum. A muscle on the lateral aspect of the trunk.
Quad'ri-ceps ex-ten'sor fem'o-ris. The four-headed muscle on the anterior aspect of the thigh.
Quad'ru-ped. A four-footed animal.

R

Ra-chit'ic. Pertaining to rickets.
Ra'di-o-graph. A picture made by the Röentgen-rays.
Ra'di-us. The lateral bone of the forearm.
Ra'mus. A branch or limb. Refers to parts of a bone or other processes.
Re-ac'tion. The response made by a part to a stimulus.
Re-cep'tors. The specialized ends of afferent neurons.
Re-ces'sive. The weaker of mutually antagonistic parental characters.
Re-cip'ro-cal in-ner-va'tion. A phenomenon in which antagonistic muscle groups are inhibited at the same time they are stimulated.
Rec'tum. The distal portion of the large intestine.
Rec'tus ab-dom'i-nis. The muscle of the anterior part of the abdominal wall.
Rec'tus fem'o-ris. One of the four muscles of the quadriceps extensor femur.
Re'flex. An involuntary movement in consequence of an impulse or impression transmitted along nerves.
Re-gur-gi-ta'tion. A flowing backward of contents through a tube or cavity of the body.
Re-sis'tance. The ability to repel invading micro-organisms.
Re-spir'a-to-ry. Pertaining to the act of breathing.
Re-tic'u-lar. Resembling a network.
Ret'i-na. The perceptive structure of the eye.
Re-tro-per-i-to-ne'al. Situated behind the peritoneum.
Re-tro-pha-ryn'ge-al. Occurring behind the pharynx.

Re-tro-ver'sion. A turning or bending backwards.
Rhom'boid. A muscle of the upper back.
Rick'ets. Childhood disease in which bones become crooked and deformed through absence of vitamin D.
Round lig'a-ment. A fibrous cord extending from the ovary through the inguinal canal to the superficial fascia of the groin.
Ru-bro-spi'nal. A nerve track in the spinal cord.
Ru'ga. A ridge or fold.

S

Sac. A bag-like membranous organ.
Sac'cu-lus. A small sac.
Sa'cral. Pertaining to the sacrum, that part of the spine which is composed of five vertebrae.
Sa-cro-coc-cyg'e-al. Pertaining to the sacrum and coccyx.
Sa-cro-il'i-ac. Pertaining to the sacrum and ilium.
Sa-cro-sci-at'ic. Pertaining to the sacrum and ischium.
Sa'crum. The lower part of the vertebral column fused into one bone that forms the posterior part of the pelvis. So named because this part of the cow was at one time considered sacred by the ancients.
Sag'i-tal. 1. Pertaining to an arrow, sagitta. 2. Refers to the suture between the parietal bones of the skull and hence designates the median line of the body.
San-to-ri'ni's duct. An accessory pancreatic duct. Named after G. D. Santorini, an Italian anatomist.
Sa-pon-i-fi-ca'tion. 1. The process of making soap. 2. Chemically, the decomposition of a fat by an alkali with the formation of soap.
Sar-co-lac'tic acid. See "Lactic acid."
Sar-co-lem'ma. A tough and fibrous sheath which encloses striated muscle-fibre.
Sar-to'ri-us. A muscle on the anterior aspect of the thigh.
Sca'la tym'pa-ni. One of the three spiral canals of the cochlea below the scala vestibuli.
Sca'la ves-tib'u-li. One of the three spiral canals of the cochlea above the scala tympani.
Sca'phoid. 1. Shaped like a boat. 2. Bone of the carpus and of the tarsus.
Scle'ra. The outer coat of the eyeball.
Scle'ro-tome. The lateral portion of the somite giving rise to bones and cartilage.
Sco-li-o'sis. Lateral curvature of the spine.
Sco-li-ot'ic. Pertaining to scoliosis.
Scro'tum. The pouch that contains the testicles.
Se-ba'ceous. Pertaining to a greasy secretion that lubricates the skin.
Se'bum. A greasy secretion from the sebaceous glands which lubricates the skin.
Se-cre'ta-gogue. Stimulating secretion.
Se-cre'tin. An enzyme in the mucous membrane of the intestine that stimulates the pancreas to secrete.
Sel'la Tur'ci-ca. A hollow in the upper surface of the sphenoid bone holding the pituitary gland. Named for its resemblance to a Turk's saddle.
Se'men. Liquid secreted by the testes and discharged in copulation.
Sem-i-lu'nar. 1. Of a half-moon shape. 2. The name of a bone of the wrist; also used with other structures.
Sem'in-al ves'i-cle. Either one of the two reservoirs for semen.

Sem-i-nif'er-ous tu'bules. Tubes in the testes lined with epithelial cells which produce spermatozoa.
Sem-i-ten-di-no'sus. A muscle on the posterior aspect of the thigh.
Se'rous. Like serum.
Ser-ra'tus mag'nus. A muscle on the lateral and posterior part of the chest.
Se'rum (pl. sera). The watery portion of the blood remaining after coagulation.
Shock. A sudden depression of the vitality of the entire body following some profound influence on the nervous system.
Sig'moid. The S-shaped part of the colon.
Si'nus. 1. A groove or cavity, as used to designate a structure on the inner surface of the skull. 2. Also refers to a cavity between the two tables of a bone.
Si'nu-ses of Val-sal'va. Pouches behind the flaps of the semilunar valves of the heart. Named after A. M. Valsalva, Italian anatomist.
Skat'ol. A compound C_9H_9N formed by putrefaction of albuminous matter found in the human intestine.
Ska-tox'yl. The oxidation product of skatol.
So'lar plex'us. Great network of autonomic nerve-fibres on the dorsal aspect of the stomach.
So'le-us. A muscle of the calf.
So-mat'ic. Pertaining to the body.
So-mat'o-pleure. Body mesoderm.
So'mite. One of the segments composing the embryonic mesoderm.
Sper-mat'ic. 1. Pertaining to semen. 2. Spermatic artery: A branch of the abdominal aorta in the spermatic cord.
Sper-mat'ic cord. A connective tissue structure containing the vas deferens.
Sper'ma-tid. One of the cells which arises by division of the secondary spermatocytes and becomes spermatozoa.
Sper'ma-to-cyte. A cell giving rise to spermatozoa.
Sper-ma-to-go'ni-um. One of the primitive mole cells.
Sper-ma-to-zo'ön. The male generative cell, consisting of a head or nucleus and a flagellum or tail.
Sphe'noid. Wedge-shaped bone of the skull.
Sphyg-mo-ma-nom'e-ter. Instrument for measuring blood-pressure in the arteries.
Spi'na bi'fi-da. Cleft of vertebral column with protrusion of the cord through the opening.
Spine. The vertebral column.
Spi-no-tha-la'mic. A tract in the spinal cord leading to the thalamus.
Splanch'nic. Pertaining to the viscera.
Splanch'no-pleure. The thin, inner layer of the mesoderm.
Spleen. An organ in the left hypo-chondriac region, close to the cardiac end of the stomach.
Splen'ic. Pertaining to the spleen.
Splen'ic flex'ure. The turn of the transverse colon downward into the descending colon in the area of the spleen.
Squa'mous. Pertaining to flat, scale-like structures.
Sta'pes. Stirrup-shaped; the third of the three bones of the middle-ear.
Steap'sin. An enzyme of the pancreatic juice acting upon fatty acids and glycerine.
Ste-no'sis. Narrowing or contraction of a duct or canal.
Ster-no-cla-vic'u-lar. Pertaining to the sternum and clavicle.
Ster-no-clei-do-mas'toid. A muscle of the neck extending from the mastoid process of the temporal bone to the sternum.

Ster'num. Breast bone.
Steth'o-scope. An instrument used to convey to the ear sounds produced in the body.
Stig'ma (pl. **stigmata**). A small spot, mark or scar, usually indicating defect.
Stom'ach. The ovoid musculo-membranous digestive pouch below the esophagus.
Sty'loid. Shaped like a pen or stylus.
Sub-a-rach'noid. Beneath the arachnoid.
Sub-cla'vi-an. 1. Situated under the clavicle. 2. Refers to a particular muscle or blood-vessel.
Sub-lin'gual. 1. Situated beneath the tongue. 2. Common reference is to a salivary gland.
Sub-max'il-la-ry. 1. Situated beneath the lower jaw. 2. Common reference is to a salivary gland.
Sub-scap'u-lar. Beneath the scapula.
Sub-scap-u-la'ris. A muscle on the under surface of the scapula.
Sul'cus. A furrow or fissure, chiefly of the brain.
Sup-er-cil'i-a-ry. Pertaining to the region of the eyebrow.
Su-per'i-or me-sen-ter'ic. A branch of the abdominal aorta.
Su-per-nu'mer-a-ry. In excess of the regular number.
Su'pi-na-tor lon'gus. A muscle of the forearm.
Su'pi-na-tor ra'dii bre'vis. The short supinator of the hand on the radial side.
Sup-pu-ra'tion. Formation or discharge of pus.
Su-pra-or'bit-al. Above the orbit of the eye.
Su-pra-re'nal. 1. Above a kidney. 2. Refers to a particular gland also called the "adrenal" and to vessels and nerves.
Su-pra-spi-na'tus. A muscle of the scapula.
Su-pra-spi'nous. Above the spine.
Su-pra-spi'nous lig'a-ment. The ligament which connects the tip of the spinous processes of the vertebrae and serving as an interspinous ligament.
Sus-ten-tac'u-lum ta'li. A process of the calcaneum which supports the astragalus.
Su'ture. The union of the articulations of the skull.
Sym'phy-sis. Line of junction and fusion of bones originally distinct.
Syn'apse. The area of contact between the terminal arborizations of one neuron and the dendrites of another.
Syn-ar-thro'sis. An immovable joint.
Syn-o'vi-al. 1. Pertaining to viscid fluid of joint cavities. 2. Synovial membrane: lining of joints, bursae, and tendon-sheaths.
Sys'to-le. Contraction of the heart.

T

Tac'tile. Pertaining to the touch.
Tal'i-pes e-qui'nus. A condition of the feet in which the heel is drawn up so the individual walks on his toes.
Tal'i-pes val'gus. An abducted foot with the outer border elevated.
Tal'i-pes va'rus. Condition of the foot in which the heel is elevated, the inner edge of sole drawn upward, the sole shortened and the axis of the sole turned inward.
Tar'sus. The instep with its seven bones.
Tem'po-ral. 1. Pertaining to the temple. 2. Refers to a bone of the skull, a region of the brain, to muscles, arteries, and nerves.

Ten'do a-chil'lis. The tendon of the soleus and gastrocnemius muscles at the back of the heel. Named because of the story concerning the Greek character, Achilles.
Ten'don. The fibrous cord by which a muscle is attached to a bone.
Te'ni-a. A band of longitudinal muscles extending the length of the large intestine.
Ten'sor fas'ci-a la'ta. A muscle that tenses the broad fascia of the thigh.
Ten-to'ri-um ce-re-bel'li. An arch-like fold of dura mater covering the upper surface of the cerebellum.
Te'res ma'jor. A large muscle of the scapula attaching to the arm.
Te'res mi'nor. A small muscle of the scapula attaching to the arm.
Ter'mi-nal ar-bor-i-za'tion. Branching end of a neuron.
Tes'tes. Glands which produce the male sex cells, discharged as semen.
Tet'a-ny. A disease with intermittent spasms affecting usually the muscles of the extremities.
Thal'a-mus. A portion of the brain; also called optic thalamus.
Ther-a-peu'tic. Pertaining to the healing art.
Tho-rac'ic. Pertaining to the thorax or chest.
Tho-rac'ic duct. A lymphatic vessel carrying lymph from the lower extremities.
Tho-rac-i-co-lum'bar. Pertaining to thoracic and lumbar regions.
Throm'bin. The ferment which changes fibrinogen to fibrin.
Throm'bo-cyte. A blood-platelet.
Throm-bo'gen. The inactive form of thrombin.
Throm-bo-ki'nase. The activating agent whose power starts the process of clot formation.
Throm'bus. A clot in a blood-vessel found at the point of its formation.
Thy'mus. A two-lobed gland of internal secretion located above the heart; disappears at puberty.
Thy'roid. A large reddish, ductless gland in front of and on either side of the trachea and usually consisting of two lateral lobes and a connecting isthmus.
Thy-rox'in. The active principle of the thyroid secretion.
Tib'i-a. The larger bone of the leg.
Tib'i-al. Pertaining to the tibia.
Ton'ic. Having tonus.
To'nus. A partial state of contraction of the muscles by a process of nerve stimuli.
Tor-ti-col'lis. A contracted state of cervical muscles with torsion of the neck.
Tour'ni-quet. A device for the compression of blood-vessels.
Tox'in. A poisonous base of bacterial origin.
Tra'che-a. A cartilaginous and membranous tube; the windpipe.
Tra-che-ot'o-my. The formation of an artificial opening into the trachea.
Trans-fu'sion. Transfer of blood from one person to another.
Trans-ver-sa'lis. A muscle of the abdominal wall.
Tra-pe'zi-um. The first carpal bone in the distal row.
Tra-pe'zi-us. A large muscle of trapezoid shape situated in the upper back.
Trap'e-zoid. The second carpal bone in the distal row.
Tri'ceps. A three-headed muscle of the back and the upper arm.
Tri-cus'pid. Having three points or cusps. Refers usually to the valves between the auricle and ventricle of the right side.
Tri-gem'i-nal. The fifth cranial nerve.
Tro-chan'ter. A very large process.
Troch'le-a. A pulley-shaped part or structure.
Troch'le-ar. Pertaining to the fourth cranial nerve or the superior oblique muscle of the eye.

Tryp'sin. The protein ferment of pancreatic juice.
Tu'ber-cle. A small rounded projection.
Tu-ber-os'i-ty. A large rounded projection.
Tur'bi-nate. Spiral-shaped; refers usually to small bones in the nasal passageway.
Tym-pan'ic. Pertaining to the middle ear, or ear-drum.

U

Ul-cer-a'tion. Formation of an ulcer.
Ul'na. The inner and larger bone of the forearm.
Ul'nar. Pertaining to the ulna.
Um-bil'i-cal. Pertaining to the umbilicus.
Um-bi-li'cus. The navel.
Un'ci-form. 1. Shaped like a hook. 2. Bone at the ulnar edge of the carpus in the distal row.
U're-a. A white crystalline substance CON_2H_4 found in urine
U-re'ter. One of the tubes through which the urine goes from the kidney to the bladder.
U-re'thra. The passage through which urine is discharged from the bladder, and semen from the seminal vesicles.
U-re'thral. Pertaining to the urethra.
U'ric acid. A white odorless compound $C_5H_4O_3N_4$ present in small quantities in the urine.
U-ri-nif'er-ous. Pertaining to the tubules in the cortical portion of the kidneys.
U-ro-gen'i-tal. Pertaining to the urinary apparatus and to the genitalia.
U'te-rine. Pertaining to the uterus.
U-ter-o-sa'cral. Pertaining to the uterus and sacrum.
U-ter-o-ves'i-cal. Pertaining to the uterus and bladder.
U'ter-us. The womb.
U-tric'u-lus. The membranous labyrinth of the ear into which open the semicircular canals.
U'vu-la. The musculo-membranous tip of the soft palate.

V

Va-gi'na. The canal in the female from the cervix to the external orifice.
Vag'in-al. Pertaining to the vagina.
Val'vu-lae con-ni-ven'tes. Transverse mucous folds in small intestine.
Va'sa va-so'rum. Arteries and veins in the walls of larger blood-vessels.
Vas'cu-lar ne'vus. Birth mark.
Vas de'fer-ens. Excretory duct of the testicle passing from the testes to the ejaculatory duct.
Vas-o-con-stric'tor. Causing constriction of blood-vessels.
Vas-o-di-la'tor. Causing dilation of blood-vessels.
Vas-o-mo'tor. Controlling the size of blood-vessels by constriction and dilation.
Vas'tus cru-re'us. One of the four muscles of the quadriceps extensor femoris situated beneath the rectus femoris.
Vas'tus in-ter'nus. One of the four muscles of the quadriceps extensor femoris on the mesial aspect of the thigh.
Vein. A vessel which conveys blood to or toward the heart.
Ve'nae the-be'si-i. Small veins which return the blood from the muscle of the heart to the right auricle.
Ven'tri-cle. 1. Any cavity. 2. Refers usually to the heart or brain.
Ven'ule. A very small vein.

Ver'mi-form ap-pen'dix. A worm-shaped appendage attached to the cecum.
Ver'mis. Worm-like; the median lobe of the cerebellum.
Ver'te-bral. Pertaining to the vertebrae.
Ver'te-brate. Having a backbone or spinal column; having vertebrae or axial ossicles.
Ves-i-co-u'ter-ine. Pertaining to the bladder and uterus.
Ves-tib-u-lo-spi'nal. A tract in the spinal cord near the anterior root, connecting with the nucleus of the eighth nerve.
Vil'lus (pl. villi). A small slender vascular process, finger-like in character in the mucous membrane of the intestine.
Vis'cer-al. Pertaining to any large interior organ in any of the four great bodily cavities, especially those in the abdomen.
Vi'ta-min. A substance existing in foods which is necessary to proper metabolism and development.
Vit'el-line. Pertaining to the yolk of the germ-cell.
Vit're-ous. Glassy or hyaline.
Vit're-ous hum'or. Transparent, semi-fluid mass between the lens and the retina.
Vi-vip'a-rous. Producing living young from the living body. Opposed to oviparous which produces from eggs outside the body.
Void. To empty.
Vul'va. The external female genitalia.
Vul-vo-vag'i-nal. Pertaining to the vulva and vagina.

W

Wir'sung's duct. The duct of the pancreas. Named after J. G. Wirsung, German anatomist.
Wor'mi-an bones. Small bony islands existing in the course of a suture. Named after Olaus Wormius, a Danish anatomist.

X

Xan'thin. A white nitrogenous compound present in muscle tissue, liver, spleen, pancreas, and other organs. One of the purins.

Z

Zo-öl'o-gy. The science of animal life. Coordinate with botany as a division of biology.
Zy-go'ma. A process of bone extending between the temporal and malar bones.
Zy-go-ma'tic. Pertaining to zygoma.

INDEX

Abdomen, 393
Abdominal aorta, 329, 336
  parietal branches, 336
  terminal divisions, 340
  visceral branches, 336
cavity, 392
disease, pain impulses in trunk in, 232
reflex, 248
viscera, pain points of, 280
wall, muscles of, 179
Abducens nerve, 273
  brain connection of, 259
Abduction of joint, 110
Abscess, retropharyngeal, from coryza, 367
Absorption of carbohydrates, 437
of fats, 436
of proteins, 438
phenomena of, 434
Accelerator nerves, 317
Accessory thyroids, 477
Accomodation, 516
Acetabulum, 148
Aceto-acetic acid, 437
Achilles' reflex, 248
Acid or acids:
aceto-acetic, 437
β-oxybutyric, 437
fatty, 433
hydrochloric, 411
  action of, 413
lactic, in muscle, 174
reaction of muscle, 174
sarcolactic, 77
Acidosis, 437
Acini of pancreas, 431
Acinus, 63, 399
Acquired immunity, 303
  active, 304
  passive, 304
Acromioclavicular joint, 143
Acromion, 143
Act, reflex, structures involved in, 243
Active acquired immunity, 304
Adam's apple, 138, 368
Addison's disease, 482
Adduction of joint, 110
Adductor brevis muscle, 206
longus muscle, 206
magnus muscle, 206
tubercle, 159
Adductors of thigh, 206
Adenitis, 293
tubercular, 295
Adenoids, 368, 407
Adipose tissue, 67
  functions of, 75
Adrenalin, 482
as aid to coagulation of blood, 83
Adrenals, 481
active principle of, 482
function of, 482
medulla of, 482
Adrenin, 482
Adult and infant skeletons, differences between, 104
  spine, differences, in, 115
Afferent neurons, 86, 223
Age and sex in metabolism, 439
Agglutination, 303
Air, expired, oxygen and carbon dioxid in, proportion of, 380
gases of, how absorbed by blood, 380
inspired, carbon dioxid and oxygen in, proportion of, 380
minimal, in lungs, 377
residual, in lungs, 377
supplementary, in lungs, 377
tidal, in lungs, 377
Albumin in urine, 455, 456
  test for, 458
Alimentary canal, 324
  development of, 45
  divisions of, 395
  mucous membrane of, continuity, 60
    function, 395
  muscular coat of, function, 395
  serous coat of, function, 396
  submucous coat of, function, 395

Alveolar process, 131, 132, 136
Alveoli, 373
Ameba, 21
Amenorrhea, 469
Ametropia, 504
Amino-acids, 433
Amitosis, 24
Amphiarthrosis, 106
Amplitude of voluntary movement, norms for, 213
Ampulla, 515
Amylase, action of, 433
Anabolism, 24
Anal reflex, 248
Analogue, definition of, 20
Anaphylaxis, 305
Anastomosis of arteries, 327
Anatomic neck of humerus, 150
  position of body, 18
Anatomy, 18
Anemia, 80
  causes of, 80
Anesthetics, action of, on nervous tissue, 245
Ankle, 156
  hinge movement of, 109
  reflex, 248
Ankle-joint, ligaments of, 163
Anterior commissure, 235
  common ligament of spine, 118
  fontanel, 136
    closing of, 104
  inferior spine of ilium, 148
  intertrochanteric line, 157
  leg muscles, 208
  ligament of uterus, 467
  median fissure of spinal cord, 235
  nares, 365
  root of spinal nerve, 229
  sacro-iliac ligament, 148
  superior spine of ilium, 148
  surface of body, 19
  tibial artery, 340
Anterolateral fontanels, 138
Anteroposterior suture, lateral, 136
Anteversion of uterus, 466
Antrum, 101, 129, 509
  of Highmore, 131, 135
Anus, 422
Aorta, 286, 288, 328
  abdominal, 329, 336
    parietal branches, 336
    terminal divisions, 340
    visceral branches, 336
  arch of, 329
  ascending, 329
  branches of, 330
Aorta, descending, 329
  dorsal, 286
  thoracic, 329
    and its branches, 333
Aortæ, ventral, 285
Aortic opening in diaphragm, 187
  plexus, 282
  semilunar valves, 316
Apex of lung, 372
Aphasia, 270
Apnea, 378
Aponeuroses, 73
  of oblique and transversalis muscles, 181
Apoplexy, 353
Appendages, epiploic, 423
  of digestive system, 394
Appendicular skeleton, 104
Appendix, vermiform, 420
Appetite, 488
  gastric juice, inducing, 414
Aqueduct of Sylvius, 263
Aqueous humor, 501
Arachnoid, 226, 257
Arborization, terminal, 85
Arc, reflex, 245
Arch or Arches:
  branchial, 358
    in body, significance of, 18
  falling, of foot, muscle associated with, 208
  longitudinal, 159
    of foot, 165
  mediotarsal, 161, 165, 166
  neural, 115
  of aorta, 329
  of child's foot, 166
  of foot, 165
  palmar, deep, 332
    superficial, 332
  plantar, 341
  transverse, 161
    of foot, 165, 166
Areas of brain, 266
Areolar tissue, 67
    functions of, 74
Arm, 150
  bones of, relations of, 154
  muscles of, 195
Arrector pilorum, 490, 493
Arterial capillaries, 289
  pulse, 353
Arteriole, 325
Arteriosclerosis, 353
Artery or Arteries, 288
  anastomosis of, 327
  axillary, 332

Artery or Arteries:
basilar, 331
blood-supply of, 326
brachial, 332
projection of, 333
bronchial, 334
celiac, 336
common carotid, 330
iliac, 340
coronary, 317
cystic, 339
dorsalis pedis, 340
elastic tissue of, 326
endothelium of, 326
esophageal, 334
femoral, 340
gastric, 336
hepatic, 336
function of, 428
hypogastric, after birth, 358
innominate, 330
intercostal, 334
internal mammary, 331
lumbar, 336
mediastinal, posterior, 335
mesenteric, inferior, 339
superior, 339
muscle of, 326
nerve supply of, 327
nutrient, 150
of base of brain, 332
of heart, 316
of lower extremity, palpation points of, 341
projection of, 341
of neck, 331
ovarian, 340
pericardial, 334
peroneal, 340
phrenic, 336
plantar, 340
popliteal, 340
pulmonary, 288, 313
and branches, 328
radial, 332
projection of, 333
renal, 340
sacral, 336
spermatic, 340
splenic, 339
structure of, 325
subclavian, and branches, 331
palpation points, 333
projection of, 332
suprarenal, 339
systemic, 328
tibial, 340
ulnar, 332
Artery or Arteries:
ulnar, projection of, 333
umbilical, 356
uterine, 340
vertebral, 330
white fibrous tissue of, 326
Articular cartilages, 75
synovial membrane, 59
Articulate processes of spine, 116
Articulations, classification of, 106
movement in, 108
Artificial lung and thorax, 383
pneumothorax, 377
Ascending colon, 420
Ascites, 349, 362
Ash, composition of, of newborn child, 51
Asphyxiation, 379
Association neurons, 223
tracts of brain, 264
Asthmatic breathing, 379
Astigmatism, 504
Astralgus, 159
Atlas, ligaments of, 121
of spine, variations in, 117
Atmosphere, 380
Atrioventricular bundle, 315
valves, 313, 316
Atrophy of bone, 100
of muscle, 76
Attraction sphere of cell, 21
Auditory area of brain, 269
canal, external, 508
fossæ, 136
meatus, external, 129, 508
nerve, 273, 512
brain connection of, 259
organ, dual function of, 507
Auditory-speech areas of brain, 269
Auerbach, plexus of, 419
Auricles of heart, 312, 315
Auricular fibrillation, 354
Autacoids, 476
Automaticity of heart, 319
Autonomic nervous system, 225, 276. See also *Nervous system, autonomic.*
Axial skeleton, 104
Axillary artery, 332
temperature, 441
Axis, celiac, 336
ligaments of, 121
of spine, variations in, 117
thyroid, 331
Axon, 85, 223
medullated, 85
non-medullated, 85
Azygos veins, 345

Babinski reflex, 248
Baby, blue, 358
Back, hollow, 121
  muscles of, 184
Backward flexion of joint, 108
Bacteriolysis, 303
Barium meal, 415
Bartholin, glands of, 468
Basal metabolism, 440
    of boys, men, and women, 440
Basedow's disease, 478
Basement membrane, 61
Bases, purin, 438, 455
Basilar artery, 331
Basophils, 80
Biceps muscle, 195, 206
Bicipital groove of humerus, 150
  tuberosity of radius, 152
Bicuspid valve, 316
Bicuspids, 403
Big toe, opposable, 162
Bile, 429
  action of, 433
  characteristics of, 433
  flow of, 434
  salts, 433
Bile-duct, common, 429
Biologic inheritance, 52
Birth, changes in lungs at, 375
  circulatory changes after, 358
Birthmarks, 54
Bitters to stimulate gastric secretion, 414
Bladder, 452
  coats of, 453
  inflammation of, 454
  rugæ of, 453
Blind spot of eye, 503
Blindness, color, 502
Blood, 289
  absorption of air gases by, in respiration, 380
  coagulation of, 82
    time of, 82, 83
  composition of, 299
  function of, 80
  gases of, how enter tissues, 380
  in urine, 456
  of child, characteristics of, 306
  plasma, 299, 302
  temperature of, 301
  transfusion, 355
  volume, measures to increase, 354
Blood-cells, 25, 27, 299
  counting, 87
  red, 29, 77
    function of, 80
Blood-cells, white, 78
    function of, 81
Blood-count, 87
Blood-platelets, 80, 301
  function of, 82
Blood-pressure, 350
  determination of, 351
  diastolic, 352
  in children, 351
  pulse, 352
  systolic, 352
  variations in, 352
Blood-vessels, 324
  arrangement of, 327
  of breasts, 471
  of female generative organs, 468
  of kidney, 450
  of large intestine, 423
  of muscles, 173
  of pharynx, 410
  of small intestines, 418
  of stomach, 412
  of tongue, 398
  of tonsils, 399
  pulmonary, 328
  systemic, 328
Blue baby, 358
Bodies, malpighian, 432
  Nissl, 85
Body, anatomic position, 18
  carotid, 485
  cavities, 32
  cell, 20, 21
    of neuron, 85, 223
  ciliary, 499, 500
  coccygeal, 485
  composition of, 50
  development of, 35
  general plan, 31
  good and bad mechanical use of, 122
  midsternal line, 19
  of hyoid bone, 138
  of ischium, 147
  of os pubis, 147
  of vertebra, 115
  organization of, 26
  oxidation in, 22
  planes of, 18, 19
  study of, 17
  surfaces, 19
  terminology, 18
  vertebrate, 31
Bolus, 405
Bone or Bones:
  astralgus, 159
  atrophy of, 100

Bone or Bones:
breast, 140
carpal, 152
collar, 143
compact, 99
composition of, 92
in infant and adult compared, 105
cuboid, 159
cuneiform, of ankle, 159
of wrist, 152
depressions, 101
diaphysis of, 95
endochondral, 91
formation of, 94
epiphysis of, 95
ethmoid, 130
formation of, 91
fractures of, 100
frontal, 127
general characteristics, 100
growth of, 99
haversian systems of, 99
heel, 160, 165
hip-, 146
hyoid, 138
injury of, 100
intramembranous, formation of, 91
lacrimal, 133
lamellar systems of, 96
malar, 133
mandible, 132
maxilla, 131
nasal, 133
occipital, 126
ligaments of, 121
of arm, relations of, 154
of cranium, 125
of face, 125
of foot, 160
of forearm, 151
of left hand, 153
of lower extremity, 155
of upper extremity, 150
os magnum, 152
ossification of, 94
palate, 133
parietal, 127
pisiform, 152
projections, 101
scaphoid, 152, 159
semilunar, 152
sphenoid, 130
spongy, 71, 99
temporal, 128
tissue, 70
functions of, 75
Bone or Bones:
trapezium, 152
trapezoid, 152
turbinate, 366
inferior, 133
middle, 130
superior, 130
unciform, 152
vomer, 133
wormian, 106
Bone-marrow, 95, 98
Bow-legs, 164
in rickets, 100
Bowman's capsule, 448
β-oxybutyric acid, 437
Brachial artery, 332
projection of, 333
plexus, 232
Brachialis anticus muscle, 195
Brain, 252
activity in children, 271
areas, 266
auditory, 269
auditory-speech, 269
motor, 268
sensory, 268
smell and taste, 269
speech and writing, 269
visual, 268
speech, 270
base, arteries of, 332
casket, bones of, 125
cells, 85
defects in, visual defects from, 507
divisions of, 257
evolution of, 221
general characteristics, 255
growth of, 253
membranes of, 256
points of connection with nerves, 259
relation of, to skull, 262
tracts of, 264
association, 264
commissural, 264
projection, 265
tumors of, paralysis from, 274
ventricles of, 263
weight of, 252
Brain-sand, 485
Branchial arches, 18, 358
Breast bone, 140
Breasts, 470
development of, 471
glandular tissue of, 470
in pregnancy, 471
lobes of, 470

Breasts, lobules of, 470
vessels and nerves of, 471
Breathing, asthmatic, 379
Cheyne-Stokes, 379
costal, 378
diaphragmatic, 378
different types, 377
labored, 379
Breathlessness, 379
Brünners glands, 417
Broad ligament, 462, 465, 467
Broca's convolution, 269
Bronchi, 370, 371
Bronchial arteries, 334
Bronchioles, 371
Brush, end, 85
Buds, taste, 398, 496
Bulbs, end, of Krause, 492
Bundle, atrioventricular, 315
of His, 315
Burdach and Goll, columns of, 238
Bursæ, 107
subacromial, 107
Bursal synovial membrane, 59
Bursitis, 107

Calcaneocuboid ligaments, 166
Calcaneoscaphoid ligament, 166
Calcium in coagulation of blood, 82
Calculi in urine, 456
Calices of kidney, 450
Callus of fracture, 100, 101
Calorie, 440
Canal, alimentary, 394
development of, 45
mucous membrane of, continuity, 394
auditory, external, 508
cochlear, 510
hyaloid, 501
inguinal, 182
and hernia, 183
neural, 115
posterior dental, 131
semicircular, 134, 515
Canine ear, 52
Canines, 403
Capillaries, 288,325
arterial, 289
pulmonary, 328
systemic, 342
venous, 289
Capitellum of humerus, 150
Capsular ligament, 153, 162, 163, 166
Capsule, 73, 293
Bowman's, 448
Capsule of kidney, 448
suprarenal, 481
Caput medusæ, 349
Carbohydrates, absorption of, 437
hydrolysis of, 405, 407
metabolism of, 437
Carbon dioxid in inspired and expired air, proportion of, 380
in muscle, 174
Cardia, 410
Cardiac center, 317
cycle, 317
muscle, 29, 76
notch, 374
plexus, 282, 317
veins, 342
Carotid arteries, common, 330
palpation points of, 330
projection of, 330
body, 485
Carpal bones, 152
Carpus, 152
Cartilage or Cartilages:
articular, 75
costal, 75, 140, 142
cricoid, 368
elastic, 70
ensiform, 142
epiphyseal, 95
hyaline, 68,69
nasal, 75
semilunar, 163
thyroid, 368
yellow fibrous, 70
Cartilaginous tissue, 69
functions of, 75
Casket, brain, bones of, 125
Casts in urine, 456
Catabolism, 24
Cataract of eye, 500
Cathartics, action of, 424
Caval opening in diaphragm, 187
Cavity or Cavities, 101
abdominal, 392
body, 32
cranial, 134
dorsal, 32
glenoid, 143
marrow, 71, 95
medullary, 98
of middle ear, 134
of skull, 134
pelvic, true, 145
peritoneal, 33
thoracic, 33
tympanic, 134, 509
ventral, 33

Cecum, 420
Celiac axis, 336
Cell or Cells, 20
  anabolism of, 24
  and heredity, 51
  attraction sphere, 21
  blood, 25, 27, 299
    red, 29
  body, 21
    of neuron, 85, 223
  brain, 85
  catabolism of, 24
  centrosome, 21
  chief, of gastric glands, 411
    of pituitary gland, 483
  chromatin, 21
  chromophil, of pituitary gland, 483
  classification, 26
  conductivity of, 23
  connective-tissue 25, 26
  contractility of, 23
  correlation of, 23
  cytoplasm, 21
  demilune, 399
  differentiation, 25
  egg-, 35
  embryonal, 20
  epithelial, 25, 26
  ethmoidal, 130
  fat, 67
  glia, 72
  goblet, 371
  irritability of, 23
  limiting membrane, 21
  living functions of, 22
  lymphoid, 294
  mastoid, 129, 135, 509
  metabolism of, 24
  muscle, 25, 26
    smooth, 28
  nerve, 25, 27
  neurogliar, 73
  nucleolus, 21
  nucleus, 21
  of Purkinje, 260
  parietal, of gastric glands, 411
  pregnancy, 484
  protoplasm, 20
  reproduction, 24
    direct method, 24
    indirect method, 24
  segmentation, 24
  sex, 24
  specialization, 25
Cellular tissue, 27
Cellulitis, 74
Center, cardiac, 317
  glycogenic, 437
  heat, 441
  respiratory, 381
  vasomotor, 327
Centers of medulla oblongata, 260
Central vein of liver, 429
Centrosome, 21
Cerebellar tracts of spinal cord, 238
Cerebellum, 260
  function of, 260
  hemispheres of, 260
  vermis of, 260
Cerebral fluid, 228
  localization, 267
Cerebrospinal fluid, 228
  nervous system, 225
    autonomic nervous system, connection between, 278
    general arrangement of, 224
Cerebrum, 262
  great longitudinal fissure of, 262
  hemispheres of, 262
Cerumen, 496, 508
Ceruminous glands, 496, 508
Cervical curve of spine, 114
  enlargement of spinal cord, 238
  lymphatic ducts, 291
  vertebræ, 113
Cervix of uterus, 465
    external os of, 465
Chalones, 476
Characters, dominant, 53
Charley horse, 205
Chemistry of muscle, 174
Chest malformations in rickets, 100
  mobility, U. S. Army requirements, 382
  muscles of, 189
  wall, projection of heart on, 310
    of lungs on, 374
Cheyne-Stokes respiration, 379
Chiasma, optic, 501
Chief cells of gastric glands, 411
    of pituitary gland, 483
Child, blood of, characteristics, 306
  blood-pressure in, 351
  brain activity in, 271
  foot of, arch, 166
  lungs in, 375
  newborn, composition of ash of, 51
  tactile sensibility in, 490
Chin angle, changes in, during life, 132
Chlorosis, 81
Choking reflex, 369

Cholin, 482
Chordæ tendinæ, 315, 316
Chorion, 49
Choroid, 500
Chromatin, 21
Chromophil cells of pituitary gland, 483
Chromosomes, 36
as bearers of heredity, 53
X and Y, 37
Chyme, 415
Cilia, 62
Ciliary body, 499, 500
glands of eyelids, 496
Ciliated epithelium, 62
infusorium, 88
Circle of Willis, 327, 330
Circulation, fetal, 355
changes after birth, 358, 360
in kidney, 452
portal, 288
pulmonary, 288, 328
systemic, 288, 328
venous, of portal system, 429
Circulatory system, 31, 284
development of, 284
general arrangement, 288
Circumduction of joint, 110
Circumvallate papillæ of tongue, 398
Clark's column, 238
Clavicle, 143
Cleft palate, 396
Climacteric, 470
Clitoris, 368
Cloaca, 445
Club-foot, 217
Coagulation of blood, 82
time of blood, 82, 83
Coccygeal body, 485
vertebræ, 113
Coccygeus muscle, 201
Coccyx, 118
Cochlea, 134, 510
membranous, 510
Cochlear canal, 510
Colic, gall-bladder, 429
Collar bones, 143
Collaterals, 85
Colles' fracture, 155
Colloid, 477, 483
Colon, 420
ascending, 420
descending, 421
dilatation of, 423
irrigations, 423
sigmoid, 421
Colon, transverse, 420
Color blindness, 502
vision, 502
Coloring materials in urine, 456
Column, Clark's, 238
Columnar epithelium, simple, 59
stratified, 62
Columns of Burdach and Goll, 238
Commissure, anterior, 235
posterior, 238
Commissural tracts of brain, 264
Common bile-duct, 429
carotid arteries, 330
iliac arteries, 340
veins, 346
Compact bone, 99
Complement, 303
Composition of body, 50
Concentric contraction of muscle, 177
Conductivity of cells, 23
of nervous tissue, 87
Condyles, 101, 127, 132
of femur, 158
of humerus, 150
Congenital defects, 54
Conjunctival sac, 498
Connective tissue, 28
function of, 66, 73
Connective-tissue cells, 25, 26
Constrictions of esophagus, 410
Contractility of cells, 23
Contraction, concentric, of muscle, 177
eccentric, of muscle, 177
of heart, 317
causes of, 319
of muscle, 173
factors in, 175
premature, of heart, 354
static, of muscle, 177
tonic, of muscle, 176
Conus, 226
Convoluted tube, first, of kidney, 448
second, of kidney, 448
Convolution, Broca's, 269
Coracobrachialis muscle, 195
Coracoid process, 143
Cord, spermatic, 472
spinal, 226
umbilical, 45, 356
after birth, 360
Cords, vocal, 369
Corium, 61
Cornea, 500
Cornua of hyoid bone, 138

Coronal suture, 136
Coronary arteries, 317
ligament, left, 427
right, 427
sinus, 317
Coronoid fossa of humerus, 150
process, 132
of ulna, 152
Corpus callosum, 262, 264
luteum, 463
Corpuscles, 492
lymph, 294
Meissner's, 492
of Hassall, 480
Pacinian, 492
Vater-Pacinian, 234
white, 299, 300
Correlation, nervous, 475
of cells, 23
of nervous tissue, 87
Cortex, 262
development of, 253
lobes of, 263
of hair, 493
of kidney, 449
Corti, organ of, 510
Coryza, conditions associated with, 366
Costal cartilages, 75, 140, 142
respiration, 378
Cough from coryza, 366
Cowper's glands, 473
Cranial autonomic system, 278
cavity, 134
nerves, 271
table of, 273
portion of skull, 126
Cranium, bones of, 125
sinuses of, 257
Creatin, 438
Creatinin, 438
Cremaster reflex, 248
Crest, 101
of ilium, 147
Cretinism, 477, 478
bones in, 100
Cricoid cartilage, 368
Cristi galli, 130
Crucial ligaments, 162
Crureus muscle, 205
Crypts of tonsils, 399
Cuboid bone, 159
Culdesac of Douglas, 467
Cuneiform bone of ankle, 159
of wrist, 152
Curves of spine, 113
primary and secondary, 115
Cuticle of hair, 493
Cycle, cardiac, 317
Cystic artery, 339
duct, 429
Cystitis, 454
Cytoplasm, 21

Deciduous teeth, 402
eruption of, 402
Decussation, motor, 239
Deep fascia, 74, 75
palmar arch, 332
veins, 327, 342
Defects, congenital, 54
Deformity of lower extremity, 164
of pelvis, 149
Degeneration, fatty, 67, 437
of spinal cord tracts, 241
reaction of, and motor points, 214
stigmata of, 52
Deltoid muscle, 195
tuberosity, 150
Demilune cell, 399
Dendrites, 85, 223
Dental canal, posterior, 131
foramen, inferior, 132
nerve, inferior, 132
Dentin, 71
Dentinal tubules, 71
Dentition, delayed, 402
Depressants, respiratory, 382
Depressions of bone, 101
Derma, 490
Descending aorta, 329
colon, 421
Determiners, 53
Diabetes mellitus, 431, 438
Dialysis, 435
Diaphragm, 186
openings, 187
Diaphragmatic respiration, 378
Diaphysis, 95, 100
Diarthrosis, 106
Diastole of heart, 317
Diastolic blood-pressure, 352
Differentiation of cells, 25
Diffusion, 435
Digestion in intestines, 432
in mouth, 403
in stomach, 412
Digestive ferments, 394
system, 31, 386
development of, 387
general characteristics, 394
Dilatation of colon, 423
of heart, 321
Diploë, 93

Disaccharids, 433
Discriminating touch, 490
Disks, intervertebral, 75, 118
Dislocation of hip and patella, 164
  of knee-joint, 164
  of shoulder, 153
  of spine, 124
Distal tubule of kidney, 448
Diverticulum, Meckel's, 419
Dominant characters, 53
Dorsal aorta, 286
  cavity, 32
  surface of body, 19
Dorsalis pedis artery, 340
Douglas, culdesac of, 467
Dropped beat, 354
Drum membrane, 508
Duct or Ducts, 291
  cystic, 429
  ejaculatory, 472
  excretory, of kidneys, 451
  Gärtner's, 461
  hepatic, 429
    function of, 428
  lymphatic, cervical, 291
    right, 291
  mesonephric, 446
  müllerian, 446
  nasal, 498
  of Santorini, 416, 431
  of Wirsung, 416, 431
  pronephric, 445
  thoracic, 291
Ductus arteriosus, 358
    after birth, 358
  venosus, 357
    after birth, 359
Duodenum, 415
Dura mater, 226, 256
Dwarfism, 483
Dysphagia from coryza, 366
Dyspnea, 379
  causes of, 379

Ear, canine, 52
  external, 507
  how it hears, 512
  internal, 134, 509
    two parts of, 510
  middle, 128, 509
    cavity of, 134
  wax, 496, 508
Earache from coryza, 367
Eccentric contraction of muscle, 177
Ectoderm, 41
  derivatives of, 46
  developmental changes in, 41
Ectopic gestation, 474
Edema, 74, 291
Effectors, 86, 176, 234
Efferent neurons, 86, 223
Effusion, 291
Egg-cell, 35
Ehrlich's theory of immunity, 303, 304
Ejaculatory ducts, 472
Elastic cartilage, 70
  tissue of arteries, 326
Elbow-joint, 152
  left, 155
Electrocardiography, 321
Embolus, 82
Embryo, composition of, 50
  definition, 18
  formation of, 35
  of twenty-eight days, 114
  of twenty-one days, 44
Embryonal cells, 20
Embryonic layers, appearance of, 41
    derivatives of, 45
Eminence, hypothenar, 199
  thenar, 199
Emmetropia, 504
Emotional states and activity of autonomic nervous system, relation between, 276
Empyema, 374
Emulsification of fats, 433
Enamel, 71
Encephalocele, 274
End-brush, 85
End-bulbs of Krause, 86, 234, 492
Endocarditis, 315
Endocardium, 58, 315
Endochondral bone, 91
    formation of, 94
Endocrine system, 31, 475
    organs of, 476
Endolymph, 510
End-organ of efferent neuron, 30
  of Ruffini, 492
  of spinal nerves, 234
Endosteum, 99
Endothelia, 57
Endothelium, 58
  of arteries, 326
  of veins, 326
Enemata, 423
Ensiform cartilage, 142
Enterokinase, 417, 433
Entoderm, 41
  derivatives of, 46
  developmental changes in, 45
Enuresis, 456

Enzymes, 65, 394
demonstrating action of, 87
of intestinal juice, 433
of pancreatic juice, 433
Eosinophils, 80
Epidermis, 490
Epididymis, 472
Epiglottis, 369
Epineurium, 231
Epiphyseal cartilage, 95
Epiphysis, 95, 100
Epiploic appendages, 423
Epithelial cells, 25, 26
tissue, 28, 56
Epithelium, 57
ciliated, 62
columnar simple, 59
stratified, 62
functions of, 64
germinal, 463
glandular, 63
goblet, 62
modified, 62
pigmented, 62
squamous, simple, 57
stratified, 62
Epoöphoron, 462
Equilibrium, 260
nitrogen, 438
sense of, 507
Erector spinæ muscle, 184
Erepsin, 417, 433
Erythroblasts, 300
Erythrocytes, 77, 299
counting, 87
function of, 80
in child's blood, 306
Esophageal arteries, 334
opening in diaphragm, 187
Esophagus, 410
constrictions of, 410
Ethmoid bone, 130
Ethmoidal cells, 130
sinuses, 130, 135
Eupnea, 378
Eustachian tubes, 368, 407, 509
valve, 316
Evolution of nervous system, 219
Excretory ducts of kidneys, 451
system, 31, 444
development of, 444
Exercise, muscular, in metabolism, 439
Exophthalmic goiter, 477
Expansion of lungs, 377
Expired air, oxygen and carbon dioxid in, proportion of, 380
Extension of joint, 108
Extensor brevis pollicis muscle, 199
carpi radialis brevior muscle, 198
longior muscle, 198
ulnaris muscle, 199
communis digitorum muscle, 199
indicis muscle, 199
longus digitorum muscle, 208
hallucis muscle, 208
pollicis muscle, 199
minimi digiti muscle, 199
ossis metacarpi pollicis muscle, 199
External auditory canal, 508
meatus, 129, 508
carotid artery, 330
ear, 507
iliac artery, 340
intercostal muscles, 187
oblique muscle, 179
aponeurosis of, 181
occipital projection, 127
os of cervix, 465
plantar artery, 341
skeleton, 90
Extrasystole, 354
Extremity, lower, arteries of, palpation points of, 341
projection of, 341
bones of, 155
injury and deformity of, 164
ligaments of, 162
lymph-nodes of, 297
motor points in, 216
muscles of, classification, 211
upper, bones of, 150
injuries of, 153
ligaments of, 153
lymph-nodes of, 296
motor points in, 215
muscles of, classification of, 199
Extrinsic foot muscles, 211
Eye, 497, 498
ametropic, 504
blind spot of, 503
demonstrating, 503
cataract of, 500
cavity of, 501
defects in, defects of vision due to, 504
development of, 497
emmetropic, 504
how it sees, 503
muscles of, 502
outerparts, 498
structure of, 499
Eyeball, 499

Eyelids, 498
ciliary glands of, 496
meibomian glands of, 494, 499

Face ache from coryza, 367
bones of, 125
muscles of, 190
surface markings of, 135
Facial nerve, 273
brain connection of, 259
portion of skull, 126
Falciform ligament, 427
Fallopian tubes, 462, 464
False pelvis, 145
vocal cords, 369
Falx cerebri, 257
Fascia, 67, 74
deep, 74, 75
superficial, 74
Fat cell, 67
Fatigue of muscle, 77, 174
absorption of, 436
emulsification and saponification of, 433
metabolism of, 436
Fatty acids, 433
degeneration, 67, 437
Fauces, pillars of, 397
Female pronucleus, 38
Femoral artery, 340
Femur, 157
condyles of, 158
Fenestra ovalis, 509, 510
rotundum, 509
Ferments, 65
digestive, 394
Fertilization of ovum, 38
process, 39
Fetal circulation, 355
changes after birth, 358, 360
Fetus, definition, 18
external appearance, 46
full-grown, composition of, 50
maternal impressions no influence on, 53
nourishment of, 47
Fibers, postganglionic, 279
preganglionic, 279
Fibrillation, auricular, 354
Fibrils, 76
Fibrin, 82
Fibrinogen, 82
Fibrocartilage, white, 70
Fibrous cartilage, yellow, 70
tissue, white, 66
functions of, 73
of arteries, 326
Fibrous tissue, yellow, 67
functions of, 73
Fibula, 159
and tibia in normal relations, 158
Filiform papillæ of tongue, 398
Fimbriæ, 465
Fingers, 150
First convoluted tube of kidney, 448
ventricle, 264
Fissure, anterior median, of spinal cord, 235
great longitudinal, of cerebrum, 262
of Rolando, 262
of Sylvius, 262
Flat-foot, 165
Flexion, backward, of joint, 108
of joint, 108
Flexor carpi radialis muscle, 197
ulnaris muscle, 196
longus digitorum muscle, 210
hallucis muscle, 210
pollicis muscle, 197
profundus digitorum muscle, 197
sublimis digitorum muscle, 197
Flexure, hepatic, 420
splenic, 421
Fluid, cerebral, 228
cerebrospinal, 228
hypertonic, 436
hypotonic, 436
isotonic, 436
pericardial, 309
peritoneal, 393
prostatic, 472
seminal, 473
spinal, 228
Follicles, Graafian, 36, 462
hair, 492
Fontanel or Fontanels, 93
anterior, 136
closing of, 104
anterolateral, 138
of skull, 136
posterior, 137
posterolateral, 138
Food digestion in intestines, 432
in mouth, 403
in stomach, 412
what happens in mouth, 403
Foot, 156
and hand, differences in, 156
arches of, 165
bones of, 160
child's arch of, 166
club-, 217

Foot, falling arch of, muscle associated with, 208
flat-, 165
muscles of, 211
extrinsic, 211
intrinsic, 211
phalanges of, 162
tendons, 165
Foramen, 101
inferior dental, 132
infra-orbital, 131
magnum, 126
mental, 132
of Magendie, 264
optic, 132
ovale, 358
after birth, 358
Foramina of Luschka, 264
of Monro, 264
Forearm, 150
bones of, 151
excessive length of, 150
muscles of, 195
tabulation of, 198
strength of, in males, 213
Fossa or Fossæ, 101
auditory, 136
coronoid, of humerus, 150
iliac, 148
infraglenoid, 143
infraspinous, 143
mandibular, 129
nasal, 135, 365
of skull, 135
olecranon, of humerus, 150
orbital, 135
ovalis, 316
subscapular, 143
supraglenoid, 143
supraspinous, 143
temporal, 136
zygomatic, 136
Fossier's measurement of heart, 322
Fourth ventricle, 263
Fovea centralis, 501
Fracture, callus of, 100, 101
Colles', 155
greenstick, 100
of bone, 100
setting of, 100
Frenum, 398
contraction of, 398
Fribrinogen, 82
Frontal bone, 127
headache from coryza, 366
lobe, 263
sinuses, 127, 134
Fundus, 410
of uterus, 465
Fungiform papillæ of tongue, 398
Funiculi, 230

Gall-bladder, 429
colic, 429
Gall-stones, 429
Ganglia, outlying, of autonomic nervous system, 282
Gärtner's duct, 461
Gases in urine, 456
of air, how they enter blood, 380
of blood, how they enter tissues, 380
Gastric artery, 336
digestion, 412
glands, 411
juice, 413
production of, 414
stimulation of flow, 414
veins, 348
Gastrocnemius muscle, 208
Gastroepiploica sinistra, 339
Gastrohepatic omentum, 412
Generative organs, common origin of, in male and female, 460
female, 461
internal, arrangement of, 461
vessels and nerves of, 468
male, 471
Genital gland, 460, 462
Genito-urinary tract, continuity of mucous membrane in, 61
Genu valgum, 164
varum, 164
Germ glands, 484
function of, as internal secretory organs, 484
Germinal epithelium, 463
Gestation, ectopic, 474
Giantism, 483
Gill arches in body, significance of, 18
Girdle, pelvic, 143
shoulder, 143
Glabella, 127
Gladiolus, 142
Gland or Glands, 63, 411
Brünners, 417
ceruminous, 496, 508
ciliary, of eyelids, 496
Cowper's, 473
different forms, 64
genital, 460, 462
germ, 484

Gland or Glands:
internal secretory, definition of, 475
lacrimal, 498
mammary, 470. See also *Breasts.*
meibomian, 494, 499
of Bartholin, 468
of Lieberkühn, 417
of Luschka, 485
of skin, 494
parathyroid, 478
parotid, 64, 399
pineal, 485
pituitary, 483
salivary, 399
sebaceous, 494
sublingual, 399
submaxillary, 399
sweat, 495
thymus, 480
thyroid, 476
urethral, 468
uterine, 465
Glandular epithelium, 63
Glans penis, 473
Glenoid cavity, 143
Glia cells, 72
Glomerulus, 445
of kidney, 448, 450
Glossary, 517
Glossopharyngeal nerve, 273
brain connection of, 259
Glottis, 369
Gluteal reflex, 248
Gluteus maximus muscle, 201
medius muscle, 203
minimus muscle, 204
Glycogen in liver, 437
in muscle, 174
Glycogenic center, 437
Glycosuria, 438
Goblet cells, 371
epithelium, 62
Goiter, exophthalmic, 477
Goll and Burdach, columns of, 238
Gonad, 445
Graafian follicle, 36, 462
Gracilis muscle, 206
Gray matter of spinal cord, 235
Great longitudinal fissure of cerebrum, 262
sacrosciotic ligaments, 148
Greater omentum, 412
Greenstick fracture, 100
Gristle, 69
Groove, 101
bicipital, of humerus, 150
musculospiral, of humerus, 150
Hair, 492
layers of, 493
root of, 493
shaft of, 493
Hair-follicle, 492
Hamstring muscles, 206
Hand, 150
and foot, differences in, 156
left, bones of, 153
muscles of, 195
tabulation of, 198
phalanges of, 152
Hard palate, 397
Harelip, 396
Hassall, corpuscles of, 480
Haustra, 422
Haversian systems, 99
Head, muscles of, 190
of femur, 157
of humerus, 150
of infant and adult compared, 106
of newborn, shape of, 138
veins of, 343
Headache from coryza, 366, 367
Head's zones, 233
Hearing, mechanism of, 512
sense of, 507
Heart, 307
arteries of, 316
auricles of, 312, 315
automaticity of, 319
component parts, 312
contraction of, 317
causes, 319
development of, 287
diastole of, 317
dilatation of, 321
dropped beat, 354
experimental perfusion of, 319
Fossier's measurement, 322
how it works, 317
hypertrophy of, 320
lining of, 315
murmurs, 320
muscle, 314
nerves of, 317
pace-maker of, 318
premature contraction, 354
projection of, on chest wall, 310
relaxation of, 317
shape and size, 309
sounds of, 319
systole of, 317
valves of, 313, 316
valvular lesions, 320
veins of, 316
ventricles of, 312, 316

Heart, voluntary acceleration of, 272
Heart-beat, cause of, 318, 319
myogenic theory, 319
neurogenic theory, 319
rate of, at different ages, 318
Heart-block, 354
Heat center, 441
dissipation, 440
loss from body by conduction
from body surfaces, 441
by excreta, 441
by radiation, 441
production, 440
regulation, 440
Heel bone, 160, 165
Height, effect of internal secretions on, 483
Heliotropism, 496
Hematocytometer, Thoma-Zeiss, 88
Hemianopsia, 268
homonymous, 506
Hemispheres of cerebellum, 260
of cerebrum, 262
Hemoglobin, 78, 300
reduced, 300
Hemolysis, 355
Hemophilia, 82
Hemophiliac, 82
Hemorrhage, 322
Henle, loop of, 448
ascending limb, 448
descending limb, 448
Hepatic artery, 336
function of, 428
duct, 429
function of, 428
flexure, 420
Hepatoduodenal ligaments, 412
Hepatogastric ligaments, 412
Heredity, 52
cells and, 51
chromosomes as bearers, 53
Hernia, conditions favoring, 184
inguinal canal and, 183
Hesselback's triangle, 183
Highmore, antrum of, 131, 135
Hilum, 373
of kidney, 448
Hinge movement of ankle, 109
of wrist, 109
Hip, dislocations of, 164
muscles of, classification, 211
Hip-bone, 146
Hip-joint, ligaments of, 162
muscles of, 201
Hirschsprung's disease, 423
His, bundle of, 315
Hollow back, 121
Homologue, definition of, 20
Homonymous hemianopsia, 506
Hormones, 476
Horseshoe kidney, 446
Humor, aqueous, 501
vitreous, 72, 502
Humoral theory, 475
Hunger, 488
Hyaline cartilage, 68, 69
Hyaloid canal, 501
Hydrocephalus, 274
Hydrochloric acid, 411
action of, 413
Hydrolysis of carbohydrates, 405, 407
Hymen, 468
Hyoid bone, 138
Hyperemia, 349
Hyperextension of joint, 108
Hyperglycemia, 438
Hyperopia, 504
Hypertonic fluid, 436
Hypertrophy of heart, 320
of muscle, 77
Hypodermoclysis, 350
Hypogastric arteries after birth, 358
plexus, 282
Hypoglossal nerve, 273
Hypophysis, 483
Hypothenar eminence, 199

Ileum, 416
Iliac arteries, common, 340
fossa, 148
veins, 346
Iliacus muscle, 201
Iliofemoral ligament, 162
Iliolumbar ligament, 148
Iliopectineal line, 145
Ilium, 147
Illusions, optical, 514, 515
Immunity, 302
acquired, 303
active, 304
passive, 304
Ehrlich's theory, 303, 304
inherited, 303
Impressions, maternal, 53
Impulse, nerve, 243
Incisors, 403
Incontinence of urine, 457
Incus, 134, 509
Index, opsonic, 81
Indican in urine, 456
Infant and adult skeletons, difference between, 104

Infant and adult spine, differences in, 115
lungs in, 375
Inferior dental foramen, 132
nerve, 132
mesenteric artery, 339
vein, 348
oblique muscle, 192
rectus muscle, 191
turbinate bones, 133
vena cava, 313, 342, 345
Inflammation, 300
of bladder, 454
stages of, 301
Infraglenoid fossa, 143
Infra-orbital foramen, 131
Infraspinatus muscle, 194
Infraspinous fossa, 143
Infundibulum, 371, 373
Infusorium, ciliated, 88
Inguinal canal, 182
and hernia, 183
Inheritance, biologic, 52
Injuries of bones, 100
of lower extremity, 164
of spine, 124
of upper extremity, 153
Inlet, pelvic, plane of, 145
Innominate artery, 330
Inorganic substances in urine, 455
Inspired air, oxygen and carbon dioxid in, proportion of, 380
Insulin in diabetes, 438
Intercondylar notch, 158
Intercostal arteries, 334
muscles, external, 187
internal, 188
Internal carotid artery, 330
ear, 134, 509
two parts of, 510
iliac artery, 340
intercostal muscles, 188
mammary artery, 331
oblique muscle, 180
aponeurosis of, 181
plantar artery, 341
secretions, effect of, on height, 483
nature of, 475
secretory gland, definition of, 475
Interossei muscles, 199
Interosseous membrane, 165
Interspinous ligament, 120
Intertrochanteric line, anterior, 157
posterior, 157
Intervertebral disks, 75, 118
Intestinal canal, development of, 389
contents, movement of, 434
Intestinal digestion, 432
juice, 417
enzymes of, 433
flow of, 434
soaps, 433
Intestine, large, 420
coats of, 422
mucous coat, 422
muscular layer, 422
serous coat, 423
submucous layer, 422
vessels and nerves of, 423
small, divisions of, 415
length of, 415
lymph-nodules of, 417
mucous coat, 416
muscular coat, 417
serous coat, 417
structure of, 416
submucous coat, 416
valvulæ conniventes of, 417
vessels and nerves of, 418
villi of, 417
Intracranial disturbance from coryza, 367
Intramembranous bone, formation of, 91
Intra-orbital disturbance from coryza, 367
Intrinsic foot muscles, 211
Intubation, 382
Invertase, 417, 433
Involuntary muscle, 76
Iris, 499
Iris, muscles of, 500
Irrigation of colon, 423
Irritability of cells, 23
of nervous tissue, 87
Ischium, 147
Island of Reil, 263
Islands of Langerhans, 431
Isotonic fluid, 436
Isthmus, 476

Jaundice, 429
Jaw of infant and adult, compared, 105
reflex, 248
Jejunum, 416
Jelly, Wharton's, 72
Joint, abduction of, 110
acromioclavicular, 143
adduction of, 110
backward flexion of, 108
circumduction of, 110
classification of, 106
elbow-, 512

Joint, extension of, 108
flexion of, 108
freely movable, 106
hyperextension of, 108
immovable, 106
knee-, 157
lumbosacral, 118
movement in, 108
rotation of, 110
sacrococcygeal, sprain of, 149
sacro-iliac, 118, 148
sprain of, 149
slightly movable, 106
suture of, 106
true, 106
Jugular veins, 343
Juice, gastric, 413
production of, 414
intestinal, 417
enzymes of, 433
flow of, 434
pancreatic, 431
enzymes of, 433
flow of, 434

Kidney, 477
beginning of, 446
blood-vessels of, 450
calices of, 450
capsule of, 448
circulation in, 452
cortex of, 449
distal tubule of, 448
excretory ducts of, 451
glomeruli of, 448, 450
hilum of, 448
horseshoe, 446
internal structure, 448
medulla of, 449
misplaced, 446
movable, 446
nerves of, 450
papillæ of, 448
pelvis of, 450
proximal tubule of, 448
second convoluted tubule of, 448
secretion of, factors modifying, 457
of urine by, 454
uriniferous tubule of, 448, 449
Knee, knock-, 164
Knee-cap, 163
Knee-joint, 157
dislocation of, 164
ligaments of, 162
Knock-knee, 164
Krause, end-bulb of, 86, 234, 492
Krogh's theory of capillary tonus, 350
Kyphosis, 121

Labia majora, 468
minora, 468
Labyrinth, 509
Lacrimal bones, 133
glands, 498
Lacrimation from coryza, 306
Lactase, 417
Lacteal, 417
Lactic acid in muscle, 174
Lacunæ, 71, 95
Lambdoidal suture, 136
Lamellar systems, 96
Laminæ of vertebra, 115
Langerhans, islands of, 431
Large intestine, 420. See also *Intestine, large.*
Laryngopharynx, 408
Larynx, 368
Lateral anteroposterior suture, 136
cuneiform bone, 159
leg muscles, 211
malleolus, 159
rectus muscle, 191
sinus, 127, 129
ventricles, 264
Latissimus dorsi muscle, 185
Layer, malpighian, 401, 490
parietal, 59
visceral, 59
Left coronary ligament, 427
lung, 375
Leg, 155, 156
bow-, 164
muscles of, 207
anterior, 208
lateral, 211
posterior, 208
shortened, scoliosis from, 124
Lens, 499, 500
Lesser omentum, 412
Leukocytes, 78, 299, 300
function of, 81
in child's blood, 306
margination of, 300
migration of, 301
mononuclear, 29, 80
polymorphonuclear, 80
transitional, 29, 80
with polymorphous nucleus, 29
Leukocytosis, 80
Leukopenia, 80
Levator ani, muscle, 201
muscle, superior, 191

Levator scapulæ muscle, 192
Lieberkühn, glands of, 417
Ligament or Ligaments, 73
anterior common, of spine, 118
of uterus, 467
sacro-iliac, 148
broad, 462, 465, 467
calcaneocuboid, 166
calcaneoscaphoid, 166
capsular, 152, 162, 163, 166
coronary, left, 427
right, 427
crucial, 162
falciform, 427
function of, 171
great sacrosciatic, 148
hepatoduodenal, 412
hepatogastric, 412
iliofemoral, 162
iliolumbar, 148
interspinous, 120
lesser sacrosciatic, 148
of atlas, 121
of axis, 121
of lower extremity, 162
of occipital bone, 121
of pelvis, 148
of spine, 118
of upper extremity, 153
of uterus, 466
ovarian, 462
posterior common, of spine, 120
of uterus, 467
sacro-iliac, 148
Poupart's, 149
rectovaginal, 467
round, 162, 360, 427, 467
scaphocuneiform, 166
supraspinous, 120
suspensory, 462, 500
uterosacral, 467
uterovesical, 467
vesico-uterine, 454
Y, 162
Ligamenta subflava, 120
Ligamentum nuchæ, 120
subflavum, 73
Line, anterior intertrochanteric, 157
iliopectineal, 145
midsternal, of body, 20
oblique, of tibia, 159
posterior intertrochanteric, 157
Linea aspera, 158
Lingual tonsil, 399
Lipase, action of, 433
Liver, 426. See also *Hepatic.*
glycogen in, 437
Liver, internal structure, 429
lobes of, 427
lobules of, 429
secretion of, 429
surfaces of, 427
Lobes of breast, 470
of cortex, 263
of liver, 427
of lung, 374
of pituitary gland, 483
Lobster, 90
Lobules of breast, 470
of liver, 429
Localization, cerebral, 267
Locke's solution, 319
Locomotor ataxia loss of muscle sense in, 261
Longitudinal arch, 159
of foot, 165
Loop of Henle, 448
ascending limb, 448
descending limb, 448
Lordosis, 121
Lower extremity, arteries of, palpation points of, 341
projection of, 341
bones of, 155
injury and deformity of, 164
ligaments of, 162
lymph-nodes of, 297
motor points in, 216
muscles of, classification, 211
Lumbar arteries, 336
curve of spine, 114
enlargement of spinal cord, 238
vertebræ, 113
Lumbosacral joint, 118
Lumbricales muscles, 199
Lungs, 372
alveoli of, 373
apex of, 372
artificial, assembling, 383
base of, 373
changes in, at birth, 375
development of, 364
hilum of, 373
how expanded, 377
in infants and children, 375
left, 374
lobes of, 374
nerve supply, 381
projection of on chest wall, 374
right, 374
root of, 373
surfaces of, 373
vital capacity, 377
volume of, at different ages, 375

Lunula, 494
Luschka, foramina of, 264
  gland of, 485
Lymph, 289, 290
  corpuscles, 294
Lymphadenitis, 322
  from coryza, 367
Lymphangitis, 322
Lymphatic channels, main, 291
  ducts, cervical, right and left, 291
    right, 291
  system, 290
  vessels, 291
Lymphatics of muscles, 173
Lymph-nodes, 292
  distribution of, 294
  inflammatory enlargement, 293
  of lower extremity, 297
  of neck, 294
  of trunk-cavities, 298
  of upper extremity, 296
  tracheobronchial, 298
Lymph-nodules of small intestine, 417
Lymphocyte, 29, 79, 294
Lymphocytosis, 79
Lymphoid cells, 294

Macula lutea, 501
Magendie, foramen of, 264
Malar bones, 133
Malaria parasite in red blood-cell, 34
Male pronucleus, 38
Malleolus, lateral, 159
  mesial, 159
Malleus, 134, 509
Malpighian bodies, 432
  layer, 401, 490
Maltase, 417, 433
  action of, 433
Mammary artery, internal, 331
  glands, 470. See also *Breasts*.
Mandible bone, 132
Mandibular fossa, 129
Manubrium, 142
Margin, supra-orbital, 127
Margination of leukocytes, 301
Marrow, 71, 95, 98
  cavity, 71
    formation of, 95
Masseter muscle, 190
Mastication, 403
Mastoid cells, 129, 135, 509
  process, 129, 136
Mastoiditis from coryza, 367
Maternal impressions, 53
Matrix, 69
  of nail, 494
Maturation of ovum, 35, 36
Maxilla bone, 131
Maxillary sinus, 131, 135
McBurney's point, 217
Measurement of muscular strength, 212
Meatus, external auditory, 129, 508
Meckel's diverticulum, 419
Mediastinal arteries, posterior, 335
Mediastinum, 375
Mediotarsal arch, 161, 165, 166
Medulla oblongata, 257
    at level of motor or pyramidal decussation, 241
    centers of, 260
    function of, 258
    transverse section, 258
  of adrenal, 482
  of hair, 493
  of kidney, 449
Medullary cavity, 98
Medullated axons, 85
Megacephalic skull, 134
Meibomian glands, 494, 499
Meissner's corpuscles, 492
  plexus, 419
Membrana tectoria, 512
Membrane, basement, 61
  drum, 508
  interosseous, 165
  limiting, of cell, 21
  mucous, 59
    continuity of, 60
    layers of, 61
  of brain, 256
  of spinal cord, 226
  Reissner's, 512
  Schneiderian, 384
  serous, 58
  synovial, 59
Membranous cochlea, 510
Meninges, 256
Meningocele, 274
Menopause, 470
Menstruation, 469
  cessation of, 469
  disturbances of, 469
    pathologic, 470
    physiologic, 470
  ovulation and, relation between, 469
  significance of, 469
Mental foramen, 132
Mesenteric artery, inferior, 339
    superior, 339

Mesenteric plexus, superior, 419
veins, 348
Mesentery, 393
Mesial cuneiform bone, 159
malleolus, 159
rectus muscle, 191
Mesocephalic skull, 134
Mesoderm, 41
derivatives of, 46
developmental changes in, 43
parietal, 45
visceral, 45
Mesonephric duct, 446
Mesonephros, 445
Mesothelia, 57
Mesothelium, 58, 315
Mesovarium, 462
Metabolism, 22, 24
age and sex in, 439
basal, 440
of boys, men, and women, 440
factors influencing, 439
mineral salts in, 439
muscular exercise in, 439
of carbohydrates, 437
of fats, 436
of proteins, 438
waste products of, 438
sleep in, 440
temperature in, 439
vitamins in, 439
Metacarpus, 152
Metanephros, 447
Metatarsals, 161
Metopic suture, 136
Microcephalic skull, 134
Microcephalus, 274
Micturition, 456
Middle cuneiform bone, 159
ear, 128, 509
cavity of, 134
turbinate bone, 130
Midsternal line of body, 20
Migration of leukocytes, 301
Müllerean duct, 446
Müller-Lyer figures to show illusion in space perception, 515
Mind-blindness, 270
Mind-deafness, 270
Mineral salts in metabolism, 439
in urine, 456
Minimal air in lungs, 377
Misplaced kidney, 446
Mitosis, 24
Mitral stenosis, 320
valve, 313, 316
Modified epithelium, 62
Molars, 403
Mononuclear leukocyte, 29, 80
Monosaccharids, 433
Monro, foramina of, 264
Mons veneris, 468
Motor area of brain, 268
decussation, 239
plates, 176
points and reaction of degeneration, 214
in lower extremity, 215
in upper extremity, 216
Mouth, development of, 396
digestion in, 403
parts of, 396
Movable kidney, 446
Movement in articulations, 108
of spine, 121
voluntary, amplitude of, norms for, 213
Mucosa of alimentary canal, function of, 395
Mucous coat of large intestine, 422
of small intestine, 416
membrane, 59
continuity of, 60
layers of, 61
Murmurs, heart, 320
Muscle or Muscles:
acid reaction, 174
action of, 176
adductor brevis, 206
longus, 206
magnus, 206
atrophy of, 76
attachment of, 171
biceps, 195, 206
blood-vessels of, 173
brachialis anticus, 195
carbon dioxid in, 174
cardiac, 29, 76
cell, 25, 26
smooth, 28
chemistry of, 174
coccygeus, 201
concentric contraction of, 177
contraction of, 173, 176
factors in, 175
coracobrachialis, 195
crurens, 205
deltoid, 195
diaphragm, 186
eccentric contraction of, 177
erector spinæ, 184
extensor brevis pollicis, 199
carpi radialis brevior, 198

Muscle or Muscles:
extensor carpi radialis longior, 198
ulnaris, 199
communis digitorum, 199
indicis, 199
longus digitorum, 208
hallucis, 208
pollicis, 199
minimi digiti, 199
ossis metacarpi pollicis, 199
external intercostal, 187
oblique, 179
aponeurosis of, 181
fatigue of, 77, 174
flexor carpi radialis, 197
ulnaris, 196
longus digitorum, 210
hallucis, 210
pollicis, 197
profundus digitorum, 197
sublimis digitorum, 197
gastrocnemius, 208
gluteus maximus, 201
medius, 203
minimus, 204
glycogen in, 174
gracilis, 206
hamstring, 206
hypertrophy of, 77
iliacus, 201
inferior oblique, 192
rectus, 191
infraspinatus, 194
internal intercostal, 188
oblique, 180
aponeurosis of, 181
interossei, 199
involuntary, 76
lactic acid in, 174
lateral rectus, 191
latissimus dorsi, 185
levator ani, 201
scapulæ, 192
lumbricales, 199
lymphatics of, 173
masseter, 190
mesial rectus, 191
names of, 178
nerves to, 176
nutrition, 77
occipitofrontalis, 190
of abdominal wall, 179
of arm, 195
of arteries, 326
of back, 184
of chest, 189
of eye, 502
Muscle or Muscles:
of face, 190
of foot, 211
extrinsic, 211
intrinsic, 211
of forearm and hand, 195
tabulation of, 198
of head, 190
of heart, 314
of hip and lower extremity, classification of, 211
of hip-joint, 201
of iris, 500
of leg, 207
anterior, 208
lateral, 211
posterior, 208
of neck, 189
of pelvic floor, 200
of pelvis, 200
of respiration, nerve supply to, 381
of scapula, 192
of thigh, 204
of thorax, 186
of trunk and upper extremity, classification of, 199
orbicularis oris, 191
palpebrarum, 191
orbital, 191
origin and insertion, 171
palmaris longus, 197
papillary, 314
pectoralis major, 189
minor, 189
peroneus brevis, 211
longus, 211
pronator quadratus, 197
radii teres, 196
psoas magnus, 201
pyriformis, 201
quadratus lumborum, 180, 183
quadriceps extensor femoris, 205
rectus abdominus, 181, 183
femoris, 205
rhomboid, 192
sartorius, 205
semimembranosus, 206
semitendinosus, 206
sense, 261
serratus magnus, 193
skeletal, 168
smooth, 76
contraction in, 173
soleus, 208
soreness of, 77, 174
static contraction of, 177
sternocleidomastoid, 189

Muscle or Muscles:
striated, 76
contraction in, 173
subscapularis, 195
superior levator, 191
oblique, 191
rectus, 191
supinator longus, 198
radii brevis, 199
supraspinatus, 194
temporal, 190
tensor fasciæ latæ, 205
teres major, 194
minor, 194
tibialis anticus, 208
posticus, 208
tonic contraction of, 176
tonus, 77
transversalis, aponeurosis of, 181
trapezius, 184
triceps, 195
vastus externus 205
internus, 205
voluntary, 76
Muscular coat of alimentary canal, function, 395
of large intestine, 422
of small intestine, 417
of stomach, 411
exercise in metabolism, 439
strength, measurement of, 212
system, 30
development of, 168
tissue, 28, 75
functions of, 76
Muscularis mucosæ, 61
Musculospiral groove of humerus, 150
Myelin, 85
Myelocytes, 98
Myeloplaxes, 95, 98
Myocardium, 314
Myogenic theory of heart-beat, 319
Myopia, 504
Myotome, 170
Myxedema, 477, 478

Nails, 494
lanula of, 494
matrices of, 494
Nares, anterior, 365
posterior, 366
Nasal bones, 133
cartilages, 75
duct, 498
fossæ, 135, 365
passages, structure of, 365
septum, 130, 365
Nasopharynx, 368, 407
Neck, anatomic, of humerus, 150
arteries of, 331
lymph-nodes of, 294
muscles of, 189
surgical, of humerus, 150
triangles of, 189
veins of, 343
Nerve or Nerves:
abducent, 273
accelorator, 317
action, compound type, 251
auditory, 273, 512
cells, 25, 27
cranial, 271
table of, 273
endings in skin, 492
facial, 273
glossopharyngeal, 273
hypoglossal, 273
impulse, 243
inferior dental, 132
oculomotor, 273
of arteries, 327
of breast, 471
of female generative organs, 468
of heart, 317
of kidney, 450
of large intestine, 423
of pharynx, 410
of small intestine, 418
of stomach, 412
of tongue, 398
of tonsils, 399
olfactory, 273, 366
optic, 273
pneumogastric, 273, 317
distribution of, 281
spinal, 229. See also *Spinal nerves.*
accessory, 273
supply to lungs and muscles of respiration, 381
to muscles, 176
trigeminal, 273
trochlear, 273
vagi, 273, 317
vasoconstrictor, 327
vasodilator, 327
vasomotor, 327
Nerve-centers, 272
psychic stimulation of, 272
Nerve-fiber, 86
Nervous correlation, 475
system, 31, 219
autonomic, 225

Nervous system, autonomic, activity of, emotional states and, relation between, 276
cerebrospinal system and, connection between, 278
cranial, 278
functions of, 279
general plan of, 276
nature of, 276
plexuses and outlying ganglia of, 282
sacral, 278
thoracicolumbar, 278
cerebrospinal, 225
general arrangement of, 224
development of, 41, 220
evolution of, 219
function of, 226
neurons in, arrangement, 223
tissue, 28, 84
action of anesthetics, 245
function of, 87
type reactions in, 244
first level, 244
second level, 245
third level, 245
Neural arch, 115
canal, 115
Neurilemma, 85
Neuro-epithelium, 63
Neurogenic theory of heart-beat, 319
Neurogliar cells, 73
Neurologia, 72
Neuron, 84
afferent, 86, 223
arrangement of, in nervous system, 223
association, 223
axon of, 223
cell body of, 85, 223
dendrites of, 223
efferent, 86, 223
end-organ of, 30
endings of, 86
Neutrophils, 80
Nevi, vascular, 54
Newborn, composition of ash of, 51
shape of head, 138
Nipple, 470
Nissl bodies, 85
Nitrogen equilibrium, 438
Node of Tawara, 315, 318
sino-auricular, 315
Nodes of Ranvier, 85
Nodules, solitary, 417, 418
Non-medullated axons, 85
Norms for amplitude of voluntary movement, 213
Nose, 365
structure of, 365
Nostrils, 365
Notch, cardiac, 374
intercondylar, 158
Nourishment of fetus, 47
Nucleolus, 21
of ovum, 35
Nucleoproteins in urine, 455
Nucleus, 21
cuneatus, 238, 258
gracilis, 238, 258
of ovum, 35
Nutrient artery, 150
Nutrition of muscle, 77
Nux vomica, tincture of, 414

Obesity, 436
Oblique line of tibia, 159
muscle, external, 179
aponeurosis of, 181
inferior, 192
internal, 180
aponeurosis of, 181
superior, 191
Obturator foramen, 147
Occipital bone, 126
ligaments of, 121
lobe, 263
projection, external, 127
Occipitofrontalis muscle, 190
Oculomotor nerve, 273
Odontoblasts, 72
Odontoid process, 117
Olecranon fossa of humerus, 150
process of ulna, 152
Olein, 433
Olfactory area of brain, 269
nerve, 273, 366
Omentum, gastrohepatic, 412
greater, 412
lesser, 412
Opposable big toe, 162
Opsonic index, 81
Opsonins, 81
Optic chiasma, 501
foramen, 132
nerve, 273
tract, defects in, visual defects from, 506
vesicle, primary, 498
Optical illusions, 514, 515
Oral temperature, 441
Orbicularis oris muscle, 191
palpebrarum muscle, 191

Orbit, 132
Orbital fossæ, 135
  muscles, 191
Organ, 28
  end, of Ruffini, 492
  of Corti, 510
Organic substances in urine, 455
Oropharynx, 408
Os calcis, 159, 165
  external, of cervix, 465
  innominatum, 147
  magnum, 152
  pubis, 147
Osmosis, 435
Osmotic pressure, 435
Ossa innominata, 143
Ossification of bone, 94
Osteoblasts, 92, 99
Osteoclasts, 99
Ovarian arteries, 340
  ligament, 462
  veins, 347
Ovaries, 462
  internal structure, 462
Ovulation, 463
  menstruation and, relation between, 469
Ovum, 35, 463
  fertilization of, 38
    process, 39
  maturation of, 35, 36
  segmentation of, 40
Oxidation in body, 22
Oxygen in inspired and expired air, proportion of, 380
Oxyhemoglobin, 80, 300

Pace maker, 318, 354
Pacinian corpuscles, 492
Pain, 489
  referred, 279
Palate bones, 133
  cleft, 396
  hard, 397
  soft, 397
Palatine tonsil, 399
Palmar arch, deep, 332
    superficial, 332
  reflex, 248
Palmaris longus muscle, 197
Palmitin, 433
Palpation points of arteries of lower extremity, 341
  of carotids, 320
Pancreas, 429
  acini of, 431
  internal structure, 431
Pancreatic juice, 431
    enzymes of, 433
    flow of, 434
Papilla of Vater, 415, 429
Papillæ of kidney, 448
  of tongue, 398
Papillary muscles, 314
Paralysis in brain tumor, 274
Paramecium, 82
Parasite, malaria, in red blood-cell, 34
Parathyroids, 478
  function of, 480
Parietal bones, 127
  branches of abdominal aorta, 336
  cells of gastric glands, 411
  layer, 59
  lobe, 263
  mesoderm, 45
  peritoneum, 393
  pleura, 374, 375
Paroöphoron, 462
Parotid glands, 64, 399
Passive acquired immunity, 304
Patches, Peyer's, 417, 418
Patella, 163
  dislocations of, 164
Patellar reflex, 248
Pectoralis major muscle, 189
    minor muscle, 189
Pedicles of vertebra, 115
Pelvic cavity, true, 145
  floor, muscles of, 201
  girdle, 143
  inlet, plane of, 145
Pelvis, angle of inclination, 146
  diameters of, in male and female, 147
  diseases and deformities, 149
  false, 145
  female, 147, 149
    in pregnancy, 149
  ligaments of, 148
  muscles of, 200
  of kidney, 450
  sagittal section through, 146
  true, 145
Penis, glans of, 473
Pepsin, 411
  action of, 413
    on protein, 442
Pericardial arteries, 334
  fluid, 309
Pericardium, 58, 307
  external fibrous layer, 307
  internal serous layer, 308
Perichondrium, 70

Pericytes, 325
Perilymph, 510
Perineum, 468
Perineurium, 230
Periosteum, 71, 94
in infant and adult compared, 105
Peristalsis, 434
Peristaltic wave, 395
Peritoneal cavity, 33
fluid, 393
Peritoneum, 58, 392
development of, 390
parietal, 393
visceral, 393
Peroneal artery, 340
Peroneus brevis muscle, 211
longus muscle, 211
Peyer's patches, 417, 418
Phagocytes, 81
Phagocytosis, 81
Phalanges of foot, 162
of hand, 152
and foot, differences in, 156
Pharyngeal reflex, 248
tonsil, 368, 399
Pharynx, 368, 407
vessels and nerves of, 410
Phenomena of absorption, 434
Phototaxis, 497
Phrenic arteries, 336
Pia mater, 226, 257
Pigmentation in skin, 491, 492
Pigmented epithelium, 62
Pillars of fauces, 397
Pineal gland, 485
Pinna, 508
Pisiform bone, 152
Pituitary gland, 483
chief and chromophil cells of, 483
function of, 483
in pregnancy and labor, 484
lobes of, 483
Pituitrin, 484
Placenta, 47, 49
Plane of pelvic inlet, 145
Planes of body, 18, 19
Plantar arch, 341
arteries, 341
reflex, 248
Plantars, long and short, 166
Plasma, blood, 299, 302
Platelets, blood, 80, 301
function of, 82
Plates, motor, 176
Pleura, 58, 374
parietal, 374, 375
Pleura, visceral, 374
Pleurisy, 374
with effusion, 374
Plexus, aortic, 282
brachial, 232
cardiac, 282, 317
hypogastric, 282
of Auerbach, 419
of Meissner, 419
solar, 282, 419
superior mesenteric, 419
Plexuses of autonomic nervous system, 282
of spinal nerves, 231
Pneumogastric nerve, 273, 317
distribution of, 281
Pneumothorax, 376
artificial, 377
Point, McBurney's, 217
Polar body, first, 36, 38
second and third, 37, 38
Polymorphonuclear leukocytes, 80
Pons varolii, 255, 260
Popliteal artery, 340
Pores of skin, 495
Portal circulation, 288
system, 342, 348
obstruction, results of, 349
venous circulation of, 429
vein, 348
function of, 428
Posterior column tracts of spinal cord, 238
commissure, 238
common ligament of spine, 120
dental canal, 131
fontanel, 137
intertrochanteric line, 157
leg muscles, 208
ligament of uterus, 467
median fissure of spinal cord, 235
mediastinal arteries, 335
nares, 366
root of spinal nerve, 229
sacro-iliac ligament, 148
surface of body, 19
thoracic wall, vascular and nervous trunks of, 335
tibial artery, 340
Posterolateral fontanels, 138
Postganglionic fibers, 279
Posture of Harvard freshmen, 122
Poupart's ligament, 149
Preganglionic fibers, 279
Pregnancy, breasts in, 471
cells, 484
changes in uterus in, 465

Pregnancy, pelvis in, 149
pituitary gland in, 484
Premature contraction of heart, 354
Premolars, 403
Prepuce, female, 468
male, 473
Presbyopia, 504
Pressure, osmotic, 435
sense of, 489
Primary optic vesicle, 498
Process, 101
alveolar, 131, 132, 136
coracoid, 143
coronoid, 132
of ulna, 152
mastoid, 129, 136
odontoid, of spine, 117
olecranon, of ulna, 152
pterygoid, 131, 136
styloid, 136
of radius, 152
of ulna, 152
Processes, superior and inferior articulate, of spine, 116
transverse, of vertebra, 115
Prognathism, 52
Projection, external occipital, 127
lines of heart, 310
of arteries of lower extremity, 341
of bone, 101
of carotids, 330
of subclavian and arm vessels, 332
tracts of brain, 265
Prolapse of uterus, 467
Pronator quadratus muscle, 197
radii teres muscle, 196
Pronephric duct, 445
Pronephros, 444
Pronucleus, female, 38
male, 38
Prostate, 472
Prostatic fluid, 472
Proteins, absorption of, 438
action of pepsin on, 442
classification, 413
metabolism of, 438
waste products of, 438
Protoplasm, 20
of ovum, 35
Proximal tubule of kidney, 448
Psoas magnus muscle, 201
Psychic flow of saliva, 400
stimulation of nerve-centers, 272
Pterygoid process, 131, 136
Ptyalin, 405
Pulmonary artery, 288, 313
and branches, 328
Pulmonary capillaries, 328
circulation, 288, 328
semilunar valves, 316
veins, 313, 328
Pulse, 353
arterial, 353
deficit, 353, 354
pressure, 352
rate, 353
strong or hard, 353
weak or soft, 353
Purgatives, action of, 424
Purin bases, 438, 455
Purkinje, cells of, 260
Purple, visual, 502
Pus, 81, 301
in urine, 456
Pyramidal tracts of spinal cord, 239
Pyramids, 239
Pyrexia, 441
Pyriformis muscle, 201

Quadratus lumborum, 180, 183
Quadriceps extensor femoris muscle, 205

Rachitic rosary, 142
Radial artery, 332
projection of, 333
Radius, 152
Rami of os pubis, 147
Ramus, 132
Ranvier, nodes of, 85
Reaction, acid, of muscle, 174
of degeneration and motor points, 214
Receptaculum chyli, 292
Receptors, 86, 234
Rectal temperature, 441
Rectovaginal ligament, 467
Rectum, 421
Rectus abdominis muscle, 181, 183
femoris muscle, 205
muscle, inferior, 191
mesial, 191
lateral, 191
superior, 191
Red blood-cells, 77
function of, 80
bone-marrow, 98
corpuscles, 299
Reduced hemoglobin, 300
Referred pain, 279, 280
Reflex or Reflexes:
abdominal, 248
Achilles', 248
act, structures involved in, 243

Reflex or Reflexes:
anal, 248
ankle, 248
arc, 245
Babinski, 248
choking, 369
common, tabulation of, 248
cremaster, 248
education of, 246
gluteal, 248
jaw, 248
of spinal cord, 247
palmar, 248
patellar, 248
pharyngeal, 248
plantar, 248
Regurgitation, 320
Reil, island of, 263
Reissner's membrane, 512
Renal arteries, 340
veins, 347
Rennin, 411
action of, 413
Reproduction of cells, 24
Reproductive system, 31, 460
Residual air in lungs, 377
Resistance, 303
Respiration, asthmatic, 379
Cheyne-Stokes, 379
costal, 378
diaphragmatic, 378
labored, 379
muscles of, nerve supply to, 381
Respiratory center, 381
depressants, 382
stimulants, 382
system, 31, 363
development of, 363
Retention of urine, 457
Reticular tissue, 67
functions of, 75
Retina, 501
layers of, 501
schematic diagram of, 63
Retropharyngeal abscess from coryza, 367
Retroversion of uterus, 467
Rhomboid muscles, 192
Ribs, 140, 141
Rickets, 100
Right coronary ligament, 427
lung, 374
Ringer's solution, 319
Rolando, fissure of, 262
Root, anterior, of spinal nerve, 229
of lung, 373
posterior, of spinal nerve, 229
Rosary, rachitic, 142
Rotation of joint, 110
of scapula, 185
Round ligament, 162, 360, 427, 460
Rubrospinal tracts of spinal cord, 239
Ruffini, end organs of, 492
Rugæ of bladder, 453
of stomach, 411
of vagina, 467

Sac, conjunctival, 498
protecting, 73
Sacculus, 507
Sacral artery, 336
autonomic system, 278
curve of spine, 114
vertebræ, 113
Sacrococcygeal joint, sprain of, 149
Sacro-iliac joint, 118, 148
sprain of, 149
ligament, anterior, 148
posterior, 148
Sacrosciatic ligaments, 148
Sacrum, 143
relation to vertebræ, 117
Saddle, Turk's, 131
Sagittal plane of body, 18, 19
section of skull, 130
through pelvis, 146
suture, 136
Saliva, psychic flow, 400
secretion of, 400
Salivary glands, 399
structure of, 399
Salts, bile, 433
mineral, in metabolism, 439
in urine, 456
Santorini, duct of, 416, 431
Saphenous veins, 346
Saponification of fats, 433
Sarcolactic acid, 77
Sarcolemma, 76
Sartorius muscle, 205
Scala tympani, 510
vestibuli, 510
Scalp, layers of, 91
Scaphocuneiform ligaments, 166
Scaphoid bone, 152, 159
Scapula, 143
muscles of, 192
rotation of, 185
spine of, 143
Schneiderian membrane, 384
Sclera, 499
Sclerotome, 170
Scoliosis, 121, 123
from shortened leg, 124

Scrotum, 472
Sebaceous glands, 494
Sebum, 494
Second convoluted tubule of kidney, 448
ventricle, 264
Secretin, 434
Secretions, internal, effect of, on height, 483
nature of, 475
Secretory gland, internal, definition of, 475
Segmentation of cells, 24
of ovum, 40
Sella turcica, 131, 483
Semen, 473
Semicircular canals, 134, 515
Semilunar bone, 152
cartilages, 163
valves, 313, 316
aortic, 316
pulmonary, 316
Semimembranosus muscle, 206
Seminal fluid, 473
vesicles, 472
Seminiferous tubules, 473
Semitendinosus muscle, 206
Sense, muscle, 261
of hunger, 488
of pain, 488
of sight, 488, 496
center for, 268
of smell, 496
center for, 269
of taste, 496
center for, 269
of temperature, 489
of thirst, 488
of touch, 489
Senses, general, 488
and special, organs of, 487
of hearing and equilibrium, 507
somatic, 488
visceral, 488
Sensibility, tactile, in children, 490
Sensory area of brain, 268
Septum, nasal, 130, 365
Serous coat of alimentary canal, function, 396
of large intestine, 423
of small intestine, 417
of stomach, 411
membrane, 58
Serratus magnus muscle, 193
Setting a fracture, 100
Sex and age in metabolism, 439
cells, 24
Sexual organs. See *Generative organs.*
Sheaths, tendon, 172
Shin, 159
Shock, 350
Shoulder, dislocation of, 153
Shoulder-blades, 143
Shoulder-girdle, 143
Shoulder-joint, left, 154
Sight, sense of, 488, 496
Sigmoid colon, 421
Sino-auricular node, 315
Sinus or Sinuses, 101, 134
coronary, 317
ethmoidal, 130, 135
frontal, 127, 134
lateral, 127, 129
maxillary, 131, 135
of skull, 257
of Valsalva, 316
sphenoidal, 131, 135
venous, 342
Sixth dorsal vertebra and rib, 142
Skeletal muscles, 168
system, 30
Skeleton, 90
appendicular, 104
axial, 104
external, 90
infant and adult, differences between, 103, 104
nature of, 90
origin of, 91
plan of, 104
Skin, 490
color of, 491
functions of, 490
glands of, 494
layers of, 490
nerve endings in, 492
pigmentation in, 491, 492
pores, 495
Skull, 125
as a whole, 133
capacity of, in men and women, 134
cavities of, 134
cranial portion, 126
evolution of, 126
facial portion, 126
fontanels of, 136
fossæ of, 135
megacephalic, 134
mesocephalic, 134
microcephalic, 134
of infant and adult compared, 104
of newborn, 138

Skull, processes of, 136
relation of brain to, 262
sagittal section of, 130
sinuses of, 134, 257
sutures of, 136
Sleep in metabolism, 440
Small intestine, 415. See also *Intestine, small.*
Smell, sense of, 496
brain area of, 269
Smooth muscle, 76
contraction in, 173
Soaps, intestinal, 433
Sodium citrate to prevent coagulation of blood, 84
Soft palate, 397
Solar plexus, 282, 419
Soleus muscle, 208
Solitary nodules, 417, 418
Solution, Locke's, 319
Ringer's, 319
Somatic senses, 488
Somatopleure, 45
Somites, 43
Soreness of muscle, 77
Sounds of heart, 319
Space perception, illusion in, 515
subarachnoid, 228
subdivided, illusion of, 514
subdural, 228
Specialization of cells, 25
Speech area of brain, 269
Spermatic arteries, 340
cord, 472
veins, 347
Spermatids, 473
Spermatocytes, 473
Spermatogonia, 473
Spermatozoa, 473
Spermatozoön, 35
Sphenoid bone, 130
Sphenoidal sinus, 131, 135
Sphere, attraction, of cell, 21
Sphygmomanometer, 352
Spina bifida, 116, 248, 249
Spinal accessory nerve, 273
cord, 226
anterior commissure of, 235
horn of, 235
median fissure of, 235
cervical enlargement, 238
gray matter of, 235
lumbar enlargement, 238
membranes of, 226
posterior commissure of, 235
horn of, 235
median fissure of, 235
Spinal cord, reflexes of, 247
structure of, 234
tracts of, 238
ascending, 238
degeneration of, 241
descending, 239
direct cerebellar, 238
posterior column, 238
pyramidal, 239
rubrospinal, 239
schematic cross-section, 237
spinothalamic, 239
vestibulospinal, 239
white matter of, 239
fluid, 226, 228
nerves, 229
anterior root, 229
funiculi of, 230
plexuses of, 231
posterior root, 229
structure of, 229
terminations of, 232
trunk of, 230
Spine, 101, 112
anterior inferior, of ilium, 148
superior, of ilium, 148
characteristics in different regions, 117
curves of, 113
primary and secondary, 115
infant and adult, differences in, 115
injuries of, 124
ligaments of, 118
movements of, 121
of ischium, 147
of scapula, 143
of tibia, 159
of vertebra, 116
results of corrective exercises for straightening, 123
Spinothalamic tracts of spinal cord, 239
Splanchnopleure, 45
Spleen, 431
enlargement of, 431
internal structure, 432
Splenic artery, 339
flexure, 421
vein, 348
Spongy bone, 71, 99
Spot, blind, of eye, 503
demonstrating, 503
Sprain of sacrococcygeal joint, 149
of sacro-iliac joint, 149
Squamous epithelium, simple, 57
stratified, 62

Stapes, 134, 509
Static contraction of muscle, 177
Stearin, 433
Stenosis, mitral, 320
Sternocleidomastoid muscle, 189
Sternum, 140, 142
Stigmata of degeneration, 52
Stimulants, respiratory, 382
Stomach, 410
  coats of, 411
  digestion in, 412
  emptying time, 415
  movements of, 415
  rugæ of, 411
  vessels and nerves of, 412
  volume, 410
Stratum corneum, 490
  germinativum, 490
Strength, muscular, measurement of, 212
Striated muscle, 76
    contraction in, 173
Styloid process, 136
    of radius, 152
    of ulna, 152
Subacromial bursa, 107
Subarachnoid space, 228
Subclavian arteries and branches, 331
    palpation points, 333
    projection of, 332
Subdural space, 228
Sublingual gland, 399
Submaxillary gland, 399
Submucosa of alimentary canal, function, 395
Submucous coat of large intestine, 422
    of small intestine, 416
    of stomach, 411
Subscapular fossa, 143
Subscapularis muscle, 195
Sugar in urine, 455, 456
Sulcus, 101
Superficial fascia, 74
  palmar arch, 332
  veins, 327, 342
Superior levator muscle, 191
  mesenteric artery, 339
    plexus, 419
    vein, 348
  oblique muscle, 191
  rectus muscle, 191
  turbinate bone, 130
  vena cava, 313, 342, 343
Supinator longus muscle, 198
  radii brevis muscle, 199
Supplementary air in lungs, 377
Suppression of urine, 457
Supraglenoid fossa, 143
Supra-orbital margin, 127
Suprarenal arteries, 339
  capsules, 481
  veins, 347
Supraspinatus muscle, 194
Supraspinous fossa, 143
  ligament, 120
Surfaces of body, 19
Surgical neck of humerus, 150
Suspensory ligament, 462, 500
Sustentaculum tali, 166
Suture, coronal, 136
  lambdoidal, 136
  lateral anteroposterior, 136
  metopic, 136
  of joints, 106
  sagittal, 136
Sutures of skull, 136
Sweat-glands, 495
Sylvius, aqueduct of, 263
  fissure of, 262
Symphisis pubis, 106, 147
Synapses, 222, 223
Synarthrosis, 106
Synovial membranes, 59
System, 29
  circulatory, 31, 284
  digestive, 31, 386
  endocrine, 31, 475
  excretory, 31, 444
  haversian, 99
  lamellar, 96
  lymphatic, 290
  muscular, 30
    development of, 168
  nervous, 31, 219
  portal, 342, 348
  reproductive, 31, 460
  respiratory, 31, 363
  skeletal, 30
Systemic arteries, 328
  capillaries, 342
  circulation, 288, 328
  veins, 342
Systole of heart, 317
Systolic blood-pressure, 352

Tables, 93
Tactile acuity, measurement of, 490
  sensibility in children, 490
Talipes calcaneus, 217
  equinus, 217
  valgus, 217
  varus, 217

Taste areas, 424
buds, 398, 496
sense of, 496
brain area of, 269
Tawara, node of, 315, 318
Teeth, 400
delayed eruption, 402
development of, 405
permanent, 402, 403
eruption of, 403
temporary, 402
eruption of, 402
Temperature, abnormal, 441
axillary, 441
in metabolism, 439
of blood, 301
oral, 441
rectal, 441
sense of, 489
subnormal, 441
Temporal bones, 128
fossæ, 136
lobe, 263
muscle, 190
Temporary teeth, 402
eruption of, 402
Tendons, 73
cellular structure, 65
function of, 172
of foot, 165
sheaths, 172
vascular supply to, 173
Tenia, 422
Tensor fasciæ latæ muscle, 205
Tentorium cerebelli, 257
Teres major muscle, 194
minor muscle, 194
Terminal arborization, 85
Terminology, 18
Testes, 472
function of, 473
removal of, effects, 484
Testicular extract, 484
Test-meal, 415
Tetany, 479
Thalamus, 262
Thenar eminence, 199
Theory, humoral, 475
Thigh, 155, 156
adductors of, 206
muscles of, 204
Third ventricle, 264
Thirst, 488
Thoma-Zeiss hematocytometer, 88
Thoracic aorta, 329
and its branches, 333
cavity, 33
Thoracic curve of spine, 114
duct, 291
vertebræ, 113
wall, posterior, vascular and nervous trunks of, 335
Thoracicolumbar autonomic system, 278
Thorax, 140
artificial, assembling, 383
mechanism of, 375
muscles of, 186
of infant and adult compared, 105
Thrombin, 82
Thrombocytes, 301
Thrombogen, 82
Thrombokinase, 82
Thrombophlebitis, 362
Thrombus, 82
Thymus, 480
function of, 481
structure of, 480
Thyroid axis, 331
cartilage, 368
gland, 476
congenital lack of, effects, 477
function of, 477
secretion of, 477
Thyroids, accessory, 477
Thyroxin, 477
Tibia, 159
and fibula in normal relations, 158
Tibial arteries, 340
Tibialis anticus muscle, 208
posticus muscle, 208
Tidal air in lungs, 377
Tied tongue, 398
Tissue, 56
adipose, 67
functions of, 75
areolar, 67
functions of, 74
bone, 70
functions of, 75
cartilaginous, 69
functions of, 75
cellular, 27
classes of, 56
connective, 28
function of, 66, 73
elastic, of arteries, 326
epithelial, 28, 56
how gases of blood enter, 380
muscular, 28, 75
functions of, 76
nervous, 28, 84
function of, 87
reticular, 67

Tissue, reticular, functions of, 75
vascular, 28, 77
white fibrous, 66
functions of, 73
of arteries, 326
yellow fibrous, 67
functions of, 73
Toe, big, opposable, 162
Toes, 156
Tongue, 398
papillæ of, 398
tied, 398
vessels and nerves of, 398
Tonic contraction of muscle, 176
Tonsils, 399
crypts, 399
lingual, 399
palatine, 399
pharyngeal, 368, 399
vessels and nerves of, 399
Tonus, 77
Touch, discriminating, 490
sense of, 489
Trachea, 370
Tracheobronchial lymph-nodes, 298
Tracheotomy, 371
Tracts of brain, 264
of spinal cord, 238. See also *Spinal cord tracts.*
Transfusion, 355
Transitional leukocyte, 29, 80
Transversalis muscle, 181
aponeuroses of, 181
Transverse arch, 161
of foot, 165, 166
colon, 420
plane of body, 18, 19
processes of vertebræ, 115
Trapezium bone, 152
Trapezius muscle, 184
Trapezoid bone, 152
Triangle, Hesselbach's, 183
Triangles of neck, 189
Triceps muscle, 195
Tricuspid valve, 313, 316
Trigeminal nerve, 273
brain connection of, 259
Trochanter, 101
Trochanters of femur, 157
Trochlea of humerus, 150
Trochlear nerve, 273
True joint, 106
pelvic cavity, 145
pelvis, 145
Trunk, muscles of, classification of, 199
of spinal nerve, 230
Trunk-cavities, lymph-nodes of, 298
Trypsin, 417, 433
action of, 433
Trypsinogen, 417, 433
Tube, eustachian, 509
fallopian, 462, 464
Tubercle, 101
adductor, 159
Tubercular adenitis, 295
Tuberosity, 101
bicipital, of radius, 152
deltoid, 150
of humerus, 150
of ischium, 147
of tibia, 159
Tubule, dentinal, 71
distal, of kidney, 448
first convoluted, of kidney, 448
proximal, of kidney, 448
second convoluted, of kidney, 448
seminiferous, 473
uriniferous, of kidney, 448, 449
Tumors of brain, paralysis from, 274
Turbinate bones, 366
inferior, 133
middle, 130
superior, 130
Turk's saddle, 131
Tympanic cavity, 134, 509
Type reactions in nervous tissue, 244

Ulna, 151
Ulnar artery, 332
projection of, 333
Umbilical arteries, 356
cord, 45, 356
after birth, 360
vein, 355
after birth, 359
vesicle, 419
Unciform bone, 152
Upper extremity, bones of, 150
injuries of, 153
lymph-nodes of, 296
motor points in, 215
muscles of, classification of, 199
ligaments of, 153
Urea, 438, 455
in urine, 455
Ureters, 451
Urethra in female, 454
in male, 454
Urethral glands, 468
Urinary system, 444
Urine, abnormal constituents of, 456

Urine, albumin in, 455, 456
test for, 458
blood in, 456
calculi in, 456
casts in, 456
coloring materials in, 456
composition of, 454
gases in, 456
how kidneys secrete, 454
incontinence of, 457
indican in, 456
inorganic substances in, 455
mineral salts in, 456
nucleoproteins in, 455
organic substances in, 455
pus in, 456
quantity of, 457
retention of, 457
secretion of, modifying factors, 457
sugar in, 455, 456
suppression of, 457
urea in, 455
voiding, 456
water in, 455
Uriniferous tubule of kidney, 448, 449
Uterine artery, 340
glands, 465
Uterosacral ligaments, 467
Uterovesical ligament, 467
Uterus, 462, 465
anterior ligament of, 467
anteversion of, 466
body of, 465
broad ligaments of, 462, 467
cervix of, 465
external os of, 465
changes in pregnancy, 465
fundus of, 465
internal structure, 465
ligaments of, 466
position of, 466
posterior ligament of, 467
prolapse of, 467
retroversion of, 467
round ligaments of, 467
Utriculus, 507
Uvula, 397

Vagi nerves, 317
Vagina, 461, 467
rugæ of, 467
Vaginal synovial membrane, 59
Vagus nerve, 273
brain connection of, 259
Valsalva, sinuses of, 316
Valve or Valves:
atrioventricular, 313, 316
bicuspid, 316
eustachian, 316
mitral, 313, 316
of heart, 313, 316
of veins, 327
semilunar, 313, 316
tricuspid, 313, 316
Valvulæ conniventes, 417
Valvular lesions of heart, 320
Vas deferens, 472
Vasa vasorum, 326
Vascular nevi, 54
tissue, 28, 77
Vasoconstriction, 349
Vasoconstrictor nerves, 327
Vasodilation, 349
Vasodilator nerves, 327
Vasomotor center, 327
nerves, 327
phenomena, 349
Vastus externus muscle, 205
internus muscle, 205
Vater, papilla of, 415, 429
Vater-Pacinian corpuscle, 234
Vein or Veins, 288
azygos, 345
blood-supply of, 326
cardiac, 342
central, of liver, 429
deep, 327, 342
endothelium of, 326
gastric, 348
iliac, 346
jugular, 343
mesenteric, 348
of head and neck, 343
of heart, 316
ovarian, 347
portal, 348
function of, 428
pulmonary, 313, 328
renal, 347
saphenous, 346
spermatic, 347
splenic, 348
structure of, 325
superficial, 327, 342
suprarenal, 347
systemic, 342
umbilical, 355
after birth, 359
valves of, 327
Vena cava, inferior, 313, 342, 345
superior, 313, 342, 343
Venæ thebesii, 317

Venous capillaries, 289
circulation of portal system, 429
sinuses, 342
Ventral aortæ, 285
cavity, 33
surface of body, 19
Ventricles of brain, 263
of heart, 312, 316
Venule, 325
Vermiform, appendix, 420
Vermis, 260
Vernix caseosa, 494
Vertebræ, 112
body of, 115
cervical, 113
coccygeal, 113
displacement of, 121
laminæ of, 115
lumbar, 113
pedicles of, 115
relation of sacrum to, 117
sacral, 113
spine of, 116
superior and inferior articulate processes of, 116
thoracic, 113
transverse processes of, 115
typical, 115
variations in, 117
Vertebral artery, 331
column. See *Spine.*
Vertebrate body, 31
Vertical lines, overestimation of, 514
Vesicle, optic, primary, 498
seminal, 472
umbilical, 419
Vesico-uterine ligament, 454
Vessels, lymphatic, 291
Vestibulospinal tracts of spinal cord, 239
Villi, 49
of small intestines, 417
Viscera, abdominal, pain points of, 280
Visceral branches of abdominal aorta, 336
layer, 59
mesoderm, 45
peritoneum, 393
pleura, 374
senses, 488
Vision, 503
color, 502
defects in, from defects in brain, 507
in eye, 504
in optic tract, 506
Visual area of brain, 268
illusions, 514, 515
perception, theories of, 502
purple, 502
senses, 488
Visual-speech area of brain, 270
Vital capacity of lungs, 377
Vitamins, 439
Vitreous humor, 72, 501
Vocal cords, 369
false, 369
Voiding, 456
Voluntary movement, amplitude of, norms for, 213
muscle, 76
Vomer bone, 133
Vulva, 461, 468

Waste products of protein metabolism, 438
Water in urine, 455
Wave, peristaltic, 393
Wax, ear, 496, 508
Wharton's jelly, 72
White blood-cells, 78
function of, 81
corpuscles, 299, 300
fibrocartilage, 70
fibrous tissue, 66
functions of, 73
of arteries, 326
matter of spinal cord, 239
Willis, circle of, 327, 330
Wirsung, duct of, 416, 431
Word-blindness, 270
Word-deafness, 270
Wormian bones, 106
Wrist, 150, 152
hinge movement of, 109
Writing area of brain, 269

Yellow bone-marrow, 98
fibrous cartilage, 70
tissue, 67
functions of, 73
Y-ligament, 162

Zöllner's lines, 515
Zones, Head's, 233
Zygoma, 129, 136
Zygomatic fossæ, 136

OCT 25 2000

Date Due

APR 1 1 2005

QM23.W5 1929
A text-book of anatomy and physiology
3 0629 0033677 X
QM
23
W5
1929

Textbook of anatomy and physiology